

HPV Infection in Esophageal Squamous Cell Carcinoma

¹Islam Bakri Mohamed elhag , ²Ibrahim Bakhit Yousif Elemam

¹BS.c in medical laboratory sciences – AL- Neelain university, Sudan

²Department of Histopathology and Cytology -Faculty of Medical Laboratory Sciences -Shendi University- Sudan

Correspondent contact: Dr. Ibrahim Bakhit Yousif Elemam

Faculty of Medical laboratory Sciences, Shendi University- Sudan

Email: elemam.ibrahim@yahoo.com

Abstract: *Carcinomas of esophagus, mostly squamous cell carcinomas, occur throughout the world. There are a number of suspected genetic or environmental etiologies. Oncogenic human papillomavirus (HPV) has been hypothesized as a risk factor for esophageal squamous cell carcinoma. The aims of this review was to estimate the present of HPV by immunohistochemical technique*

Material and Methods: *In this is descriptive retrospective study, which carried out Khartoum state -Sudan, formalin fixed paraffin embedded blocks from 30 patients previously diagnosed as esophageal tumors , Five (4) micron was taken on positively coated slide for immunohistochemical detection of HPV (6, 11, 16, 18, 31, 33, 42, 51, 52, 56 and 58). SPSS version 11.5 computer programs were used to analyze the data, frequencies, and means, the P.value was calculated by Chi square test.*

Result: *The study involved (30) , 13 out of 30 were males (43.3%) and 17(55.7%) were females with (1.3:1) female: males ratio, their age ranging from 25 and 89 years with mean of age about 55.7 years old. HPV was detected in four samples (13.3%) with statistically insignificant difference between HPV infection and type of tumors.*

Conclusion: *. This study demonstrates that the HPV infection rate in ESCC samples is very low, suggesting that HPV is not the etiological cause of ESCC in Sudan.*

Keywords: *Human papillomavirus, esophageal cancer. Immunohistochemistry*

Introduction:

Esophageal squamous cell carcinoma (ESCC) accounts for most esophageal malignancy in East Asia, including China, [1] and southern Africa, and its incidence remains relatively constant. Esophageal adenocarcinoma (EAC), including adenocarcinoma of the esophagogastric junction, has increased rapidly in North America and Europe.[2] Esophageal cancer, the eighth most common cancer in the world, is composed of two main histologic types: squamous cell carcinoma (ESCC) and adenocarcinoma (EAC). The two tumors have five-year overall survival rates averaging 15% [3], and are often included together in therapeutic and prognostic clinical studies [4, 5]. The histologist may share the poor outcome with current therapeutic strategies, but they have distinct differences including causality, cell of origin and epidemiologic distribution [6] The epidemiology of esophageal cancer differs markedly from other epithelial cancers. There is huge variation in incidence worldwide with greater than 100-fold differences observed between high incidence areas such as China and Iran, and low

incidence areas such as Western Africa [7].These wide variations in incidence are often observed between areas in close geographical proximity [8,9,10].

Male to female incidence rate ratio also varies widely with ratios greater than 20:1 in France to near equality or even excess female cases in high incidence areas such as Iran [8, 11]. Worldwide, a higher incidence of esophageal cancer is seen in men with an average 3–4 fold increased rate for SCC and a 7–10 fold increased rate for ADC compared to women [12]. The etiology of ESCC remains unclear, and epidemiological studies suggest that tobacco smoking, heavy alcohol drinking, micronutrient deficiency [13, 14], and dietary carcinogen exposure may cause the malignancy. Infectious agents have been implicated, as either direct carcinogens or promoters. In particular, human papillomavirus (HPV) has been postulated as a possible cause of ESCC [15]. HPV infection in esophageal cancer was first suggested in 1982 based on histological observations [16]. Subsequent studies using various methods have confirmed the presence of HPV in ESCC [15, 17]

Human papillomavirus (HPV) is a circular, double-stranded DNA virus with established oncogenic potential in the setting of multiple malignancies, most prominently squamous cell carcinoma of the cervix [18]. The established role of HPV in squamous cell cancers of other sites, including the anus and the oropharynx, has resulted in a growing literature aiming to assess the biological and clinical roles of HPV tumor infection in a diversity of cancers.

Evidence dating back over three decades has indicated an association between HPV infection and esophageal squamous cell carcinoma (ESCC) [19,21]. Recent meta-analyses have assessed the incidence and etiological role of HPV-ESCC tumor infection. This review aims to provide clinicians with a summary of the current HPV-ESCC literature and clinical recommendations regarding HPV infection in this disease.

3. MATERIALS AND METHODS

This is retrospective descriptive study aimed to detect the HPV in esophagus tumor using immunohistochemistry. The group included 30 participants; Thirty paraffin blocks that previously were diagnosed as esophageal tumor were selected from Omdurman teaching Hospital- Sudan during the period from January 2014 and may2015. Patient identification data were retrieved from patients records data include age, sex and tumor grade. The immunostaining of HPV was performed according dextral polymer method, using monoclonal antibodies (HPV-Ab-3 -Thermo Fisher) against HPV types (6, 11, 16, 18, 31, 33, 42, 51, 52, 56 and 58.).

The Immunohistochemical procedure was done as follows:

One section (3µm) from formalin-fixed, paraffin-embedded tumors was cut and mounted onto salinized slides (Thermo). Following deparaffinization in xylene, slides was rehydrated through a graded series of alcohol and was placed in distilled water. Samples were steamed for antigen retrieval for HPV using high PH (9) by water bath at 95c. Endogenous peroxidase activity was blocked with 3% hydrogen peroxide and methanol for 10 min, and then Slides was incubated with 100 µl of primary antibodies for 20 min at room temperature in a moisture chamber. After washing with PBS for 3 min, binding of antibodies was be detected by incubating for 20 minutes with dextran labeled polymer ((Thermo -ultra vision). Finally, the sections washed in three changes of PBS, followed by adding 3, 3 diaminobenzidine tetra hydrochloride (DAB) as a chromogen to produce the characteristic brown stain for the visualization of the antibody/enzyme complex for up to 5 min. Slides was counterstained with haematoxylin.. Each slide was evaluated with investigator then the results were confirmed by consultant histopathologist.

Statistical analysis:

The data was analyzed, using the statistical programs software Statistical Package for the Social Sciences (SPSS) version (11.5), Chi square test and different statistical measures were calculated.

Result:

Patient Characteristics:

The study involved 30 subjects, (13) out of them were males (43.3%) and (17) (55.7%) were females with (1.3:1) female: males ratio as showed in fig 1, the patients' age ranged between 25 and 89 years with mean of age about 55.7 years. The majority of esophageal tumors patients were above 50 years old 21(70%) and 9 (30%) were less than 50 years old as in table 2.

Histological classifications:

The frequency of esophageal cancer was 3 (10%) cases of squamous cell carcinoma Insitu, 15(50%) cases of moderately differentiated squamous cell carcinoma, 11(36.7%) cases of well differentiated squamous cell carcinoma, and 1(3.3%) case of poorly differentiated squamous cell carcinoma as in table 1.

HPV immunostain results:

The HPV showed positive staining reaction in (2) cases of well differentiated squamous cell carcinoma, one case of poorly differentiated squamous cell carcinoma and one case of moderately differentiated squamous cell carcinoma, with statistically insignificant relationship between histological types of the esophageal cancer and HPV expression , the P value was 0.51 as in table

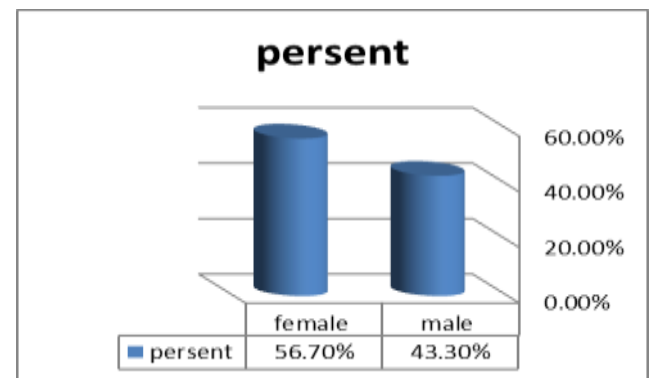


Fig 1: the frequency of sex among study population

Table 1: Frequency of histological types of tumors

Type of tumor	Frequency	Percent
Moderately differentiated squamous cell carcinoma	15	50
Well differentiated squamous cell carcinoma	11	36.7
Poorly differentiated squamous cell carcinoma	1	3.3
Squamous cell carcinoma	3	10.0
Total	30	100.0

Table 2: the frequency of ESCC by age group

Age group	Frequency of ESCC	Present
10-20	2	6.7%
21-30	2	6.7%
31-40	6	20%
41-50	8	26.7%
51-60	5	16.6%
61-70	5	16.6%
71-80	2	6.7%
Total	30	100%

Discussion:

The etiological role of HPV in ESCC is still unclear. The incidence of HPV in ESCC varies between different geographical areas [15]. It is postulated that areas with high incidence of esophageal carcinoma have higher rates of HPV than areas with low incidence of esophageal carcinoma [20]. The infection of HPV rate reported in the literature varied largely, such as in India, one of Asian high ESCC regions, the detection rate could reach as high as 67% [21], while in some Western countries such as France [22], Slovenia [23], Sweden [24], Belgium [25] and Finland [26], the HPV infection rate is close to zero.

In our study, we observed an association between HPV infection and ESCC, HPV was detected in 13.3% of the cases by the use of immunohistochemistry, this result contrast with some previous studies from other countries that identified HPV in high proportion in esophageal cancer such Zhou et al, investigated the presence of HPV type 16's DNA in twenty three ESCC samples, and adjacent normal mucosa as controls; and found it in 64% of ESCC samples and in 34.7% of the adjacent mucosa (27). Farhadi investigated the relationship of HPV and ESCC in Iranian patients compared to esophageal specimens from normal subjects as controls. He employed PCR using three types of primers; a conserved region and two type specific primers namely, HPV 16 and HPV 18 and found the following results: Fourteen (36.8%) of the 38 ESCC samples and only 5 (13.2%) of the 38 control samples were positive for the HPV L1 gene ($P=0.02$). Five (13.2%) of the ESCC samples but none of the control samples were positive for the HPV16 E6/E7 gene ($P=0.05$). Three (7.9%) of the ESCC samples and 5 (13.2%) of the control samples were positive for the HPV18 E6/E7 gene ($P=0.71$) [28]

However, there are some other factors such as dietary and environmental factors as well as an ill-defined contribution from genetic predisposition that may be involved in pathogenesis of esophageal carcinomas. [29,30]

The present study also observed that most of esophageal tumor were over 50 years old, the observation was consistent with United state study by Enzinger and Mayer

,they found the risk factor increase with age- most patients are over 60, and median in United state is 67 [31].

Conclusion: The findings of the present study indicate that there is no association between HPV infection and development of esophageal squamous cell carcinoma in the cases evaluated.

References:

1. Parkin DM, Bray F, Ferlay J, Pisani P. Global cancer statistics, 2002. *CA Cancer J Clin.* 2005;55:74–108.
2. Devesa SS, Blot WJ, Fraumeni JF., Jr Changing patterns in the incidence of esophageal and gastric carcinoma in the United States. *Cancer.* 1998;83:2049–53.
3. Portale G, Hagen JA, Peters JH, et al. Modern 5-year survival of resectable esophageal adenocarcinoma: single institution experience with 263 patients. *J Am Coll Surg.* 2006;202:588–596.
4. Pennathur A, Luketich JD, Landreneau RJ, et al. Long-term results of a phase II trial of neoadjuvant chemotherapy followed by esophagectomy for locally advanced esophageal neoplasm. *Ann Thor Surg.* 2008;85:1930–1936.
5. Kountourakis P, Correa AM, Hofstetter WL, et al. Combined modality therapy of cT2N0M0 esophageal cancer: the University of Texas M. D. Anderson Cancer Center experience. *Cancer.* 2011;117:925–930.
6. Pera M, Manterola C, Vidal O, et al. Epidemiology of esophageal adenocarcinoma. *J Surg Oncol.* 2005;92:151–159.
7. Ferlay J., Bray F., Pisani P., Parkin D.M. GLOBOCAN 2002: Cancer Incidence, Mortality and Prevalence Worldwide. IARC Press; Lyon, France: 2004.
8. Kmet J., Mahboubi E. Esophageal cancer in the Caspian littoral of Iran: initial studies. *Science.* 1972;175:846–853.
9. Khuroo M.S., Zargar S.A., Mahajan R., Banday M.A. High incidence of esophageal and gastric cancer in Kashmir in a population with special personal and dietary habits. *Gut.* 1992;33:11–15. doi: 10.1136/gut.33.1.11.
10. Zaridze D.G., Basieva T., Kabulov M., Day N.E., Duffy S.W. Esophageal cancer in the Republic of Karakalpakstan. *Int. J. Epidemiol.* 1992;21:643–648. doi: 10.1093/ije/21.4.643.
11. Day N.E. Some aspects of the epidemiology of esophageal cancer. *Cancer Res.* 1975;35:3304–3307.
12. Vizcaino A.P., Moreno V., Lambert R., Parkin D.M. Time trends incidence of both major histologic types of esophageal carcinomas in selected countries, 1973–1995. *Int. J. Cancer.* 2002;99:860–868. doi: 10.1002/ijc.10427.
13. Holmes RS, Vaughan TL. Epidemiology and pathogenesis of esophageal cancer. *Seminars in Radiation Oncology.* 2007;17(1):2–9.

14. Wei W-Q, Abnet CC, Qiao Y-L, et al. Prospective study of serum selenium concentrations and esophageal and gastric cardia cancer, heart disease, stroke, and total death. *The American Journal of Clinical Nutrition*. 2004;79(1):80–85.
15. Syrjänen KJ. HPV infections and oesophageal cancer. *Journal of Clinical Pathology*. 2002;55(10):721–728
16. Syrjänen KJ. Histological changes identical to those of condylomatous lesions found in esophageal squamous cell carcinomas. *Archiv fur Geschwulstforschung*. 1982;52(4):283–292
17. Chang F, Syrjänen S, Shen Q, et al. Evaluation of HPV, CMV, HSV and EBV in esophageal squamous cell carcinomas from a high-incidence area of China. *Anticancer Research*. 2000;20(5 C):3935–3940.
18. Flint SJ, Enquist LW, Racaniello VR, et al. eds. Principles of Virology. Third Edition. Washington DC: ASM Press, 2009.
- 19 Syrjänen K. Geographic origin is a significant determinant of human papillomavirus prevalence in oesophageal squamous cell carcinoma: systematic review and meta-analysis. *Scand J Infect Dis* 2013;45:1-18
- 20 Shen Z-Y, Hu S-P, Lu L-C, et al. Detection of human papillomavirus in esophageal carcinoma. *Journal of Medical Virology*. 2002;68(3):412–416.
- 21 Sobti RC, Kochar J, Singh K, Bhasin D, Capalash N. Telomerase activation and incidence of HPV in human gastrointestinal tumors in North Indian population. *Mol Cell Biochem* 2001; 217: 51-56
- 22 Benamouzig R, Jullian E, Chang F, Robaskiewicz M, Flejou JF, Raoul JL, Coste T, Couturier D, Pompidou A, Rautureau J. Absence of human papillomavirus DNA detected by polymerase chain reaction in French patients with esophageal carcinoma *Gastroenterology* 1995; 109: 1876-1881
- 23 Poljak M, Cerar A, Seme K. Human papillomavirus infection in esophageal carcinomas: a study of 121 lesions using multiple broad spectrumpolymerase chain reactions and literature review. *Hum Pathol* 1998; 29: 266-271
- 24 Lagergren J, Wang Z, Bergstrom R, Dillner J, Nyren O. Human papillomavirus infection and esophageal cancer: a nationwide seroepidemiologic case-control study in Sweden. *J Natl Cancer Inst* 1999; 91: 156-162
- 25 LambotMA, Haot J, PenyMO, Fayt I, Noel JC. Evaluation of the role of human papillomavirus in oesophageal squamous cell carcinoma in Belgium. *Acta Gastroenterol Belg* 2000; 63: 154-156
- 26 Chang F, Janatuinen E, Pikkarainen P, Syrjanen S, Syrjanen K. Esophageal squamous cell papillomas. Failure to detect human papillomavirus DNA by in situ hybridization and polymerase chain reaction. *Scand J Gastroenterol* 1991; 26: 535-543
- 27 Zhou XB, Guo M, Quan LP, Zhang W, Lu ZM, Wang QH, Ke Y, Xu NZ. Detection of human papillomavirus in Chinese esophageal squamous cell carcinoma and its adjacent normal epithelium. *World J Gastroenterol*. 2003 Jun;9(6):1170-3.
- 28 Farhadi M. Human papilloma virus in Squamous cell carcinoma of esophagus in a high-risk population. *World J Gastroenterology*. 2005 Feb 28; 11(8):1200-3.
- 29 Bagheri Lankarani K, Mowla A, Asadian F, Tabei SZ, Panjeshahin MR. Changing epidemiology of esophageal cancer in Fars province, Iran. *Iran J Med Sci*. 2002;27:4-10.
- 30 Riddell RH. Early detection of neoplasia of the esophagus and gastroesophageal junction. *Am J Gastroenterol*. 1996;91:853-63.
- 31- Enzinger PC, Mayer RJ. Esophageal cancer. *N Engl J Med*. 349:2241–2252.