

Case report

Endolaser Treatment of Aesthetic Disorders: Clinical Experience of 4 Years

Alessandro Oliveira de Moura¹, Fábio dos Santos Borges*², Angelita Cristiane Ramos de Moura³

¹ Angelita Ramos Aesthetic Advanced Clinic, Santa Rosa-RS, Brazil

² Estácio de Sá University, Rio de Janeiro-RJ, Brazil

³ Angelita Ramos Aesthetic Advanced Clinic, Santa Rosa-RS, Brazil

Email Address: fabiborges2000@gmail.com

Abstract:

Introduction: Endolaser or Endolift, is a technique that uses a laser beam with a wavelength between 980 and 1470nm emitted through an optical fiber inserted into the subcutaneous tissue in order to tone the skin through neocollagenesis and reduce fat subcutaneous.

Objective: This study aimed to describe the clinical experience of the authors after four years using the endolaser technique treating different aesthetic disorders, and to this end, it was grouped data on the most treated disorders, personal protocols and treatment results.

Methodology: An exploratory research was carried out, presented in a narrative review to show the action of Endolaser used in the treatment of aesthetic disorders. The review explored scientific articles published and available in the following databases: MEDLINE (System for Analysis and Retrieval of Online Medical Literature), PubMed (National Library of Medicine), SCIELO (Scientific Electronic Library Online) and LILACS (Latin American and of the Caribbean in Health Sciences). In addition, some clinical findings obtained through a retrospective analysis of medical records were added to describe the clinical experience of the authors in using Endolaser for treating aesthetic dysfunctions.

Results: It was verified that the endolaser technique is extremely effective for reducing localized fat and skin retraction, and is characterized as an eligible procedure for face and neck, as well as for the body. Still, endolaser may be indicated for the treatment of several aesthetic disorders involving lipodystrophies and dermal disarrangement, in addition, associated with other therapeutic resources such as microfocused ultrasound, cryolipolysis, chemical peeling, intradermotherapy and others. The technique is safe and has minimal side effects.

Conclusion: As a conclusion, the current popularization of Endolaser is justified by its extreme effectiveness and versatility, as well as its ease usability and minimal adverse effects, producing excellent aesthetic results in the short and medium term, and can also be used alone or associated with other therapeutic resources.

Keywords: Endolaser, Endolift, Laser lipolysis, aesthetics, rejuvenation, skin sagging, wrinkles, cellulite and lipodystrophy.

Introduction:

Since a few years in clinical practice, it has been seen a daily growth in demand for treatments able to treat different aesthetic disorders. However, for some people these therapies are still expensive, especially when it involves plastic surgery. Among these aesthetic changes, those arising from natural aging process or aggravated by external factors related to daily living habits stand out. In addition, tonic skin dysfunctions, localized lipodystrophies, aesthetic dysfunctions caused by surgical sequelae or unsuccessful aesthetic treatments also stand out.

Normally, the use of aesthetic procedures has the epidermis and dermis as its main target, and then, laser-based treatments, intense pulsed light (IPL) and radiofrequency (RF) are considered good therapeutic options aimed at neocollagenesis [1]. Based on the aging process, which can also affect periorbicular bags, as well as ligament laxity of the face, ptosis, etc., other technologies have emerged for treatment, such as Microfocused Ultrasound (MFU), which is capable of generating neocollagenesis in structures of the skin and in the deeper layers, such as the superficial musculoaponeurotic system (SMAS), fundamental for face supporting [2].

Going further the dermal-epidermal layer, dysfunctions of the subcutaneous tissue occupy an important place in the search list for aesthetic treatments. Although liposuction surgery is very popular for localized fat reduction, recovery process after surgery and the risk of complications have led some patients to seek less expensive treatments, also with a shorter recovery time and, mainly, with a lower risk of adversities [3].

Ablative lasers such as the Erbium Laser can eliminate the outermost layer of the skin at the same time heating its deeper layers to increase the growth of new collagen fibers. However, many patients prefer treatment with non-ablative lasers [4].

Endolaser technique [5, 6], also known as Endolift [7-9] is a technique aims to lift (to make it hard) the tissues within the skin using an optical fiber as thin as human hair [10]. Previously, the terms Endolaser and Endolift were associated with liposuction techniques where the optical fiber emitting the laser was used inside the cannulas [5, 6]. Currently, these terms are associated with the technique that uses equipment without the liposuction procedure, and are considered non-invasive [3, 8] or minimally invasive [9]. It is by the reason of emitting only a laser beam with a wavelength in the range between 980nm and 1470nm through an optical fiber inserted in the superficial subcutaneous tissue in order to reduce subcutaneous fat and tone the skin through neocollagenesis.

This non-invasive laser therapy technique can reduce facial wrinkles and glabellar frown lines, as well as improve skin texture and tone. To this end, endolaser stimulates growth of collagen, increases the dermis thickness and makes the underlying skin firmer and without injuries [2, 4]. In addition, it can also treat various lipodystrophies such as localized adiposities and cellulite [3, 5, 7], as well as unaesthetic situation of mandibular border and “marionette lines”, “double chin”, middle facial and nasolabial folds, periorbicular changes of the eyes [10], acne vulgaris and acne scarring [11, 12], and others.

Endolaser has become commonly known in Brazil, and many professionals have used it to treat several aesthetic disorders with a variety of protocols and extremely effective therapy. As such, this study aimed to describe four years of clinical experience using the endolaser technique without the liposuction procedure for treating different aesthetic disorders, and for this, it was carried out a retrospective analysis of medical records in order to gather information about the most treated disorders, personal protocols and treatment results, as well as a brief discussion of data described in the world literature.

Methodology:

This study is characterized by exploratory research, presented through a narrative review to highlight the action of Endolaser technique used in the treatment of aesthetic dysfunctions. The review approached scientific articles, published and available in the following databases: MEDLINE (Medical Literature Analysis and Retrieval System Online), PubMed (National Library of Medicine), SCIELO (Scientific Electronic Library Online) and LILACS (Latin American and Caribbean Literature in Health Sciences).

As inclusion criteria, it was selected sources which mentioned the aesthetic disorders treated by endolaser or described its mechanism of action and techniques involved in the treatment of these aesthetic disorders. Sources discarded were those which did not present the abstract, those that were not allocated in scientific journals and did not address the subject of the study, as well as those that did not subsidize the collection of reliable data.

The bibliographic survey was carried out in Portuguese, English and Italian, with the following descriptors: Endolaser, Endolift, Laser lipolysis, aesthetics, rejuvenation, skin sagging, wrinkles, cellulite and lipodystrophy.

In addition to the bibliographic review, it was added to this study a data survey contained in the medical records of patients treated for four years (2019 to 2023) in the city of Santa Rosa-RS, Brazil to describe the

clinical experience of the authors who used the endolaser technique with personal treatment protocols in the care of many facial and body aesthetic disorders.

Results and Discussion:

The term Endolaser has already been mentioned in the literature since the beginning of the 2000s. During this period, CO₂ and/or Erbium YAG lasers using was common and the goal was to achieve aesthetic results and broader rejuvenation in a less traumatic way, also having minimal morbidity. [13]. Initially, the technique was performed by associating a microcannula with an optical fiber for laser emission, and over the years it was detected that the laser could liquefy adipose tissue, coagulate small blood vessels as well as induce neocollagenesis with tissue remodeling and stiffening [14-16].

Although the essence of Endolaser action was initially concentrated in the subcutaneous tissue (superficial or deep), its effects on the dermis were overwhelming [17]. Authors compared classic liposuction with laser-assisted liposuction (Lipolaser) and the found results showed a significantly higher rate of tissue contraction on the laser-treated side than on the liposuction side alone. On the non-laser treated side, mean skin tightness and skin tightening showed no statistically significant difference from the untreated side. Three months after treatment, skin tightness and tightness were significantly greater on the laser-treated side [18]. Therefore, although endolaser concentrates its action on the subdermal tissues, when used on the face, it is capable of rejuvenating through three strategic methods: suspension of soft tissues, photoaging reversal and correction of volume decreasing [13].

The technique was firstly described using diode and ND:Yag lasers with wavelengths ranging from 920nm to 1440nm as described in Table 1 [19].

SYSTEM	WAVE LENGHT(nm)
Nd:Yag	1064nm
Nd:Yag	1320nm
Nd:Yag	1064nm/1319nm
Nd:Yag	1064nm
Diodo	980nm
Diodo	924nm/975nm
Diodo	920nm
Nd:Yag	1064nm/1320nm
Nd:Yag	1064nm/1320nm/1440nm

Table 1. Laser systems and their wavelengths previously used for the endolaser technique. At this time, they were associated with the optical fiber emitting the laser and microcannulas for liposuction. (Source: McBean et al., 2011) [19]

Currently, this technique has become popular and the market has adopted the diode laser with a wavelength of 1470nm as safe and effective for the endolaser technique, and it is commonly used without liposuction procedure, that is, only with fiber optics (Figure 1), so the technique became less aggressive, but maintaining its effectiveness for reducing the subcutaneous tissue and toning the skin (Figure 2) [3, 5, 6-9].

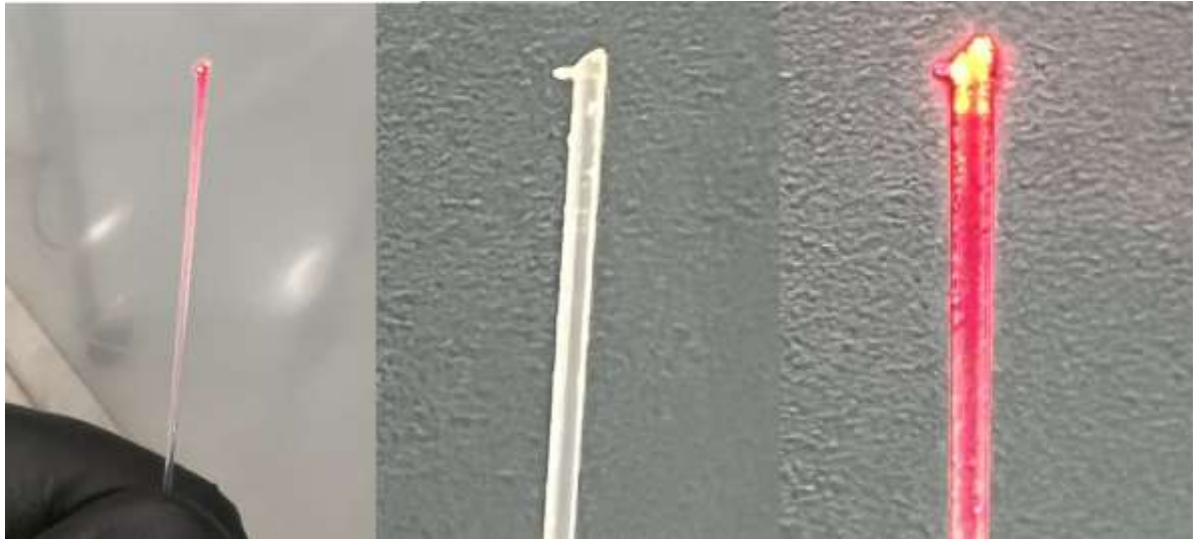

Figure 1. 400 microns optical fiber used in the endolaser technique.

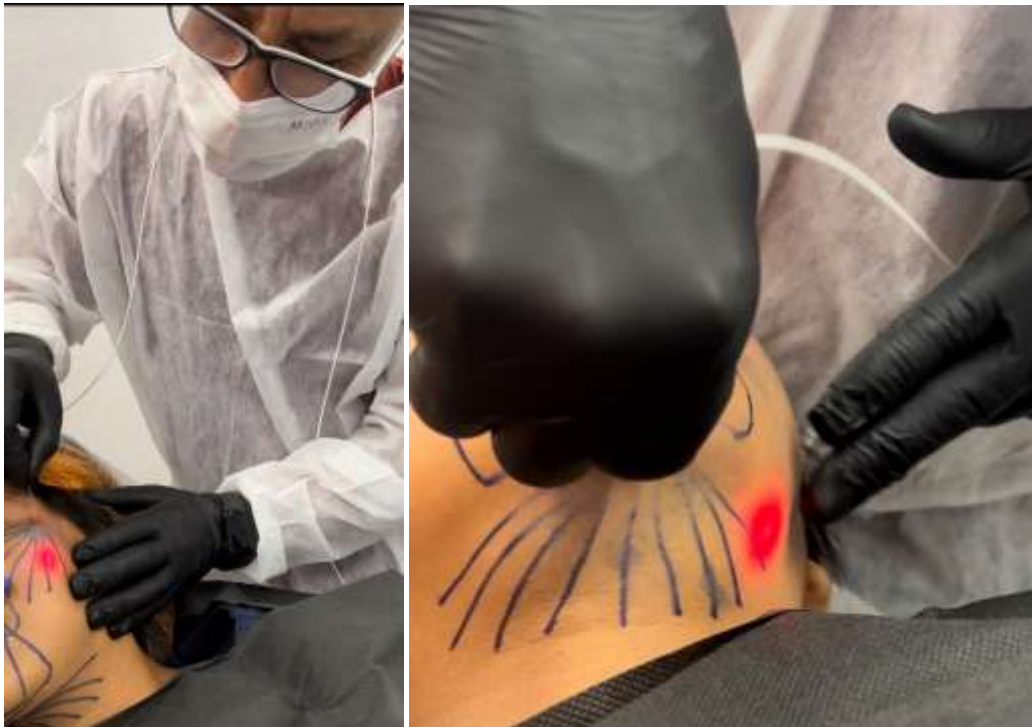

Figure 2. Endolaser marking and procedure on the face, and submental area using a 400 microns optical fiber and a 1470nm diode laser.

To produce the protocols described in this work, diode laser was used during all clinical practice with a wavelength of 980nm (Delight® - Vyndence Medical), which was also named as Fiber Lift. According to some authors [20], the 980nm diode laser devices have water (intra and extracellular) as a chromophore, however this wavelength also has recognized application in the coadjuvant treatment in liposuction, once over time it was discovered that there is an absorption curve of human fat that would have a different behavior compared to the laser action band on water. Thus, showing better absorption by fat than by water, which provides lipolysis without the need for high energy. Thus, this wavelength has been shown to be an excellent method for uniform fat solubilization (laser lipolysis by changing the permeability of adipocyte membrane, and direct injury to the adipocyte caused by the laser photothermal action).

Authors reported that the 1470 nm diode laser is able to deeply penetrate into tissues due to its high affinity for fat and water. As the richer a tissue is in water and fat, the better the transmission of this laser and the lower its dispersion [6]. Furthermore, fat is rich in glycerol which even facilitates the laser effectiveness [5]. It was demonstrated by a mathematical model that the photothermal effect of the endolaser technique may occur when the temperature reaches 48 to 50°C inside the tissues (0.8cm below the dermis) while on the surface of the skin the maximum temperature reaches 41°C. However, due to heat diffusion, temperature elevation is also produced within the lower reticular dermis. Therefore, while the heat caused by laser irradiation induces lipolysis of adipose cells, collagen and elastin in the dermis are also stimulated resulting in stiffening and accentuated skin retraction. It can take place either immediately or later, due to collagen stimulation. [20, 21].

For this study, the medical records of some patients treated by the authors in the period between 2019 and 2023 using the endolaser were selected. The average age of those treated was 53 years old, ranging between 44 and 63 years old.

All patients were examined aiming to extensively discuss the therapeutic procedure and all risks involved. Still, pre-procedure exams were requested and evaluated before treatment. Patients signed the pre-procedure informed consent form and authorized the publication of images of post-treatment results.

Some patients underwent treatment with Endolaser associated with other therapeutic resources.

The regions target to be treated were marked in detail before the procedure, and for that, the patients were positioned sitting (face and submental) (Figure 2) or in body orthostasis.

Patients were submitted to anesthetic infiltration in the port points with Lidocaine 1-2% with vasoconstrictor (epinephrine hemitartrate) and the puncture was usually performed with a 21G needle. Further, it was performed a uniform infiltration of the same anesthetic by using of a 22G cannula by retrograde injection in each line traced for optical fiber use (Figure 3). All received Diprospan administered via intramuscular before beginning the procedure, aiming to control and reduce post-treatment inflammation and edema. The areas submitted to treatment were then degermed with degerming chlorhexidine, and antisepsis was performed with alcoholic chlorhexidine.

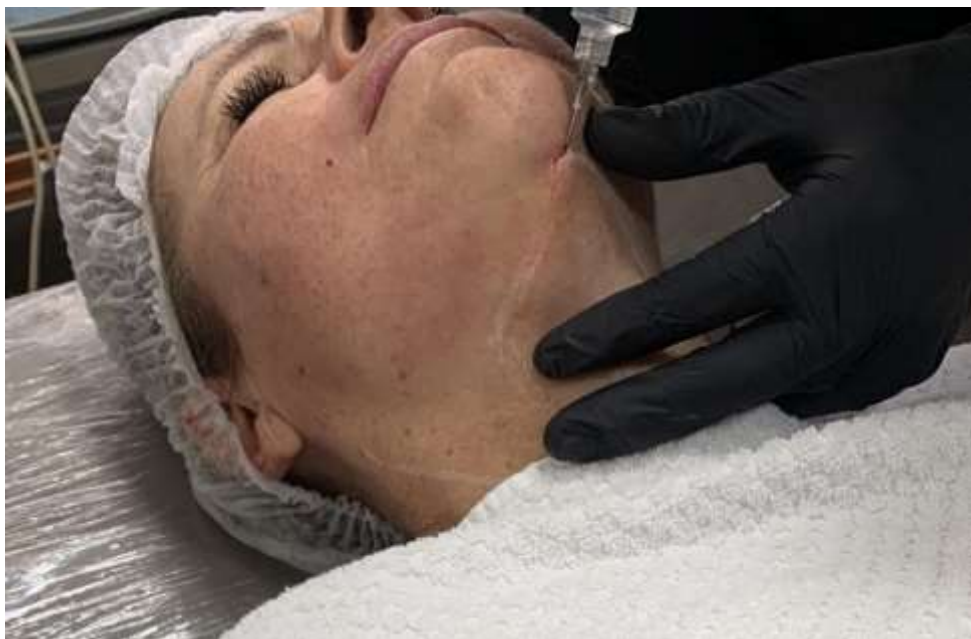

Figure3. Application of meshes pre-procedure anesthetic solution

For the laser treatment, the Delight® device (Vydenze Medical, Brazil) was used with optical fibers of 300 to 600 microns in diameter and with a wavelength of 980nm, emission of pulses in continuous mode, and power that varied between 4 and 6 W, with its accumulated energy between 600 and 2,000 J. This parameterization was individualized, according to clinical evaluation and also based on the treatment protocols from the equipment manufacturer used in this trial.

Optical fiber pass was performed at the subdermal level with pedal activation only when the fiber was removed, repeating it for 3 times in each location and the movement speed of the optical fiber was about 4 to 5 cm per second. The fiber was passed in the direction of the marking in a “fan” format (Figure 2) from the incision (hole), and the distance between each marked line was approximately 1 cm. After the procedure, a manual mechanical manipulation was performed to remove the emulsified fat and remnants of the anesthetic solution through the fiber optic insertion hole.

In practice, the endolaser produces the laser lipolysis effect, as it has an effective action for the liquefaction of fatty tissue through photothermolysis [14-16]. According to some authors, laser lipolysis is indicated for any location where there is unwanted adipose tissue and modest skin laxity. Still reported that the ideal candidate for laser lipolysis should be a thin, healthy patient with isolated “bags” of removable fat [19]. Scrimali et al. [5] reported the efficacy and safety of the endolaser to improve the facial contour reducing the aesthetic appearance of the treated region. In figure 4, it is shown the result of the treatment of a patient using the endolaser who aimed “emptying” of the localized fat on the cheeks and skin retraction, thus helping to reduce the unsightly appearance of the nasolabial folds.

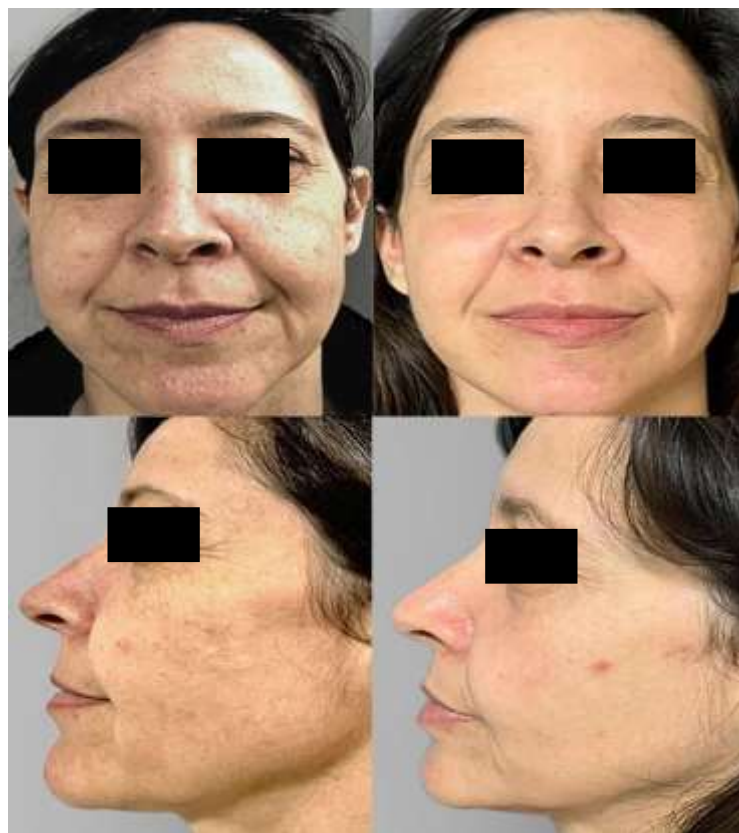

Figure 4. Main complaint: Excessive subcutaneous fat on the cheeks and sagging of the middle and lower 1/3 of the face. After 1 endolaser session (980nm), it was possible to notice the emptying of the fat cheeks, a decrease of nasolabial folds depth and an improvement in the skin quality.

Applying Endolift on the face may involve the treatment of only one or two areas (specific actions) of several regions in the same treatment session (Full Face Rejuvenation). Based on clinical practice backgrounded this work, facial rejuvenation using laser only with the optical fiber can also be performed with the association of other therapeutic resources, since it is understood that as the optical fiber is used below the dermis, the most superficial skin is not able to fully benefit from the laser's lifting effect when it is very aesthetically compromised.

Authors [22] reported that Endolaser associated to other techniques is incorporated into the treatment regime of several professionals who work with the technique, for instance, the fractional carbon dioxide laser can be associated to internally and externally improve neocollagenesis and the tightening of the skin.

Dell'Avanzato, [23, 24] cited the use of Microfocused Ultrasound after the Endolift for the “gentle” rejuvenation of face, neck and body, looking for the maximum result possible by working deeper the middle and deeper hypodermis to the muscular fascia (SMAS), thus seeking to obtain an immediate and long-term lifting. Authors [25] treated 96 individuals with sagging skin in the lower third of the face using Endolift associated with laser photobiomodulation (multi-wavelength), and found that the group that used both resources obtained better therapeutic results when compared to the groups that used the same resources separately. Based on these reports, the clinical practice applied in this work, it was used many associations in order to reach the skin as a whole (superficial and deep), and thus obtain the best result mainly when the subject is facial rejuvenation.

In figures 5 and 6 it is noticed results with the Endolaser use associated with other resources such as microneedling and chemical peeling for facial rejuvenation. They are applied together 15 and 45 days after using the Endolaser, respectively.

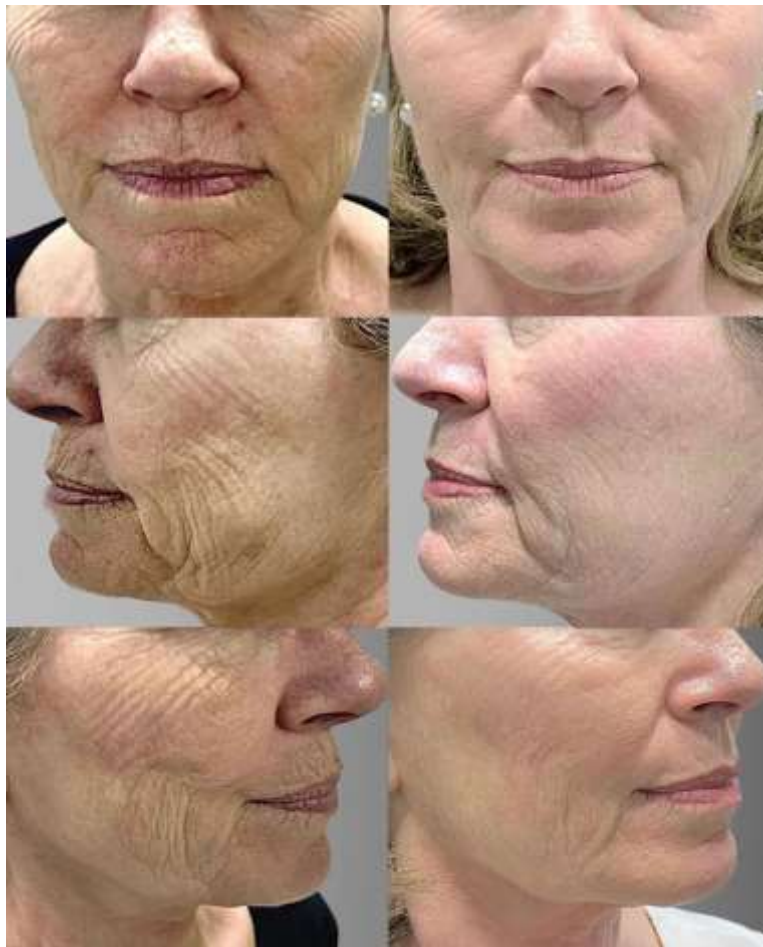

Figure 5. Before and after the treatment aimed at facial rejuvenation of a 64-year-old patient. Endolaser was used in association to other therapeutic resources. The patient was followed up at 15 and 45 days after endolaser for treatment with microneedling and chemical peeling, respectively.

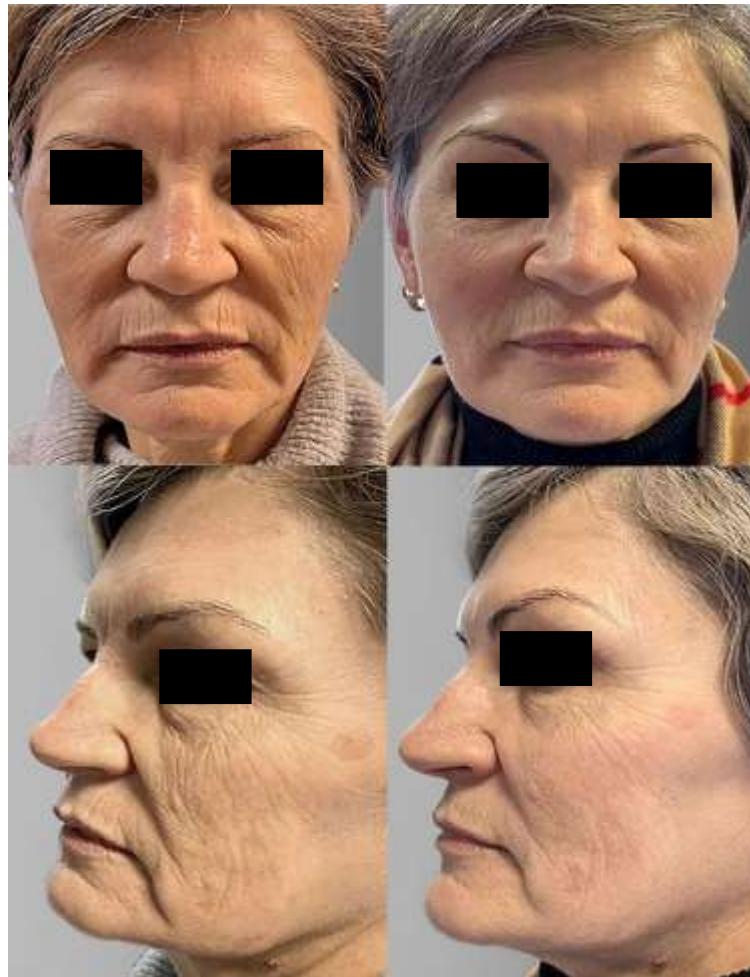

Figure 6. Before and after the treatment aimed at facial rejuvenation of a 63-year-old patient. Endolaser was used in association to other therapeutic resources. The patient was followed up at 15 and 45 days after Endolaser for treatment with microneedling and chemical peeling, respectively

Besides the association with microfocused ultrasound, microneedling and chemical peeling, in this work, endolaser was also associated with plasma jet for cases of upper palpebral ptosis, PDO threads for smoothing the nasolabial folds or deep wrinkles, in addition to radiofrequency and ozone therapy.

Nilforoushadeh et al. [4] verified that the Endolift procedure is able to significantly increase thickness and elasticity of the skin. However, authors [26] reported that heat generated in the skin by thermotherapeutic resources may be useful for several clinical purposes in aesthetic dermatology, such as reducing flaccidity and improving body contour. But tissue retraction induced by heat depends on several factors, including the maximum temperature reached, the time of exposure to heat and tissue hydration.

For this reason, it is still recommended that, from the indication of treatment with endolaser, both before and after procedure, it must ensure the skin quality, especially regarding the level of hydration, since it allows the skin to respond better to the photothermal stimulus, thus guaranteeing better results and favoring a faster recover skin y.

Endolaser use for aesthetic body disorders is efficient and with promising results. The main body conditions treated are localized fat in the inner region of the arms, abdomen, inner thighs, knees, ankles [3, 10], cellulite [7], and body flaccidity [27].

In figure 7 it is seen the result of the treatment to reduce fat and flaccidity in the dorsal and lateral regions of the body, as well as in the abdominal region and flanks using the Endolaser. Two treatment sessions were required with an interval of 30 days between them (the patient received 10 sessions of manual drainage after endolaser application. Also, the patient used a compressive mesh for 30 days). In this case, the results obtained were reduction of localized fat and skin sagging.

The therapeutic resources that are able to be associate with the Endolaser in the body treatment range from those addressed to booster the reduction of residual subcutaneous fat after fiber optic treatment, those destined to improve skin or cellulite quality. Intradermotherapy is one of these resources as dermally or subdermally injection of actives can support any aesthetic treatment involving these tissues [28, 29].

In Figure 8 it is shown the result of the buttock lifting treatment. The patient received an endolaser session associated with dermal/subdermal intradermal therapy with an injectable product of biostimulators in order to produce a toning and revitalizing effect in the gluteal region (GLUTEOMAX®, PHD Estética, Brazil). The client received intradermotherapy 15 days after treatment with Endolaser. Still, after the Endolaser session, patient was instructed to use a compressive mesh for 15 days, by the other side. After intradermotherapy she was instructed to avoid using compressive clothing for 30 days.

Manual lymphatic drainage and 3 MHz ultrasound were described as recommended resources in the first days after the Endolift or Laser lipolysis aiming to control and reduce the inflammatory process, as well as for the treatment of small areas with fibrosis [30, 31].

Cryolipolysis can play an important role in enhancing the effects of Endolaser, especially in cases of large fat deposits [32, 33], it can enhance even more skin toning, preventing sagging once it promotes skin toning by stimulating collagen [34, 35].

In Figure 9 it is demonstrated the abdominal liposculpture procedure using the endolaser, which is characterized by the emulsification of the fat associated with the dermal lifting in order to generate an aesthetic definition of the structures of the abdominal region. After the procedure, the patient was treated with sessions of manual lymphatic drainage and therapeutic ultrasound for 10 days aiming at reducing the inflammatory edema. After 60 days, a treatment with cryolipolysis was carried out in the abdominal region in order to increase skin adherence and highlight the natural appearance of the contours caused by the action of endolaser, highlighting patient's abdominal muscles (authorial technique called "Fiber Lift HD"). It is important to emphasize that this technique was also used to reduce fat located on the flanks.

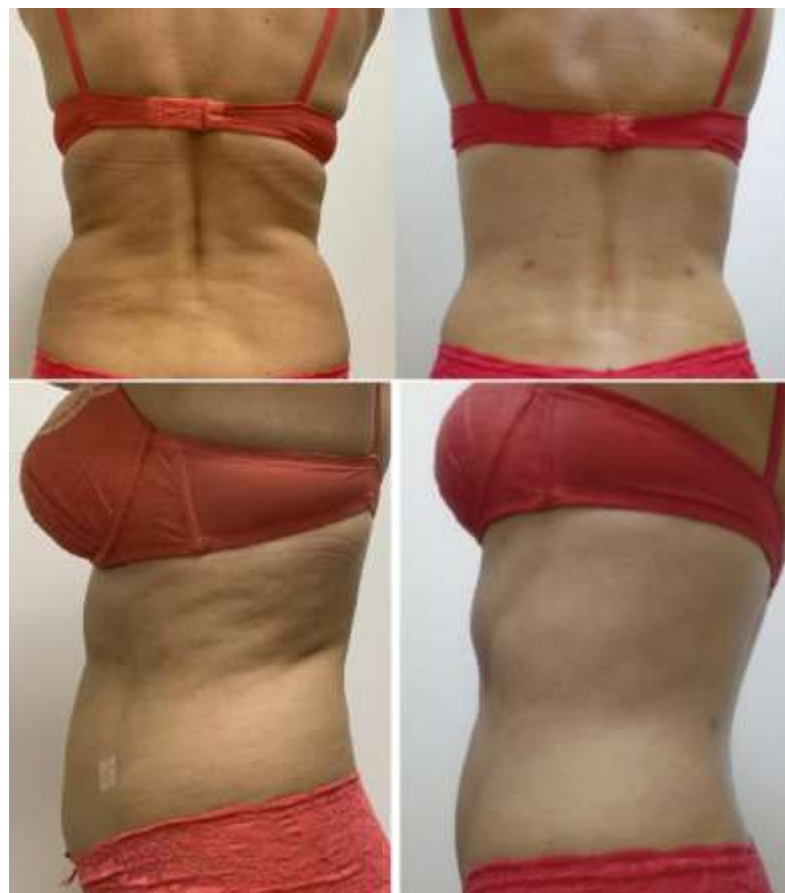

Figure 7. A 57-year-old patient underwent two treatment sessions to reduce localized fat and skin flaccidity in the dorsal, lateral, abdominal and flank regions.

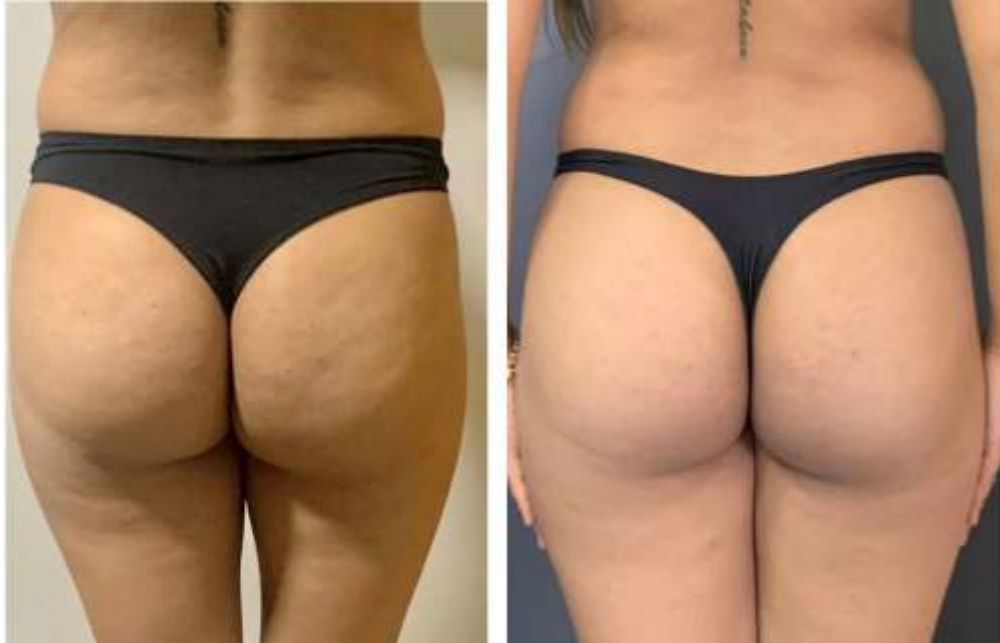

Figure 8. A 32-year-old patient underwent a butt lift with Endolaser associated with intradermotherapy with biostimulating actives. It is noticed in the image an intense improvement in skin quality (decrease in flaccidity and cellulite) and volumization of the entire gluteal region 60 days after treatment.

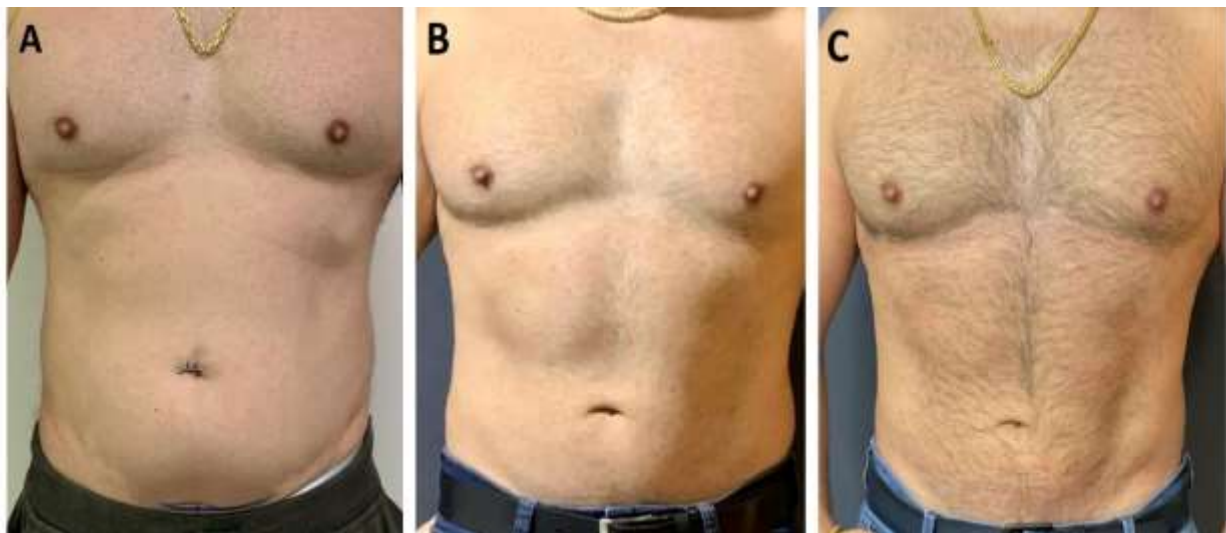


Figure 9. A 44-year-old patient underwent the Fiber Lift HD technique for aesthetic “definition” of structures in the abdominal region. For this, the patient received a combination of Endolaser associated with cryolipolysis. (A) Before endolaser treatment; (B) 60 days after treatment with Endolaser and cryolipolysis; (C) 45 days after cryolipolysis.

Both on the face and on the body, the use of girdles, bands, bandages, tapings and micropore after Endolaser treatment is something common in the clinical practice of many professionals. It is done to exert local pressure and favor post-treatment recovery. After laser lipolysis, some authors [31] recommend the use of specific commercial compressive meshes for each area during a period that can vary from two weeks (submental region) to four weeks (abdominal region, flanks and breeches). Marysabel & Oscar [36] recommended the use of micropore adhesive up to 72 hours after the facelift with Endolaser, from this period on, their patients used a submental girdle at least 12 hours a day, for 30 days. However, there are authors [30] who did not ask for any compression resource when treating cutaneous ptosis on the face and

neck with endolift. In this work, it was recommended the use of a compressive mesh after body endolaser when large fat deposits removed, but it was not recommended to use compression artifacts when performing facial endolaser; Patient registered in figure 7 wore a compressive mesh for 30 days.

The technique is considered by many as safe and has a few or no adverse effects. There are reports of post-treatment mild edema and erythema, which were resolved within a few hours or up to 3 days [4, 9, 25, 37]. There was a report of only one patient who treated acne scars and presented mild hypoesthesia in the cheek region, which was solved in seven days. The pain experienced by patients was considered mild to moderate (mean score 3.1 out of 10) [37]. However, some authors [3, 36] described there was no adverse effects or residual pain reported by any patient during studies carried out. Throughout this clinical practice, it was verified that no patient had burns, vascular lesions, pain or paresthesia. Three patients had mild hematomas in the orifice area with spontaneous resolution within thirty days.

Conclusion:

The evolution of endolaser technique, it is no longer used as a liposuction instrument and started to be used only as laser therapy through optical fiber, and also allowed its expansion to several outpatient clinics and professionals, this enabled its popularization in Brazil.

All clinical practice used in this work has shown that the technique is efficient both for dysfunctions involving the face and neck, as well as for body disorders. Results from this article corroborate authors [38] who described the effectiveness of the 980nm wavelength as effective for the endolaser. And it was verified that this is a procedure which allows its use associated with other therapeutic resources in order to enhance its results.

As a conclusion, the current popularization of endolaser is justified by its extreme effectiveness and versatility, as well as its ease usability and minimal adverse effects; producing excellent aesthetic results in the short and medium term, and can also be used alone or associated with other therapeutic resources.

Conflict of interest


The authors declare that there are no conflicts of interest in the publication of this article.

References:

- [1] Fabi SG, Goldman MP. Retrospective evaluation of micro-focused ultrasound for lifting and tightening the face and neck. *Dermatol Surg*. 2014;40(5):569-575. doi:10.1111/dsu.12471
- [2] Oni G, Hoxworth R, Teotia S, Brown S, Kenkel JM. Evaluation of a microfocused ultrasound system for improving skin laxity and tightening in the lower face. *Aesthet Surg J*. 2014;34(7):1099-1110. doi:10.1177/1090820X14541956.
- [3] Nilforoushadeh, MA, Heidari-Kharaji, M, Fakhim, T, et al. (2023). Efficacy of Endolift laser for arm and under abdomen fat reduction. *J Cosmet Dermatol*; 00: 1- 5. doi:10.1111/jocd.15684.
- [4] Nilforoushadeh, Mohammad Ali & Fakhim, Tannaz & Heidari-Kharaji, Maryam & Torkamaniha, Elham & Nouri, Maryam & Rohaninasab, Masoumeh & Behrangi, Elham & Hanifnia, Amirreza & Goodarzi, Azadeh. (2022). "Endolift laser an effective treatment modality for forehead wrinkles and frown line". *Journal of cosmetic dermatology*. 21. doi:10.1111/jocd.14884.
- [5] Scrimali L, Lomeo G, Dell'Avanzato R, Crippa A. (2013). Endolaser soft-lift: a new approach on body contouring. Perspective and suggestions. *Eur. J. Aesth. Medicine and Dermatology*;3(3):86-90.
- [6] Scrimali L, Lomeo G. (2015). Endolaser soft lift: from theory to practice. *Aesthetic Medicine Volume 1 • Number 1 • April-June*.
- [7] J. Sigova, D. Kaliterna, A. Abdelmaksoud and Kamalska, M. (2023). Progressive Lipodystrophy: topical laser treatment with Endolift® procedure using Eufoton® LASEmaR®1500 1470-nm wavelength. *Journal of Applied Cosmetology*. 41, 1 (Feb. 2023), ahead of print. doi: <https://doi.org/10.56609/jac.v41i1.66>.
- [8] Nilforoushadeh, Mohammad Ali & Heidari-Kharaji, Maryam & Fakhim, Tannaz & Hanifnia, Amirreza & Nouri, Maryam & Rohaninasab, Masoumeh. (2022). Endolift laser for jowl fat reduction:

- clinical evaluation and biometric measurement. *Lasers in Medical Science*. 37. 1-5. doi:10.1007/s10103-021-03494-9.
- [9] Dell'Avanzato, R. (2022). Endolift® the “lunch-time” laser lifting for the lower eyelids. *Laser Therapy*. 29. Doi:10.4081/ltj.2022.307.
- [10] **Dell'Avanzato, R. & Dell'Avanzato, G.** *Endolift®: lunch-time laser lifting with no downtime. Aesthetic & Anti-Aging Medicine World Congress. Monte Carlo, Monaco, Sep/2021.*
- [11] Sadoughifar, R & Abdelmaksoud, A & Türsen, B. (2023). Topical treatment of acne vulgaris: Endolift® direct optical energy combined with LIGHTSCAN™ fractional laser. *Journal of Applied Cosmetology*. 41. doi:10.56609/jac.v41i1.70.
- [12] Nilforoushadeh, M. A., Fakhim, T., Heidari-Kharaji, M., Hanifnia, A. R., Hejazi, S., & Torkamaniha, E. (2020). *Efficacy evaluation of Endolift-based Subcision on acne scar treatment. Journal of Cosmetic Dermatology*. doi:10.1111/jocd.13876
- [13] Badin, A., Casagrande, C., Roberts III, T. *et al.* Rejuvenescimento Facial Minimamente Invasivo Endolaser Mid-Face Lift. *Aesth. Plástico. Cirurg*. 25 , 447-453 (2001). <https://doi.org/10.1007/s00266-001-0023-9>
- [14] Goldman A, Schavelzon DE, Blugerman GS. Laser lipolysis: liposuction using Nd:YAG laser. *Rev Soc Bras Cir Plast*. 2002;17:17–26.
- [15] Ichikawa K, Miyasaki M, Tanaka R, et al. Histologic evaluation of the pulsed Nd:YAG laser for laser lipolysis. *Lasers Surg Med*. 2005;36:43–46.
- [16] Prado A, Andrade P, Dannila S, et al. A prospective, randomized, double-blind, controlled clinical trial comparing laser-assisted lipoplasty with suction-assisted lipoplasty. *Plast Reconstr Surg*. 2006;118:1032–1045.
- [17] DiBernardo, B.E., Reyes, R., Chen B. Evaluation of tissue thermal effects from 1064/1320-nm laser-assisted lipolysis and its clinical implications. *Journal of Cosmetic and Laser Therapy* 2009; 11: 62–69.
- [18] DiBernardo BE, Reyes J. Evaluation of skin tightening after laser-assisted liposuction. *Aesthet Surg J*. 2009;29(5):400–407.
- [19] McBean JC, Katz BE. Laser lipolysis: an update. *J Clin Aesthet Dermatol*. 2011 Jul;4(7):25-34.
- [20] Dornelles, R.F.V, Lima e Silva, A., Missel, J., Centurión, P. Laserlipólise com diodo 980 nm: experiência com 400 casos. *Rev. Bras. Cir. Plást*. 2013. Vol. 28(1):124-129.
- [21] Mordon SR, Wassmer B, Reynaud JP, Zemmouri J. Mathematical modeling of laser lipolysis. *Biomed Eng Online*. 2008 Feb 29;7:10. doi: 10.1186/1475-925X-7-10.
- [22] Stebbins WG, Hanke CW. Rejuvenation of the neck with liposuction and ancillary techniques. *Dermatol Ther*. 2011;24(1):28–41.
- [23] Dell'Avanzato, R. Endolift and Ultherapy for the best face, neck and body nonsurgical lifting. Joint Event on International Congress on Dermatology and Trichology & 2nd World Nephrology and Therapeutics Congress. Arch Gen Intern Med, September 20 - 21, 2018-Rome, Italy. doi: 10.4066/2591-7951-C5-015.
- [24] Dell'Avanzato, R. Endolift & Ultherapy: il miglior lifting non chirurgico per il volto e per il corpo. L'Ambulatorio Medico, n.54 maggio - agosto 2018, anno XVIII. Disponibile in: https://www.ambulatoriomedico.eu/numeri/AM_maggio_18.pdf
- [25] Longo, L., Dell'Avanzato, R., & Longo, D. (2022). ENDOLIFT® and multi-wavelength laser photobiomodulation: a randomized controlled trial study on 96 subjects, treating skin laxity of the lower third of the face. *Laser Therapy*, 29(2), 115–120. <https://doi.org/10.4081/ltj.2022.298>.
- [26] Bonjorno, A. R., Gomes, T. B., Pereira, M. C., Carvalho, C. M., Gabardo, M. C. L., Kaizer, M. R., & Zielak, J. C. (2019). Radiofrequency therapy in esthetic dermatology: A review of clinical evidences. *Journal of Cosmetic Dermatology*. doi:10.1111/jocd.13206.
- [27] Roberto, M. Endolift for the best face and body non-surgical lifting, *Dermatology & Cosmetology* 2020, October 15, 2020, Dubai, UAE.
- [28] González RMC, Galimberti D, Valdivia MDC, et al. Cellulite: A Combine Treatment with Mesotherapy, Laser and Radiofrequency. *Dermatología Cosmética, Médica y Quirúrgica*. 2015;13(1):13-19.

- [29] Casabona G, Pereira G. Microfocused Ultrasound with Visualization and Calcium Hydroxylapatite for Improving Skin Laxity and Cellulite Appearance. *Plast Reconstr Surg Glob Open*. 2017 Jul 25;5(7):e1388. doi: 10.1097/GOX.0000000000001388.
- [30] A. Markabayeva, D. Kaliterna, S. Karimov, A. Abdelmaksoud, M. Kamalska and I. Binić. Topical treatment of cutaneous ptosis: Endolift® treatment with 1470-nm wavelength Eufoton® LASEmaR®1500. *Journal of Applied Cosmetology*, Vol. 41 iss. 1 Jan-Jun, 2023
- [31] Tagliolato, Sandra; Barcellos Medeiros, Vanessa; de Sousa Teresani, Patrícia Cristiane; Gerin Leite, Oriete; Vilela Filipe, Janaína; Bassanezi Mazzaro, Carla; Accione Rover, Patrícia; Oliveira Fernandes, Renata Rita. Experiência em laserlipólise: casuística de 120 casos no período de 2004 a 2010, *Surgical & Cosmetic Dermatology*, vol. 3, núm. 4, 2011, pp. 282-287.
- [32] Ferreira, BG, Stroparo, E., Cezar-dos-Santos, F., Pestana, C.R. Reduction of Body Fat Mass by Cryolipolysis without Changes in Clinical Biomarkers Levels. *J Clin Med Surgery*. 2022; 2(1): 1011.
- [33] Meyer PF , Valentim da Silva RM , Rodrigues de Souza F , Farias SLQ , Santos de Vasconcellos L , de Moraes Carreiro E , Santos Borges F . Effects of Cryolipolysis with Plates in Localized Adiposity with the CrioPlace Concept. *Cryo Letters*. 2020 Jul-Aug;41(4):223-229.
- [34] Carruthers J, Stevens WG, Carruthers A, Humphrey S. Cryolipolysis and skin tightening. *Dermatol Surg*. 2014 Dec;40 Suppl 12:S184-9. doi: 10.1097/DSS.0000000000000229.
- [35] Stevens WG, Gould DJ, Pham LD, Jimenez Lozano JN. Molecular and Histological Evidence Detailing Clinically Observed Skin Improvement Following Cryolipolysis. *Aesthet Surg J*. 2022 Jan 1;42(1):56-67. doi: 10.1093/asj/sjab226.
- [36] Marysabel, Q, & Oscar, S. Efectividad de la técnica endoláser con plataforma diodo 980 nm en la ritidosis grado I y II. *RILMED*, Volumen 3 N° 1 – Marzo 2023.
- [37] Dell'Avanzato, R. Endolift: Subcision laser-assistita per le cicatrici da acne. *L'Ambulatorio Medico*, n. 62 maggio - mayo 2021. Disponibile in: https://issuu.com/ambulatorio-medico/docs/am_maggio_21/s/12304685
- [38] Nilforoushzadeh MA, Heidari-Kharaji M, Behrangi E, Lotfi E, Roohaninasab M, Nouri M, Najari Nobari N. Effect of Endolift laser on upper eyelid and eyebrow ptosis treatment. *J Cosmet Dermatol*. 2022 Aug;21(8):3380-3385. doi: 10.1111/jocd.14798. Epub 2022 Feb 1.



Open Access This article is licensed under a Creative Commons Attribution 4.0 International

License, which permits use, sharing, adaptation, distribution and reproduction in any medium or format, as long as you give appropriate credit to the original author(s) and the source, provide a link to the Creative Commons license, and indicate if changes were made. The images or other third-party material in this article are included in the article's Creative Commons license, unless indicated otherwise in a credit line to the material. If material is not included in the article's Creative Commons license and your intended use is not permitted by statutory regulation or exceeds the permitted use, you will need to obtain permission directly from the copyright holder. To view a copy of this license, visit

<https://creativecommons.org/licenses/by/4.0/>.