

Research Article**Angiographic study of double right coronary artery in Basra***Dr. Saja M. Ali¹, Dr. Hassna B. Jawad²*¹University of Basra, College of Medicine, Department of Anatomy, Histology and Embryology.²University of Basra, College of Medicine, Department of Anatomy, Histology and Embryology

Abstract: Splitting right coronary artery is a benign entity but the atherosclerotic changes once occurred the patient presented with acute coronary disease and even death. It is a very rare coronary artery anomaly and discovered incidentally during cardiac angiography or autopsy. Here the pathological and clinical scenarios of this anomaly should be taken into account: Arrhythmia, hemodynamic and cardiac surgery procedures.

Aim of study: To know the incidence of splitting or double right coronary artery among people in Basra by conventional coronary angiography.

Patients and Methods: Prospective study of coronary angiography carried out in Basra cardiac center at Al-Sadder teaching hospital. A sample of 150 patients attended to cardiac center with acute coronary disease.

Results: In our study the incidence of double right coronary artery was 3.3% and the mean length of anterior right coronary artery was 81.43 ± 2.22 mm and the caliber of this artery was 2.96 ± 0.76 mm while the mean length of posterior right coronary artery was 105.33 ± 3.36 mm and its caliber was 3.03 ± 0.732 mm.

Conclusion: Double right coronary artery is a benign coronary artery anomaly but it may be life threatening if it is associated with other congenital heart anomalies, atherosclerosis, arrhythmias or myocardial infarction.

1. Introduction :

Right coronary artery is one of the main coronary arteries. It arises from the right aortic sinus, passing anteriorly to the right then descends vertically through the right atrioventricular sulcus between the right atrium and the right ventricle on reaching the inferior margin of the heart, it turns posteriorly and continues in the sulcus in the diaphragmatic surface.^[1,2,3,4] The RCA supplies oxygen and nutrient to the right atrium, right ventricle, the bottom of the left ventricle, the interatrial septum, portion of the left atrium, the posteroinferior one-third of the interventricular septum and supplies 25% - 35% of the left ventricle.^[1,5,6,7]

The branches of right coronary artery are sinoatrial, conal, acute marginal, atrioventricular and posterior descending arteries.^[1,2,4,7]

A particular genetic background is responsible for the coronary artery anomalies especially during the crucial first eight weeks of the fetal development.^[8] A double right coronary artery is one of the rare coronary artery anomalies, different authors used special terms to define the double right coronary artery like "split right coronary artery, dual right coronary artery or duplicated right coronary artery".^[9] Some theories proposed that double right coronary artery is defined when both arteries supply the inferior left ventricle coursing down to reach the interventricular sulcus^{[9][10][11]} while others suggested that the two split right coronary arteries

originated either as single or two separated orifices from the right aortic sinus or from a single proximal trunk and run closely in the atrioventricular groove.^{[9][12]}

This anomaly is hemodynamically insignificant but it provides better collateral support in case of total occlusion of the left coronary artery.^{[9][12]} Patients with double right coronary artery are asymptomatic until an accidently discovered during coronary angiography.^{[9][13][14]}

This anomalous coronary artery poses a risk for earlier development of coronary atherosclerotic disease so the acute coronary syndrome is possible because of duplication of the artery, therefore the clinical presentations are the inferior myocardial infarction or anterior myocardial infarction.^{[9][13][14]} In addition, there are difficulties of this anomaly for the angiographer at the time of the catheterization with a challenge for the radiologist in interpretation.^{[15][16]}

The coronary intervention or cardiac operation is more complicated in individuals with a double right coronary artery. Therefore, it is important to obtain information on the anatomic variants of this congenital coronary anomaly in patients who are undergoing either coronary intervention, aortic root operation or myocardial revascularization.^[14]

2. Aim of The Study:

To know the incidence and morphological measurements of double right coronary artery in Basra.

3. Patients and Methods :

This angiographical prospective study was carried out in the cardiac catheterization center at Al Sadder Teaching Hospital ,Basrah governorate during the period extended from January 2013 to the end of August 2013 . The sample size was one hundred fifty cases (150) .The sample included patients who lived in Basrah and attended the center during the study period.

A structural questionnaires formula was developed and designed for the purpose of the study after being discussed with experts . All 150 cases were interviewed , the interview and data collection was carried out after taken a verbal permission from the patient to participate in this study .The patient should be stable at time of conventional angiographical study ,each patient should have done the following tests : the baseline ECG, electrolytes , renal function tests, complete blood cell count and coagulation test should be reviewed before coronary angiography .

Drugs used during coronary angiography : sedation as diazepam 5 - 10 mg intramuscularly, anticoagulants as heparinized saline is still required during routine coronary arteriography , contrast dye Ominopaque contrast media 350mg /1cc , the vial contain 100 cc given according to body weight and other drugs used according to the patient conditions these drugs included: intravenous fluid, adrenaline, atropine, hydrocortisone. The coronary angiographies were performed by the Judkin technique through femoral approach by using 6 French femoral sheath and diagnostic catheters .

Catheterization Equipments : The catheterization equipments used in cardiac catheterization center at Al Sadder Teaching Hospital were :

*Phillips angiographic equipment : which used in the center since 2008 and manufactured in Holland .

*General Electrical angiographic equipment : : which used in the center since 2012 and manufactured in USA.

4. Results:

This angiographical prospective study was carried out in the cardiac catheterization center for period extended from January 2013 to the end of August 2013 . The sample size was 150 cases ; male patients were 92 (61.3%) and the female patients were 58 (38.7%); the age of patients were ranged from 47 to 75 years (58 ± 5.6 years).In our study the incidence of split right coronary artery was 5 (3.3%) in general population. The incidence of double right coronary artery was more in male than female and more in patients who live in rural area ; the p values between double right coronary artery and gender and presidency were 0.035 and 0.042 respectively as shown in **Table 1, Table 2 , Table 3** .

The splitted right coronary artery was arising from a common single ostium in right coronary sinus; the anterior artery was S shape branched to acute marginal and the mean length was 81.43 ± 2.22 mm and the caliber of this artery was 2.96 ± 0.76 mm while the posterior artery was C shape terminated by

giving off posterior descending artery in posterior interventricular groove and the mean length was 105.33 ± 3.36 mm and its caliber was 3.03 ± 0.732 mm, these measurements revealed that the anterior right coronary artery was short and small in caliber when compared it with posterior right coronary artery as shown in **Table 4** .

The conal and acute marginal arteries were branched from anterior right coronary artery while the sinoatrial nodal artery and posterior descending artery were arose from posterior right coronary artery as shown in **Figure 1, Figure 2** .

Table 1. Distribution of cases according to double right coronary artery presentation.

Pattern of right coronary artery	Number of patients	Percentage
Single	145	96.7%
Double	5	3.3%
Total	150	100%

Table 2 .Distribution of double right coronary artery according to gender :

Pattern of right coronary artery	Male (n=92)		Female (n=58)		Total (n=150)		P value
	No.	%	No.	%	No.	%	
Single	88	95.7	57	98.3	145	96.7	0.035
Double	4	4.3	1	1.7	5	3.3	

Table 3 .Distribution of double right coronary artery according to presidency .

Pattern of right coronary artery	Urban (n=78)		Rural (n=72)		Total (n=150)		P value
	No.	%	No.	%	No.	%	
Single	77	98.7	68	94.4	145	96.7	0.042
Double	1	1.3	4	5.6	5	3.3	

Table 4 .The measurements of double right coronary artery .

Variables		Mean (mm)	Std. Deviation
Anterior right coronary artery	Length	81.43	2.22
	Caliber	2.96	0.76
posterior right coronary artery	Length	105.33	3.36
	Caliber	3.03	0.732

recognized 1.23%.^[19]

Also the incidence increased in patients who lived in rural area and there is no similar study related to this issue but this differences in the incidence may related to geographical and genetic bases^[20] or due to physicians in the other countries define this topic as high take off large ventricular artery from right coronary artery.^[21]

The incidence of double right coronary artery in our population was more common in male and the both arteries are originated from common or single ostium this agree with Sari *et al.*, 2008; Chen *et al.*, 2010.^[22, 23]

The first report about double right coronary artery anomaly was by Barthe *et al.*, 1999 who observed this artery arose from single ostium.^[24] The knowledge of the anatomical consequences of origin of double right coronary artery from single or separated ostia has its clinical cost. The origin of both arteries from single ostia its more common but has a disadvantages because the atherosclerotic coronary disease is higher.^[25] and this may lead to the stenosis of ostia leading to acute coronary syndrome as myocardial infarction or sudden death while double right coronary artery with two separated ostia is very uncommon and its associated with other anomalies as valvular diseases in the other hand the double right coronary artery with two separated ostia may miss diagnosed during coronary angiography when stenosis in one of these ostia at that time evaluation of patient is incomplete and symptoms remain unchanged.^[26]

In our study the double right coronary artery has anterior right coronary artery was S shape its mean length was 81.43 ± 2.22 mm and the caliber was 2.96 ± 0.76 mm while the posterior right coronary artery was C shape its mean length was 105.33 ± 3.36 mm and its caliber was 3.03 ± 0.732 mm ; there is no similar studies concerned in measurements of length and caliber but in general the authors offered a case of double right coronary artery with different sizes one is large caliber posterior located and small caliber anterior located and that synchronized to our results.^[18]

The conal and acute marginal arteries were branched from anterior right coronary artery while the sinoatrial nodal artery and posterior descending artery were arose from posterior right coronary artery here our results are disagree with Selcoki *et al.*, 2010; Kumar *et al.*, 2017^[8,27] who report the two right coronaries shared in formation of posterior descending artery.

The two different geometric shapes of double right coronary artery described by coronary angiography the C shaped and S shaped arteries that found C shaped artery more liable to atherosclerosis specially in proximal middle area than S shaped because of flow pattern is low shear stress along inner wall and the maximum differences of shear stress between inner and outer wall making it liable to formation of atherosclerosis^[28,29] Dvir *et al.*, 2003 assumed the S shaped right coronary artery is bending in the middle region causing different hemodynamic pattern and consequently have a lower probability to atherosclerosis.^[28]

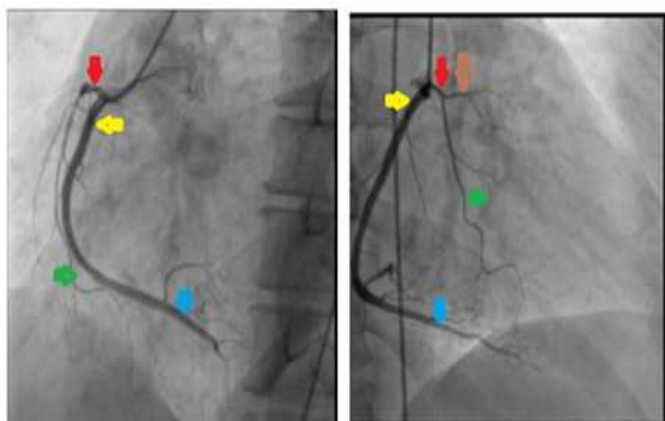


Figure 1. Coronary angiogram shown the double right coronary artery ; anterior right artery short and small caliber (red arrow) give rise to conal artery (brown arrow) and acute marginal artery (green arrow) . The posterior right artery long and large caliber(yellow arrow) gives posterior descending artery (blue arrow).

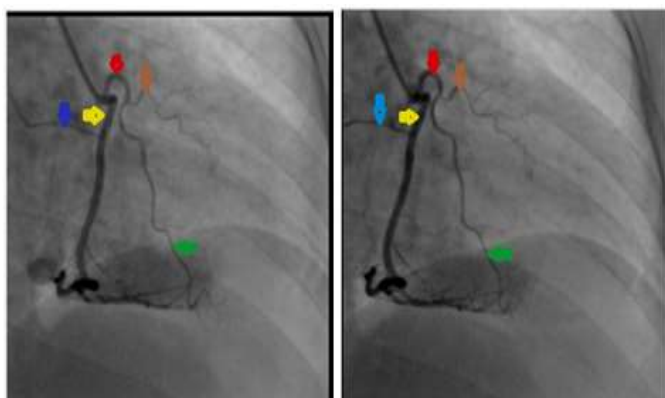


Figure 2. Coronary angiogram shown the double right coronary artery ; anterior right artery(red arrow) give rise to conal artery (brown arrow) and acute marginal artery (green arrow) . The posterior right artery (yellow arrow) gives sinoatrial nodal artery (blue arrow).

5. Discussion :

The double right coronary artery usually diagnosed by conventional coronary angiography or multi-detector computed tomography. In our study the incidence of double right coronary artery was 3.3% and that disagreed with Ermis *et al.*, 2014 ; Kunimasa *et al.*, 2007; Erbagci *et al.*, 2006 who found 0.01% , 0.07% and 0.01% respectively^[17,11,18] but our result nearly corresponded to Angelini *et al.*, 1999 who

6. Conclusion :

The cardiologist and cardiovascular surgeon must have a clear knowledge about this coronary anomaly in order to have a successful medical therapy and perfect cardiac operation planning and preventing the consequent errors in management .

References:

[1] Snell R.S. Clinical Anatomy , 7th edition . Lippincott Williams &Wilkins : Wolters Kluwer. 2004 ;105-117

[2] Drake R. L. , Vogl W., Mitchell A.W.M..Gray's Anatomy for Students. London : Churchill Livingstone. 2004;3:154-181

[3]Sunil Kini , Kostaki G.Bis ,Leroy Weaver . Normal and Variant Coronary Arterial and Venous Anatomy on High – Resolution CT Angiography . AJR 2007;188:1665-1674

[4] Hemant B Telkar .Multi –detector coronary angiography . Radiology 2002; 223 : 212 -220

[5] Bastarrika Aleman G, Alonso Burgos A, Azcarate Agüero PM, et al. Normal anatomy ,anatomical variants, and anomalies of the origin and course of the coronary arteries on multislice CT. Radiologia 2008 ;50(3):197–206

[6] Smuclovsky C. .Coronary Artery anatomy. Springer Science 2009; Ch(1):1-11.

[7]Cademartiri F, La Grutta L, Malagò R, et al. Prevalence of anatomical variants and coronary anomalies in 543 consecutive patients studied with 64-slice CT coronary angiography. Eur Radiol. 2008; 18:781-91

[8] Selcoki Y. , Yilmaz O. C. , Okan Er, and Eryonucu B. Double right coronary artery: a report of two cases. Clinics (Sao Paulo) 2010; 65(4): 449–451

[9] Barik R. , Damara SR. Hide and seek of double right coronary artery. Nig J Cardiol. 2016;13:157-8

[10] Sato Y., Kunimasa T., Matsumoto N., Saito S. Detection of double right coronary artery multi-detector row computed tomography : Is angiography still gold standard ? Int J Cardiol. 2008;126:134-5

[11] Kunimasa T., Sato Y., Ichikawa M., Ito S., et al . MDCT detection of double right coronary arising from single ostium in the right sinus of Valsalva : Report of 2 cases. Int J Cardiol .2007;115:239-41

[12] Misuraca L., Balbarini A. Double right coronary or split right coronary : The same anomaly ? J Cardiovasc Med (Hagerstown). 2010;11:398

[13] Acet H., Ozyurtlu F., Zihni M. B., Ertas F., A Rare Coronary Anomaly: Atypical Double Right Coronary Artery With an Acute Inferior Myocardial Infarction. Korean Circ J. 2012 Mar; 42(3): 208–211

[14] Chien TM. , Chen CW., Chen HM . , Lee CS. , et al. Double right coronary artery and its clinical implications. Cardiol Young. 2014 Feb;24(1):5-12

[15] Greenberg MA. , Fish BG., Spindola-Franco H.

Congenital anomalies of the coronary arteries. Classification and significance. Radiol Clin North Am. 1989 Nov;27(6):1127-46

[16] Shin Eun Lee, Myung Ho Jeong ,Jong Pil Park , Sung Hee John, et al. Congenital anomaly of the true double- lumen right coronary artery: An extremely rare case . Journal of Cardiology Cases .2010;1:e6-e8

[17] Ermis E., Ipek E., Demirelli S. Double right coronary artery arising from separated ostia . Journal Of Case Reports.2014 ;4(1): 206-208

[18] Erbagci H., Davutoglu V., Turkmen S., Kizilkan N., et al. Double Right Coronary Artery: Review of Literature The International Journal of Cardiovascular Imaging. 2006; 22(1):9-11

[19] Angelini P, Villason S, Chan AV, Diez JG. Coronary artery anomalies: a comprehensive approach. Lippincott Williams & Wilkins (Wolters Kluwer): 1999 ;27–79

[20] Topaz O, De Marchena EJ, Perin E, Sommer LS , et al . Anomalous coronary arteries: angiographic findings in 80 patients. Int J Cardiol . 1992; 34:129-138

[21] Akçakoyun M, Acar G, Avcı A, Kargın R, et al . Double right coronary artery co-existing with separately originating left anterior descending and circumflex arteries. Eur J Gen Med. 2010;7:345–7

[22] Sari I, Kizilkan N, Sucu M, Davutoglu V., et al. Double right coronary artery: report of two cases and review of the literature. Int J Cardiol. 2008;130(2):e74-7

[23] Chen HY. Aberrant origin of the conus branch: Diagnosis of split right coronary artery with two separate ostia by conventional angiography. Exp Clin Cardiol. 2010;15:9–10

[24] Barthe JE, Benito M , Sala J , Houbani AJ ,et al . Double right coronary artery . Am J Cardiol . 1994;73:622

[25] Joshi A., Solanki N., Bhuta M., Bava JS. Case of Double right coronary artery: Diagnosed on Computed Tomography Coronary Angiography. Heart India .2015; 3: 108-11

[26] Kheirkhah J, Habibifar A, Moladoust H. A case of double right coronary artery with separate ostium. J Tehran Heart Cent. 2014;9(3):135-6

[27] Kumar S., SinghS, , Chaturvedi V., Agrawal P., et al. Atypical Double Right Coronary Artery Presenting With Acute Coronary Syndrome, Cardiogenic Shock and Complete Heart Block . J Clin Med Res. 2017; 9(3): 221–224

[28] Dvir D , Kornowski R, Gurevich J, Orlov B, et al. Degrees of severe stenoses in sigma-shaped versus C-shaped right coronary arteries . Am J Cardiol. 2003 ; 92(3): 294-8

[29] Güngör B , Alper AT, Ozcan KS, Ekmekçi A, et al. Presence of sigma shaped right coronary artery is an indicator of poor prognosis in patients with inferior myocardial infarction treated with primary percutaneous coronary intervention. Catheter Cardiovasc Interv. 2014;84(6):965-72