

*International journal of medical science and clinical Invention*  
Volume 1 issue 6 2014 page no. 339-344 ISSN: 2348-991X

## Kikuchi's Disease with Pleural Effusion – A Rare Case Report

Dr. Hemant Mahur<sup>1</sup>, Dr. D.P. Singh<sup>2</sup>, Dr. Kripa Shanker Jhirwal<sup>3</sup>

<sup>1</sup>Associate Professor, Department of Medicine

<sup>2</sup>Sr. Professor & Head, Department of Medicine

<sup>3</sup> Final Year Medicine Resident, Maharana Bhupal Associate Group Of Hospitals and R.N.T. Medical College, Udaipur

### Address for Correspondence:

Dr. Hemant Mahur,  
D-6, M.B. Hospital Campus,  
R.N.T. Medical College,  
Udaipur-313001  
Ph. 09829040103, 09610251730  
Email: drhemantmahur@yahoo.com , silverex96bar@gmail.com

### ABSTRACT:

*We report here an unusual case of a 26 year old female patients presenting with clinical features of moderate to high grade fever with chills and rigor, bilateral cervical and submandibular lymphadenopathy and left sided exudative pleural effusion. On lymph node biopsy patient was diagnosed as Kikuchi's disease. Our case of kikuchi's disease is unusual because patient had exudative pleural effusion which is not reported earlier in literature.*

**INTRODUCTION:** Kikuchi's disease, also known as Kikuchi Fujimoto disease; is an uncommon, idiopathic, generally self limited, disease with very rare recurrence and mortality. The cause of kikuchi's disease is unknown. It is three times more common in female and typically affect young adult. Kikuchi's disease most

frequently manifests as relatively acute onset of cervical adenopathy associated with fever and flu like prodrome. Other less common symptoms include headache, nausea, vomiting, malaise, fatigue, weight loss, arthralgia, myalgia, night sweat, rash and abdominal pain.

Besides lymphadenopathy, hepatosplenomegaly is not uncommon. Neurological involvement though rare can include condition such as Aseptic meningitis, acute cerebeller ataxia and encephalitis. Patients with aseptic meningitis may report headache, but they do not exhibit neck rigidity or positive Kernig's or Brudzinski's sign. CSF findings are similar to those noted in patients with aseptic meningitis of viral etiology. In patients with Kikuchi's disease laboratory and radiological finding are nonspecific. Although result of FNAC Lymph node may be suggestive, the diagnosis of Kikuchi's disease is confirmed only by excisional lymphnode biopsy.

**CASE REPORT:** A 26 year old female, home maker who was apparently well until three month back, was admitted with complaints of fever of three month duration and cervical lymph node swelling since one month. Her complaints started as moderate to high grade fever which was continuous, associated with chills and rigor, occurring during any time of the day and relieved by antipyretics. No history suggestive of weight loss, cough with hemoptysis, arthralgia, bone pain, rashes, pain abdomen, high risk sexual

behavior, occupational exposure to animals, urinary symptoms etc. From last one month she noticed painless swelling over both side neck, which was gradually increasing in size. Swelling was not associated with pain except when pressed by hand. No past history of D.M., Pulmonary tuberculosis or any other major chronic illness.

On examination she was moderately built and nourished. Vital were normal except raised temperature in the range of 102°F to 103.8°F. No pallor was present.

There was bilateral cervical lymphadenopathy, multiple {both anterior and posterior cervical and submandibular, approximately 1.5x 2.0 cm in size, rounded to oval, smooth surface, mobile, firm in consistency, few were matted, non tender and overlying skin was normal and free from underlying structure. On systemic examination, respiratory system revealed stony dullness, absent air entry over left infra\_axillary and infrascapular area finding consistent with left pleural effusion. Alimentary system revealed hepatomegaly which was four cm below right costal margin with leafy margin, smooth surface, moved with respiration, nontender with a liver span of 19 cm. There was

moderate splenomegaly which was non-tender. Cardiac and neurological examination were within normal limit.

On laboratory examination: Hb; 12.4mg%, TLC; 7100/cu.mm, DLC; P 76%, L 24%, ESR by Westergreen was 30 mm. in one hour. Malaria parasite was negative by both QBC and peripheral blood-film. IgG and IgM for typhoid fever was negative. Peripheral blood film shows normocytic and normochromic red blood cell, no immature cells and platelets are adequate in number and no hemoparasite seen. Urine analysis was normal. Renal function and liver functions were normal. HIV, Hbs Ag, VDRL, LE Cell, LDH, ANA, anti ds DNA, RA factor, ASOtitre, CRP and T.B IgM and IgG were negative. Blood culture for pyogenic bacteria was negative.

Chest X Ray PA showed pleural effusion on the left side. Pleurocentesis was done. Pleural fluid was yellowish in colour and was exudative type (total protein 3.9 gm%, cell count 900 cells/cu.mm which was predominantly lymphocytic). Pleural fluid AFB culture was negative and ADA level was normal, Gram stain negative and pyogenic culture was sterile.

USG abdomen revealed hepatosplenomegaly. FNAC from cervical lymphadenopathy showed presence of sheets of lymphocytes, macrophages, neutrophils against the background of RBC with no atypical cells suggestive of reactive hyperplasia. Lymph node biopsy was done which on serial section showing patchy area of necrosis with focal collection of neutrophils. Rest of lymph nodes appears normal. Capsules of lymph nodes also did not show any infiltration. This whole biopsy picture is suggestive of KIKUCHI'S disease.

Our case of KIKUCHI'S disease have following manifestation:

1. Moderate to high grade fever with chills and rigor.
2. Cervical and submandibular lymphadenopathy.
3. Left-sided exudative pleural effusion.

Patient was treated conservatively. Left sided pleurocentesis was, done and patient was given symptomatic treatment in the form of antipyretics and anxiolytics. Patient was followed over a period of three months. After one and half months of follow-up, patient became afebrile and

there was no lymphadenopathy. Patient became symptom free after three months i.e. afebrile with no lymphadenopathy, gained weight of 5 kilograms and X-Ray chest PA view was normal.

### DISCUSSION:

Kikuchi's disease is generally a self limited disease with a favourable prognosis. In various literatures, the male female ratio is 1:3 and the age is 4-75 years. About lymphadenopathy cervical nodes are affected in about 80% of cases of which posterior cervical nodes are frequently involved (65-70%), lymphadenopathy is isolated to a single location in 83% of cases but multiple chains may be involved. Nodes are usually described as painless or mildly tender usually firm and mobile.

### Various Extranodal Findings:

1. SKIN: The incidence of skin involvement varies from 5-30%. Findings are varied and non specific include maculopapular lesion, morbilliform rash, urticaria and malar rash which may resembles that of SLE. Skin lesion resolves in a few weeks to months.
2. Hepatosplenomegaly is not uncommon.

3. Neurological involvement is rare.

Kikuchi's disease is misdiagnosed as lymphoma, SLE, infectious mononucleosis, sarcoidosis, tuberculosis etc.

### Management of Kikuchi's Disease:

Treatment is generally supportive. NSAIDs may be used to alleviate lymph node tenderness and fever. The use of prednisone has been recommended in severe extranodal or generalized Kikuchi's disease. Indications for corticosteroid use include the following:

- (A) Neurological Involvement: Aseptic meningitis and cerebellar ataxia
- (B) Hepatic Involvement with elevated LDH level
- (C) Severe lupus like syndrome

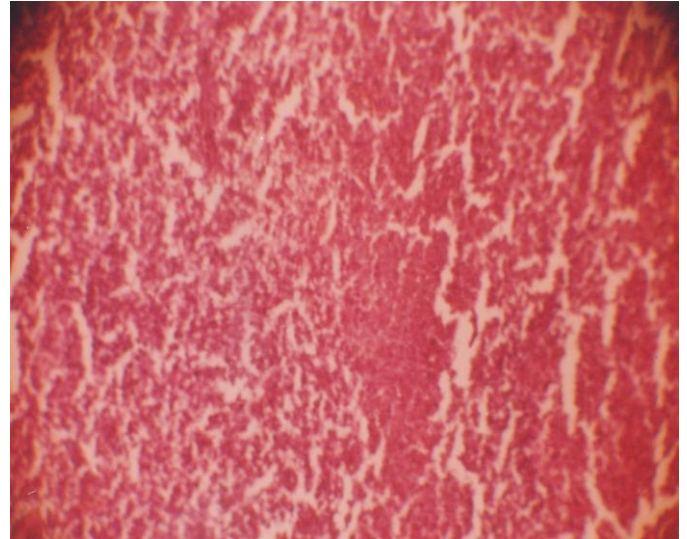
### Conclusion:

We presents a rare case of Kikuchi's disease with unilateral pleural effusion. The occurrence of pleural effusion in Kikuchi's disease is nonreported in literature.

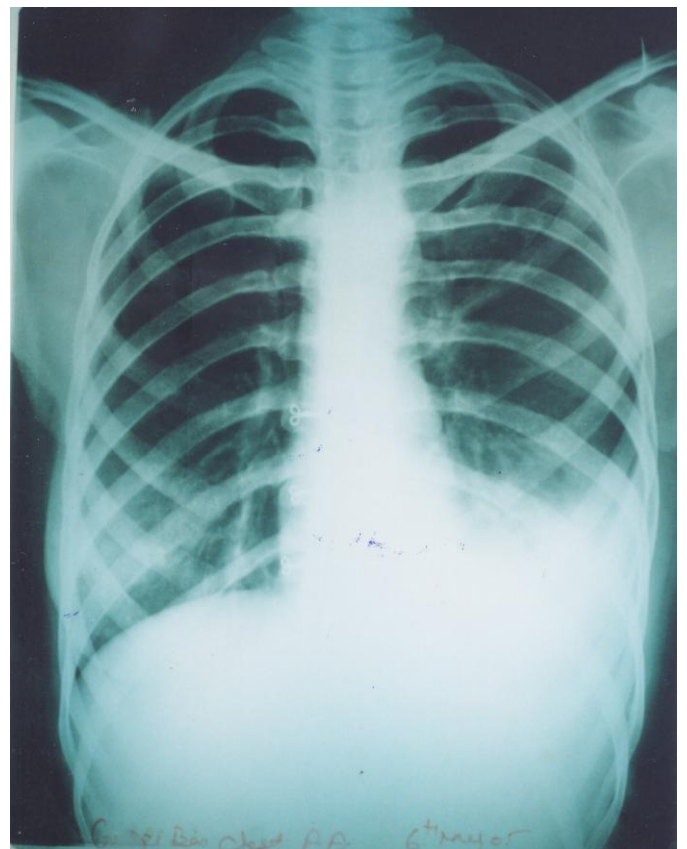
### REFERENCES:

1. Baumgotner BJ, Helling ER. Kikuchi's disease: A case report and review of the

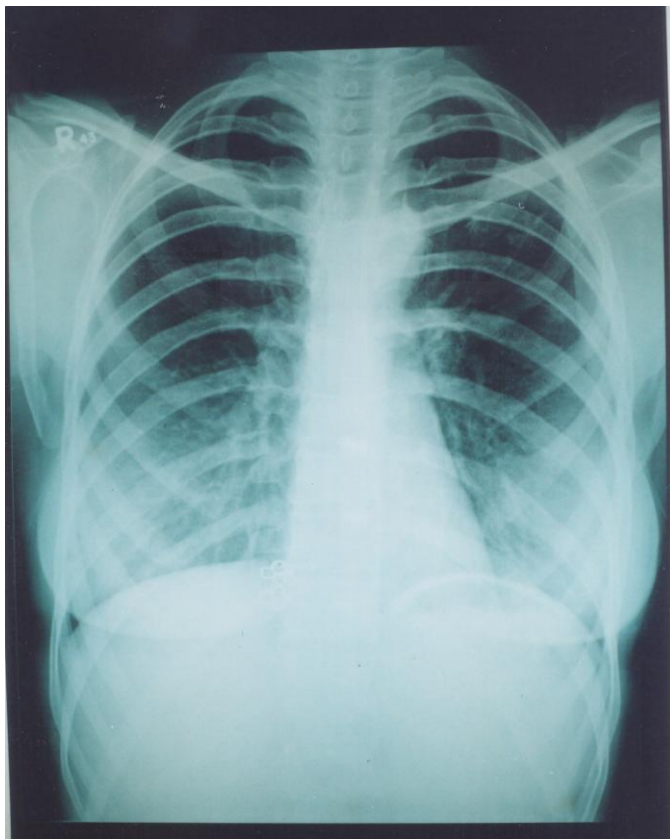
- literature. Ear, Nose, Throat J 2002 May; 81(5):331-335.
2. Bosch X, Guilbest A, Miquel R, et al. Engimetic Kikuchi. Fujimoto disease, a comprehensive review. Am J Clin Pathol 2004 July; 122(1): 141-152.
  3. Jang YJ, Park KH, Seok HJ. Management of Kikuchi's disease using glucocorticoid. J Laryngol Otol 2000 September; 114(9): 709-711.
  4. Soto Y, Kuno H, Oizumi K. Kikuchi's disease with aseptic meningitis, J Neurol SC 1999 March; 163 (2):187-191.
  5. Yasukaw K, Matsumara T, Sato. Matsumara KC, et al. Kikuchi's disease and the skin: case report and review of the literature, British J Dermato 2001 April; 144(4): 885-889.



**Histopathology from FNAC of cervical lymph node**



**CX-Ray PA view before treatment**



**CX-Ray PA view after treatment**