

Research Article

Clinical significance of preoperative thyroglobulin antibody in patients with thyroid malignancy**Begzada Hasukić¹, Amra Jakubović-Čičkušić², Jasminka Alagić-Smailbegović³, Goran Imamović⁴, Šefik Hasukić⁵, Indira Mehmedagić⁶**¹Department of ENT, University Clinical Center Tuzla, Faculty of Medicine, University of Tuzla, Tuzla, Bosnia and Herzegovina²Department of Nuclear Medicine, University Clinical Center Tuzla, Faculty of Medicine, University of Tuzla, Tuzla, Bosnia and Herzegovina³Faculty of Medicine, University of Sarajevo, Sarajevo, Bosnia and Herzegovina⁴Goran Imamović, Faculty of Medicine, University of Tuzla, Tuzla, Bosnia and Herzegovina⁵Department of Surgery, University Clinical Center Tuzla, Faculty of Medicine, University of Tuzla, Tuzla, Bosnia and Herzegovina.⁶Department of Surgery, University Clinical Center Tuzla, Faculty of Medicine, University of Tuzla, Tuzla, Bosnia and Herzegovina.**Abstract:**

It has been reported in recent years that elevated thyroglobulin antibody (TgAb) values can be associated with thyroid malignancy. The aim of this study is to determine whether serum TgAb have a predictive role in thyroid cancer in patients with thyroid nodules. The crossed study included 100 patients with scintigraphic cold thyroid nodules divided in two groups. Demographic data, TgAb levels and final histopathological findings were recorded. The first group consisted of 50 patients with histopathological verified malignant nodules and the second group of 50 patients with histopathological verified benign nodules. TgAb were estimated by the radio-immunity assay (RIA) method. The median of TgAb in the group with benign nodules were 14.3 (10-32) IU / mL and in the group with malignant nodules 42.9 (13-156) IU / mL. TgAb values were significantly higher in patients with malignant nodules ($p = 0.02$). The increase in values of TgAb by 1 IU / mL increased the risk for malignancy by 0.7%. The cut-off for TgAb of > 35 IU / mL discriminates between diagnosis of the malignant and benign thyroid nodule. TgAb of > 35 IU / mL, with a sensitivity of 56% and a specificity of 78%, was found to be a limit value for predicting malignant thyroid lesion. TgAb serum values were predictor of malignant thyroid lesion and their preoperative measurement in combination with other risk factors could assist in preoperative diagnosis in patients with cytological indeterminate thyroid nodules.

Keywords: thyroid gland, thyroglobulin antibody, thyroid cancer, prediction**INTRODUCTION**

Nodules in the thyroid gland represent clinically recognizable increase in thyroid gland with one or more structural and / or functional changes of one or more zones in the normal tissue of the gland (1). The risk of malignancy in the thyroid nodules is 5% to 10% in countries with sufficient iodine intake (2,3). Only a small number of nodules requires surgical treatment and those are nodules that compress the airway or nodules that have a high risk of malignancy.

In the evaluation of the nodose thyroid disease, it is most important to differentiate a disease that is treated medically from a disease that requires a surgical treatment. Various diagnostic methods (thyroid ultrasonography, scintigraphy, fine needle aspiration biopsy-FNAB) are used in preoperative differentiation between malignant and benign lesions. However, none of the aforementioned diagnostic methods has 100% accuracy (4,5). Fine needle aspiration biopsy (FNAB)

is the most important method for evaluating thyroid nodes because of high diagnostic reliability and low risk of complications. The introduction of this method reduced the number of unnecessary surgeries of the thyroid gland (5,6). Although this method is gold standard in the examination of thyroid nodal disease, there are still difficulties in distinguishing between adenomatoid nodules, follicular adenomas, well-differentiated follicular carcinoma, and follicular variants of papillary carcinoma. Due to the nature of the same method, the fine needle biopsy of the thyroid gland can not distinguish between follicular carcinoma and follicular adenoma. They differ in each other by tumor invasion of the capsule (7,8).

Recently, some studies investigated the role of TgAb in preoperative prediction of malignant thyroid nodules. Several studies have shown the association of elevated serum TgAb

values with well-differentiated thyroid carcinoma (WDTC) suggesting that the measurement of preoperative values of TgAb could be used in the prediction of malignant thyroid disease in combination with other diagnostic methods and clinical indicators (9, 10, 11).

The aim of our study was also to determine whether TgAb can be a pre-surgical predictor of the malignant thyroid disease.

Patients and methods

Our study had a prospective clinical study design. It lasted from August 2010 to March 2012 and included 100 patients with scintigraphic cold nodule who underwent lobectomy or total thyroidectomy at the Department for Ear, Nose and Throat (ENT) Disease of the University Clinical Center in Tuzla. The study was approved by the Bioethics Committee of the University Clinical Center Tuzla. All patients met the inclusion criteria and granted their informed consent for the participation in the trial.

Patients included in the study were both sexes divided into two groups based on final histopathological report. The first group consisted of 50 patients with final histopathology reports of malignant nodules. The second group consisted of 50 patients with final histopathological reports of benign nodules. The subjects of this study were patients who had preoperative history of disease, clinical examination, thyroid hormone finding and serum TSH, thyroid ultrasonography, FNAB, TgAb, a scintigraphic finding of a cold node (solitary or multiple) and which had a orderly functional state of the thyroid gland. The study excluded: patients with scintigraphic warm and hot nodules, patients with functional thyroid gland disorders and those who did not have complete medical documentation.

The following data were analyzed: age, sex, scintigraphic findings of cold nodules, serum TgAb values in malignant and in benign thyroid nodules and in separate cytological categories. The surgical specimens were analyzed at the Department of Pathology of University Clinical Center Tuzla. The histopathological analysis was done according to the World Health Organisation Classification of Thyroid Tumors. TgAb were estimated by the radio-immunity assay (RIA). The reference values of TgAb at the laboratory of Department of Nuclear Medicine- University Clinical Center Tuzla, were TgAb<60 IU / mL.

Indications for the surgery of benign thyroid lesions included the size of nodules (due to compressive syndrome) or retrosternal node extension as well as cosmetic reasons (at the patient's request). A conventional method and the operation with an ultrasonic blade were applied.

For statistical data processing for comparison of continuous variables, the T test of independent samples was used, or the Mann-Whitney test, depending on the symmetry of the data distribution. Sensitivity, specificity and predictive value were calculated by diagnostic tests. Logistic regression was used to assess the risk for malignant diagnosis. The ROC analysis was used to predict the limit value of the continuous variable for the dichotomous outcome. The data was statistically analyzed using MedCalc Software, Mariakerke, Belgium. P values

<0,05 were considered statistically significant.

Results

The average age of patients was 46 ± 13 years. There were 12 men and 88 women. The mean age in the groups with benign and malignant nodules was 46 ± 12 and 47 ± 15 years (p> 0.05), and the gender distribution was identical, with 6 men and 44 women in both groups (p> 0.05). Of the total number of patients with scintigraphic cold thyroid nodules, 90 had solitary and 10 patients with multiple nodules .

According to the histopathological reports among 50 patient with diagnosis of malignant nodules there were 30 patients with papillary cancer diagnosis, 19 patients with follicular cancer, and 1 patient with medullary thyroid cancer .

The mean values of TgAb in the groups with benign and malignant nodules are shown in Figure 1.

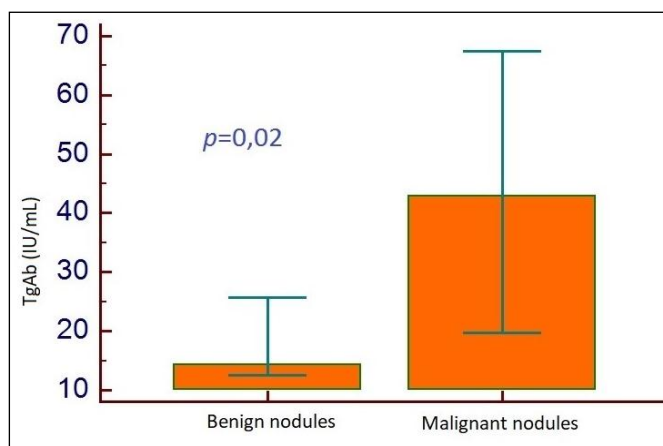


Figure 1. Average values of TgAb in the group with benign (B) and malignant (M) nodules

The mean value of TgAb in the total number of subjects was 21.2 (10-71) IU / mL. The mean values of TgAb in the groups with benign and malignant nodules were 14.3 (10-32) and 42.9 (13-156) IU / mL (Figure 1). TgAb values were significantly higher in patients with malignant nodules than in patients with benign nodules (p = 0.02).

The TgAb value is predictive for malignant nodule diagnosis. The TgAb values of > 35 IU / mL discriminates between diagnosis of the malignant and benign thyroid lesion (Figure 2). Increasing the value by 1 IU / mL increases the risk for malignancy by 0.7% (Table 1).

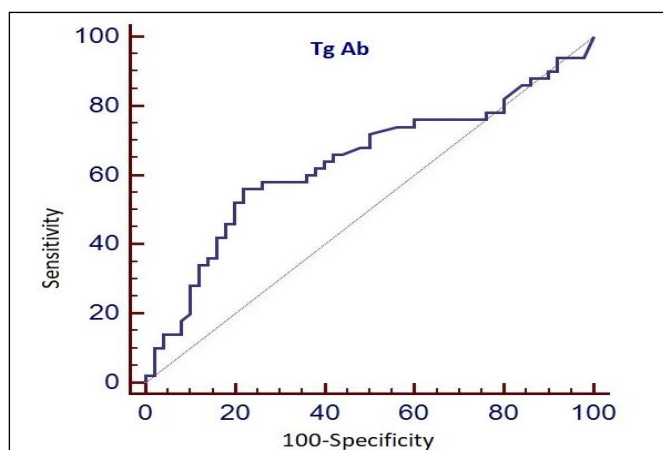


Figure 2. Predictive value of TgAb for thyroid malignant nodule. AUC=0.64; sensitivity 56%, specificity 78% by TgAb >35 IU/mL. (p=0.02).

The predictive values of demographic and diagnostic parameters for malignant nodule diagnosis are shown in Table 1.

Table 1.

Predictive value of demographic and diagnostic parameters for diagnosis of malignant node

Predictors	Units of change	Corrected OR	95% CI	p
Age	1 year	1,007	0,97-1,04	>0,05
Sex	Male Female	0,98 1.0 (ref.)	0,22-4,36	>0,05
Tg	1 ng/mL	1,001	0,99-1,003	>0,05
TgAb	1 IU/mL	1,007	1,0008-1,01	0,02
Scintigraphy	Multiple Solitary	0,26 1.0 (ref.)	0,05-1,29	>0,05

Discussion

TgAb values in patients with malignant thyroid lesions were significantly higher in comparison to a group of patients with benign thyroid lesions (p = 0.02).. The obtained results showed that the TgAb > 35 IU / mL with 56% sensitivity and 78% specificity was a cut-off value in the prediction of thyroid malignancy in our patients. This obtained value discriminated between the diagnosis of malignant and benign thyroid lesion. The increase in TgAb values of 1 IU / mL increased the risk for malignancy for 0.7%.

Lately, some authors report the association of autoimmune thyroiditis and thyroid carcinoma, and reassess the role of TgAb in the presurgery prediction of thyroid malignancy. Kim and al. investigated whether serologic TgAb are predictive of thyroid cancer in patients with thyroid nodules. They obtained that positive TgAb was significantly associated with thyroid cancer and suggest that measurement of presurgery values of TgAb could be used in the prediction of malignant thyroid disease in combination with other diagnostic methods and clinical indicators (9). It was first study that reported that positive serum TgAb test was an independent predictor of malignancy, regardless of the presence of autoimmune thyroiditis. Hosseini and al. received in their study the higher prevalence of well-differentiated thyroid carcinoma (WDTC) in patients with positive TgAb, compared to patients with low/ negative TgAb. They suggest that a TgAb ≥30 IU / ml may be specific for WDTC, although a lower count should not be used to rule out malignancy (10).

Qin et al. examined also the relationship between serological TgAb and WDTC. In their study, the prevalence of elevated serum TgAb and thyroid peroxidase antibodies (TPOAb) was

greater in patients with WDTC than those with benign nodules (11). Boi and al. assessed in their study the association between thyroid autoimmunity and thyroid cancer in a retrospective series of unselected thyroid nodules submitted to FNAB. These authors found a high prevalence of malignant and suspect malignant cytological findings in patients with positive serum anti-thyroid antibody (ATA) compared to patients with negative ATA. A low prevalence of positive ATA were in the cytological finding that they labeled as a benign lesion. Operated patients with histopathological finding of thyroid cancer (most commonly papillary) belonged to a group of subjects with positive ATA. Therefore, these authors recommend further investigation in the light of proving association of thyroid carcinoma and thyroid autoimmunity (12). Pacini and al. reported the presence of TgAb preoperatively in 25% of thyroid cancer patients in 1988 (13).

The results of our study confirm the results of the studies of these authors (9,10,11,12,13). By generally analyzing the results of this study we can conclude that the presurgery determination of serum TgAb in combination with other indicators can significantly contribute to a better estimate when selecting patients for a surgical intervention due to suspected malignant lesions of the thyroid gland. By combining the obtained predictive value of serum TgAb in patients with certain cytological categories, we come closer to a more reliable presurgery diagnosis of malignant thyroid lesions. This is especially important in patients with cytological finding of follicular suspected malignant lesions. It is widely known that the major problem in presurgery diagnosis is the cytological finding of follicular neoplasma. The cytological finding is not able to distinguish the thyroid adenoma from well-differentiated follicular cancer.

Therefore, obtained TgAb value of >35 IU / mL in patients with cytological findings of follicular neoplasma can contribute to greater reliability in presurgery assessment of malignant lesions, especially in patients with other clinical indicators (a hard solitary nodule in the rapidly growing thyroid gland, male gender, older age, ultrasound finding of a hypoechoic nodule without "halo", nodule with microcalcifications, scintigraphic cold nodule).

Conclusion

Serum TgAb values were significantly higher in patients with malignant thyroid lesions than in patients with benign thyroid lesions. Serum TgAb values are predictable for the diagnosis of malignant thyroid lesion. The cut-off for TgAb values of > 35 IU / mL discriminated between the diagnosis of malignant and benign lesions with a specificity of 78% and a sensitivity of 56%. Increasing the value of TgAb by 1 IU/mL increased the risk for malignancy by 0.7%.

References

[1] Radović, B., Tatić, S., Krajnović-Jakšić, E., Han R., 2010 Cytological findings in scintigraphically nonfunctioning thyroid nodules. *Vojnosanitetski pregled* 67 (10):797:801.
 [2] Camargo R, Corigliano S, Friguglietti C, Gauna A, Harach R, Munizaga F and al. *Latin American Thyroid*

- Society recommendations for management of thyroid nodules. *Arq Bras Endocrinol Metab* 2009; 53(9): 1167-1175.
- [3] Harach HR, Ceballos GA. Thyroid cancer, thyroiditis and dietary iodine: a review based on the Salta, Argentina model. *Endocr Pathol.* 2008; 19(4):209-220.
- [4] Castro MR, Gharib H. Thyroid nodules and cancer. When to wait and watch, when to refer. *Postgrad Med.* 2000; 107(1):113-116, 119-120, 123-124.
- [5] Lansford C. Evaluation of Thyroid Nodule. *Carle Selected Paper* 2011; 52 (1):12-22.
- [6] Sidawy MK, Del Vecchio DM, Knoll SM. Fine needle aspiration of thyroid nodules: correlation between cytology and histology and evaluation of discrepant cases. *Cancer* 1997; 81(4):253-259.
- [7] Bomeli SR, LeBeau SO, Ferris RL. Evaluation of a thyroid nodule. *Otolaryngol Clin North Am.* 2010; 43(2):229-238.
- [8] Baloch ZW, LiVolsi VA, Asa SL, Rosai J, Merino MJ, Randolph G, et al. Diagnostic terminology and morphologic criteria for cytologic diagnosis of thyroid lesions: a synopsis of the National Cancer Institute Thyroid Fine-Needle Aspiration State of the Science Conference. *Diagn Cytopathol* 2008; 36(6):425-437.
- [9] Kim-ES, Lim DJ, Baek KH, Lee JM, Kim MK, Kwon HS, Song KH, Kang MI, Cha BY, Lee KW, Son HY. Thyroglobulin antibody is associated with increased cancer risk in thyroid nodules. *Thyroid* 2010; 20(8):885-891.
- [10] Hosseini S, Payne RJ, Zawawi F, et al. Can preoperative thyroglobulin antibody levels be used as a marker for well differentiated thyroid cancer? *Journal of Otolaryngology - Head & Neck Surgery.* 2016; 45:31. doi:10.1186/s40463-016-0143-5.
- [11] Jing Qin, Zhenqian Yu, Haixia Guan, et al., "High Thyroglobulin Antibody Levels Increase the Risk of Differentiated Thyroid Carcinoma," *Disease Markers* 2015, Article ID 648670, 7. doi:10.1155/2015/648670
- [12] Boi F, Lai M L, Marziani B, Minerba L, Faa G, Mariotti S. High prevalence of suspicious cytology in thyroid nodules associated with positive thyroid autoantibodies. *European Journal of Endocrinology* 2005; 153: 637-642.
- [13] Pacini F, Mariotti S, Formica N, Elisei R, Anelli S, Capotorti E & Pinchera A. Thyroid autoantibodies in thyroid cancer: incidence and relationship with tumour outcome. *Acta Endocrinologica (Copenhagen)* 1998; 119:373-380.