

## International Journal Of Medical Science And Clinical Inventions

Volume 2 issue 02 2015 page no. 682-690 ISSN: 2348-991X

Available Online At: <http://valleyinternational.net/index.php/our-jou/ijmsci>

# The Use of Cone Beam Computed Tomography Imaging In Dentistry: A Review

Mobeen Khan<sup>1</sup>, Anjani Kumar Shukla<sup>2</sup>, Md Asad Iqbal<sup>3</sup>, Swetarchi<sup>4</sup>, Moazzam Jawaid<sup>5</sup>

<sup>1,2,3,4,5</sup>Post Graduate Student, Department of Oral medicine and Radiology, Institute of Dental Sciences,  
Bareilly, India.

**Corresponding authors:** Mobeen Khan, Post Graduate Student, Department of Oral medicine and  
Radiology, Institute of Dental Sciences, Bareilly, India.

Email id: drmkhan26@gmail.com

### **ABSTRACT:**

*Radiology is very important in the diagnostic assessment of the maxillofacial pathology and in the maxillofacial trauma. In the past, maxillofacial pathologies were evaluated by conventional radiography or plain radiography. The use of cone beam computed tomography (CBCT) or 3D imaging as an aid in the diagnosis of maxillofacial pathologies and treatment planning of periodontal disorders is well accepted. Radiographs can provide critical information for diagnosis and treatment planning. Radiographs can also serve as baseline information for the assessment of treatment outcomes. CBCT imaging is generally considered to provide complete information for the assessment, diagnosis and management of maxillofacial disorders and maxillofacial trauma and periodontal pathologies.*

**KEYWORDS:** CBCT, maxillofacial pathologies, periodontal pathologies, diagnostic assessment.

### **INTRODUCTION**

Radiology is important in the diagnostic assessment of the dental patient and guidelines for the selection of appropriate radiographic procedures for patients suspected of having dental and maxillofacial disease are available.<sup>1</sup> The American Academy of Oral and Maxillofacial Radiology (AAOMR) has established “parameters of care” providing rationales for image selection for diagnosis, treatment planning and follow-up of patients with conditions affecting the oral

maxillofacial region, including temporomandibular joint (TMJ) dysfunction (Parameter 2), diseases of the jaws (Parameter 3) and dental implant planning (Parameter 4).<sup>2</sup> Although in a number of clinical situations, combinations of plain x-ray transmission projections and panoramic radiography can be adequate. Radiographic assessment may sometime be facilitated by multiplanar images including

computed tomography and cone beam computed tomography.

For most dental clinicians, the use of advanced imaging has been limited because of cost, availability and radiation dose considerations; however, cone-beam computed tomography (CBCT) for the maxillofacial region provides opportunities for dental clinicians to request multiplanar imaging. Most dental clinicians are familiar with the thin-slice images produced in the axial plane by conventional helical fan-beam CT. CBCT allows the creation in “real time” of images in the axial plane, coronal, sagittal and even oblique or curved image planes — a process referred to as multiplanar reformation (MPR). In addition, CBCT data are acquiescent to reformation in a volume, rather than a slice, providing 3-dimensional (3D) information (figure 1).

### **CBCT IMAGE PRODUCTION**

CBCT machines scan patients in sitting or standing positions. Despite patient orientation within the equipment, the principles of image production remain the same. The four components of CBCT image production are as follows:

#### **Acquisition configuration**

Continuous or pulsed x-ray beam and charged couple device detectors moving synchronously around the fixed fulcrum within the patient's head.

#### **Image detection**

It is determined by individual volume elements or voxels produced from the volumetric data set. CBCT units provide voxel resolutions that are isotropic (equal in all 3 dimensions).

#### **Image reconstruction**

The processing of acquired projection frames to the volumetric dataset is done on the personal computer which is called as reconstruction.

#### **Image display**

The compilation of all available voxels is presented to the clinician on the computer screen as secondary reconstructed images in three orthogonal planes.<sup>3</sup>

### **AS A DIAGNOSTIC AID IN ORAL AND MAXILLOFACIAL RADIOLOGY**

A combination of low radiation dose, high quality bony definition, and compact design requiring minimum space has made CBCT desirable as an in-office imaging system for examination of the pathology in the head and neck, extra-cranial, paranasal, and temporal bone region. Examination of fractured teeth and bone seem to be a logical application of CBCT. Evaluation of post-surgical complications such as losing screws or broken mandibular fracture fixation can be achieved with CBCT due to the low level metal artifact.<sup>4</sup>

CBCT is recommended for diagnosis of a cyst, tumor (figure 2) or infections in alveolar process and jaw bone<sup>5</sup>. Many unusual and rare calcifying lesions such as Calcifying Cystic Odontogenic Tumor (CCOT) can be examined in CBCT images for their particular variations. CBCT is very useful for evaluation of intra-osseous lesions that are in close proximity to vital organs and vasculature in the head and neck region<sup>5</sup>. Although the reliability of CBCT in detecting the invasion or erosion of oral malignancy such as Oral Squamous Cell Carcinoma (OSCC) is still under investigation, study has suggested that combination of Dynamic Contrast Enhanced (DCE)-Magnetic Resonance Image (MRI) and CBCT may be a useful tool to

delineate tumor boundary and develop appropriate surgical intervention.<sup>6</sup>

Studies have shown that CBCT images enable the surgeon to produce a more conservative treatment approach, which reduces iatrogenic damages and is more acceptable to the patients.<sup>7,8</sup> Researchers have made big strides to translate computer-assisted virtual treatment planning to actual clinical practices for orthognathic surgeries. Once being fully developed, CBCT and the 3D virtual software will become an excellent clinical tool for treatment planning of oral & maxillofacial deformities.<sup>9,10</sup>

It would be safe to say that the application of CBCT for craniofacial pathology and surgery is in its infancy stage. Much more evidenced-based studies are needed to validate the role of CBCT in oral and maxillofacial pathology and surgery.<sup>11</sup>

### ORAL AND MAXILLOFACIAL SURGERY

Conventional CT is used routinely in the diagnosis of maxillofacial pathology. Given the higher resolution, lower radiation dose, and lower cost of CBCT in imaging the maxillofacial region, it stands to reason that CBCT can easily replace conventional CT in this regard. Three dimensional imaging of the maxillofacial pathology can give the vital information to oral and maxillofacial surgeon necessary for planning surgery. CBCT data also can be useful in creating a stereolithic model of the area of interest.<sup>12</sup>

The diagnosis and treatment planning of temporomandibular joint (figure3) disorders often are quite challenging. The imaging offered by current CBCT machines has been shown to provide a complete radiographic evaluation of the bony components of the TMJ. The resulting images are of high diagnostic quality. CBCT may

soon become the investigational tool of choice for evaluating bony changes of the TMJ.<sup>13</sup>

Treatment planning for patients with cleft lip and palate entails many unique considerations. CBCT should allow better evaluation of dental age, arch segment positioning, and cleft size compared with traditional radiography. Volumetric analysis promises to offer better prediction in terms of the morphology of the defect, as well as the volume of graft material necessary for repair. Questions abound regarding the stability of the arch after grafting, the quality of the bone graft over time, and the effect on overall facial growth; CBCT provides a means to investigate these issues in depth.<sup>12</sup>

Dental professionals have evaluated the significance of CBCT imaging in orthognathic surgery, regarding the correlation between soft tissue and hard tissue changes.

The identification, treatment planning, and evaluation of potential postoperative complications of impacted teeth are greatly improved by adding the 3D image through CBCT. The relationship of impacted third molars to the mandibular canal, adjacent teeth, sinus walls, and cortical borders is an important diagnostic information that can directly impact the outcome of surgery.<sup>14</sup>

Using CBCT to locate and evaluate impacted cuspids and supernumerary teeth seem to make the surgical procedure more efficient and less invasive.<sup>15</sup> Because the anatomic structures adjacent to the region of interest can be seen in 3 dimensions, this additional information may reduce the morbidity and potential complications during surgery, contributing to a better outcome.<sup>12</sup>

Dentoalveolar fracture, maxillary bone fracture, zygomatic complex fracture, mandibular fracture,

or gunshot injuries require radiographs for precise location of the fracture. Panoramic radiographs and numerous extra oral radiographs are routinely used in maxillofacial trauma cases. Additionally, CBCT is more sensitive and accurate in imaging the maxilla and mandible. It is reported that mandibular fractures that are not evident in conventional CT can be identified using CBCT. Also, when using CBCT, as compared to CT and conventional radiograph, information about dentoalveolar fractures is more detailed. This makes CBCT uniquely useful in the diagnosis of alveolar fractures.<sup>16-18</sup>

### DENTAL IMPLANT

Clinical examination and conventional radiographs may be adequate for patients with wide residual ridges that exhibit sufficient bone crestal to the mandibular nerve and maxillary sinus. These methods do not allow for precise measurement of the bucco-lingual dimension of the bone or assessment of the location of unanticipated undercuts. For these concerns, it is necessary to view the recipient site in a plane perpendicular to a curved plane through the arch of the maxilla or mandible in the region of the proposed implants. Cross-sectional views of the maxilla and mandible are the ideal means of providing necessary pre-operative information. In simple cases, where a limited number of implants are to be placed, panoramic radiography may be used to obtain a view of the arch of the jaw in the area of interest. For complex cases, where multiple implants are required, the CBCT scan is recommended. A CBCT is also ideal when working with severely resorbed maxilla and the mandible. Depending upon the pattern of resorption the anatomical landmarks might pose a risk to placement of dental implants. Use of a CBCT, because of its ability to reconstruct a fully three dimensional model of the maxilla and

mandible, will help identify critical anatomic structures accurately for precise placement of dental implants with minimal complications.<sup>19</sup>

### ORTHODONTICS

The applications of CBCT in orthodontics include assessment of palatal bone thickness, skeletal growth pattern, severity of tooth impaction, and upper airway evaluation.<sup>4, 20, 21</sup> CBCT is helpful in treatment planning of orthodontic cases which need buccal tooth movement and arch expansion.<sup>22, 23</sup>

The synthesized cephalometric image can be used to delineate ambiguous visual landmarks such as porion, and avoid measurement inaccuracy occurred on conventional cephalogram. Cephalometric reconstruction can be used as an alternative to conventional cephalograms when a CBCT volume is already available, so as to reduce additional radiation exposure and extra examination cost.<sup>24, 25</sup>

Using CBCT hard and soft tissue segmentation along with photographic superimposition, orthodontists and other related specialists are able to simulate virtual patient and interact directly with the disease model, which improves the therapeutic outcomes in many clinical sceneries.<sup>24</sup>

Although CBCT has become more popular in orthodontics, further studies are needed to determine if it should be routinely ordered for orthodontic cases, especially because majority of the patients are young and the radiation dose associated with CBCT is much higher than the traditional plain film radiograph.<sup>11</sup>

### ENDODONTICS

CBCT is a useful diagnostic tool for the diagnosis of periapical pathology. A few research studies

have shown that contrast-enhanced CBCT images can be used to differentiate between apical granulomas and apical cysts by measuring the lesion density. Another article describes the use of CBCT as a tool to categorize the origin of the lesion as endodontic or non-endodontic. The superiority of CBCT in detecting fractured roots compared to 2D radiographs has been demonstrated by several clinical case reports focused on detecting vertical root fractures<sup>26</sup>. CBCT is considered superior to periapical radiographs in the detection of fractures in buccolingual or mesiodistal directions, in the measurement of depth in dentin and in the detection of horizontal root fractures.<sup>26,27</sup> CBCT is able to detect lesions in cases of inflammatory root resorption, whereas conventional 2D x-rays cannot detect them in early stages. In other cases such as external root resorption, external cervical resorption and internal resorption, CBCT cannot only detect the presence of resorption but also its extent. CBCT can be used to determine root morphology; to measure the number of roots, canals (figure4), and accessory canals; and to establish their working lengths and angulations. CBCT also provides accuracy in the assessment of root canal fillings in the detection of pulpal extensions in talon cusps and in the detection of the position of fractured instruments. CBCT is a reliable tool for the presurgical assessment of the proximity of the tooth to adjacent vital structures, the size and extent of a lesion, and the anatomy and morphology of roots through very accurate measurements.<sup>28</sup> In emergency cases requiring tooth assessment after trauma, CBCT applications can aid in reaching a proper diagnosis to determine the most suitable treatment approach. When ordering CBCT to evaluate a suspicious periapical lesion, or already failed root canal therapy, it is important to select the correct parameters, such as small volume and a voxel size

of 0.125 mm, to achieve a diagnostic quality image.<sup>11</sup> Due to its reliability and accuracy, CBCT has recently been used to evaluate canal preparation in different instrumentation techniques.

## PERIODONTICS

Conventional (2D) intraoral radiography is the most common imaging modality used for diagnosing bone morphology, such as periodontal bone defects. However, the limitations of conventional radiography could cause dentists to underestimate the amount of bone loss or available bone due to projection errors and has led to errors in identifying reliable anatomical reference points.<sup>29</sup> 2D radiographs are inadequate for detecting changes in bone level or determining the architecture of osseous defects.<sup>30</sup> CBCT provides accurate measurement of intrabony defects and allows clinicians to assess dehiscence, fenestration defects, and periodontal cysts. While CBCT and 2D radiographs are comparable in terms of revealing interproximal defects, only 3D imaging such as CBCT can visualize buccal and lingual defects.<sup>30</sup>

CBCT has been used to obtain detailed morphologic descriptions of bone as accurately as direct measurement with a periodontal probe. CBCT can also be used to assess furcation involvement of periodontal defects and allow clinicians to evaluate postsurgical results of regenerative periodontal therapy.<sup>31</sup>

## CBCT IN FORENSIC DENTISTRY

In forensic dentistry age estimation is an important aspect. It is imperative that clinicians are able to estimate the age of the individuals placed in the legal system (and those who are deceased) as accurately as possible. A lot of criminal acts are committed by individuals

pretending to be beneath the age of majority. Verification of chronological age is required in order to be entitled to a guardian and social benefit.<sup>32</sup> Enamel is largely immune from such changes beyond normal wear and tear; however, the pulpodentinal complex (dentin, cementum, and the dental pulp) shows physiologic and pathological changes with advancing age. Typically, extraction and sectioning are required to quantify these morphological changes, which is not always a viable option. CBCT, however, provides a non-invasive alternative.<sup>32</sup>

### ADVANTAGES

Being considerably smaller, CBCT equipment has a greatly reduced physical footprint and is approximately 20-25% of the cost of conventional CT. CBCT provides images of high contrasting structures and is therefore particularly well-suited towards the imaging of osseous structures of the craniofacial area. The use of CBCT technology in clinical dental practice provides a number of advantages for maxillofacial imaging.<sup>33</sup> These include:

- a. Rapid scan time.
- b. Image accuracy.
- c. Reduced patient radiation dose compared to conventional CT.
- d. Interactive display modes unique to maxillofacial imaging.

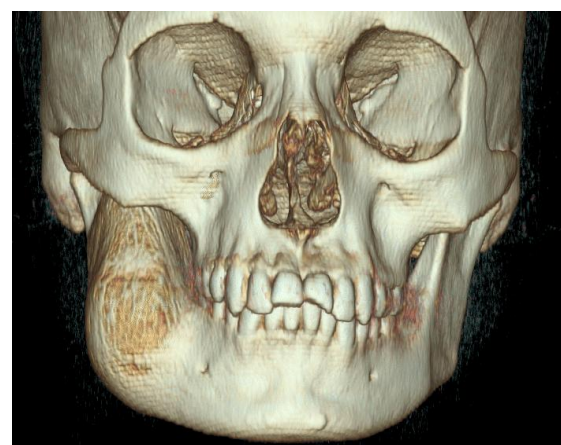
### LIMITATIONS OF CBCT

Metal crowns or any other metal elements in the mouth cause many artifacts during the acquisition of the three-dimensional image due to the absorption of the X-ray beam. The nature of the metal leads to great variations in the quality of the image. In endodontics, it is common to examine

teeth with posts and prosthetic restorations. Artifacts produced by metals limit the image reading. Sometimes interpretation even becomes impossible. Currently, Planmeca is the first to adopt image processing software for their cone-beam promax, which minimizes the effect of metallic artifacts.<sup>34</sup>

### CONCLUSION

Two-dimensional diagnostic imaging has served dentistry well and will continue to do so for the anticipated future. On the other hand, CBCT allows complete visualization of the oral and maxillofacial region. CBCT technology aids in the diagnosis of periapical pathosis and endodontic pathosis. CBCT has increased accuracy, higher resolution, and reduced scan time. CBCT has led to reduction in radiation dose in comparison with CT. CBCT eliminates superimposition of surrounding structures. The development and rapid commercialization of CBCT technology dedicated for imaging the maxillofacial region will certainly increase dental practitioner access to 3D radiographic assessments in clinical dental practice.



**Figure 1:** 3D reconstruction shows expansion.

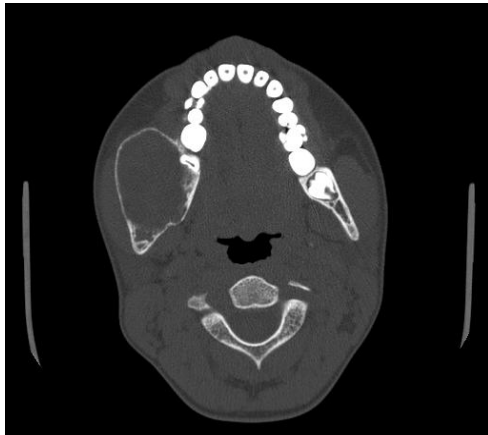

Figure 2: cone beam CT axial view shows bicortical expansile lesion on right side of mandible.

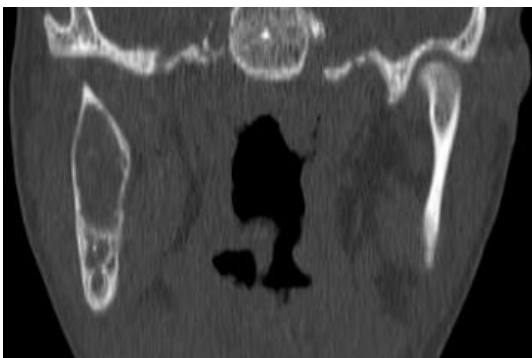


Figure 3: CBCT coronal view shows morphological alteration on right side of the tmj in comparison to left side

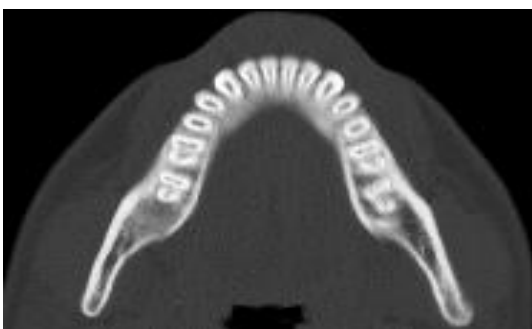


Figure 4: CBCT axial image shows number of pulp canal in the mandibular teeth.

1. American Dental Association and U.S. Department of Health and Human Services. The selection of patients for dental radiographic examinations. Chicago: American Dental Association, 2004.

2. White SC, Heslop EW, Hollender LG, Mosier KM, Ruprecht A, Shroot MK; American Academy of Oral and Maxillofacial Radiology, ad hoc Committee on Parameters of Care. Parameters of radiologic care: an official report of the American Academy of Oral and Maxillofacial Radiology. *Oral Surg Oral Med Oral Pathol Oral Radiol Endod* 2001; 91(5):498–511.

3. Ranjana Mohan, Archana Singh, and Mohan Gundappa. Three-dimensional imaging in periodontal diagnosis – Utilization of cone beam computed tomography. *J Indian Soc Periodontol*. 2011; 15(1): 11–17.

4. Miracle AC, Mukherji SK. Cone beam CT of the Head and Neck, Part 2: Clinical Applications. *Am J Neuroradiol* 2009;30: 1285-1292.

5. Marques YM, Botelho TD, Xavier FC, Rangel AL, Rege IC, et al. Importance of cone beam computed tomography for diagnosis of calcifying cystic odontogenic tumour associated to odontoma. Report of a case. *Med Oral Patol Oral Cir Bucal* 2010;15: 490-493.

6. Hendrikx AW, Maal T, Dieleman F, Van Cann EM, Merckx MA. Cone-beam CT in the assessment of mandibular invasion by oral squamous cell carcinoma: results of the preliminary study. *Int J Oral Maxillofac Surg* 2010; 39: 436-439.

7. Bortoluzzi MC, Manfro R. Treatment for ectopic third molar in the subcondylar region planned with cone beam computed tomography: a

## References

case report. *J Oral Maxillofac Surg* 2010; 68: 870-872.

8. Szucs A, Bujtár P, Sándor GK, Barabás J. Finite element analysis of the human mandible to assess the effect of removing an impacted third molar. *J Can Dent Assoc* 2010; 76: 72.

9. Edwards SP Computer-assisted craniomaxillofacial surgery. *Oral Maxillofac Surg Clin North Am* 2010;22: 117-134.

10. Swennen GR, Mollemans W, Schutyser F. Three-dimensional treatment planning of orthognathic surgery in the era of virtual imaging. *J Oral Maxillofac Surg.* 2009; 67: 2080-2092.

11. Adibi S, Zhang W, Servos T, O'Neill P (2012) Cone Beam Computed Tomography for General Dentists. 1;(11):519. doi:10.4172/scientificreports.519.

12. Faisal A. Quereshy, Truitt A. Savell, and J. Martin Palomo. Applications of Cone Beam Computed Tomography in the Practice of Oral and Maxillofacial Surgery. *J Oral Maxillofac Surg.* 2008; 66:791-796.

13. Tsiklakis K, Syriopoulos K, Stamatakis HC: Radiographic examination of the temporomandibular joint using cone beam computed tomography. *Dentomaxillofac Radiol.* 2004; 33:196.

14. Danforth RA, Peck J, Hall P: Cone beam volume tomography: An imaging option for diagnosis of complex mandibular third molar anatomical relationships. *J Calif Dent Assoc.* 2003;31:847.

15. Walker L, Enciso R, Mah, J: Three-dimensional localization of maxillary canines with cone-beam computed tomography. *Am J Orthod Dentofac Orthop.* 2005; 128:418.

16. Palomo L, Palomo JM. Cone beam CT for diagnosis and treatment planning in trauma cases. *Dent Clin North Am.* 2009;53(4):717-727.

17. Heiland M, Schulze D, Rother U, Schmelzle R. Postoperative imaging of zygomaticomaxillary complex fractures using digital volume tomography. *J Oral Maxillofac Surg.* 2004;62(11):1387-1391.

18. Mischkowski RA, Zinser MJ, Ritter L, Neugebauer J, Keeve E, Zöller JE. Intraoperative navigation in the maxillofacial area based on 3D imaging obtained by a cone-beam device. *Int J Oral Maxillofac Surg.* 2007;36(8):687-694.

19. Vandana Kumar. Applications of Cone Beam Computed Tomography (CBCT) in Implant Treatment Planning. *JSM Dent.* 2013; 1(2): 1008.

20. Kim YJ, Hong JS, Hwang YI, Park YH. Three-dimensional analysis of pharyngeal airway in preadolescent children with different anteroposterior skeletal patterns. *Am J Orthod Dentofacial Orthop.* 2010; 137: 306.

21. Nurko C. Three-dimensional imaging cone beam computer tomography technology: an update and case report of an impacted incisor in a mixed dentition patient. *Pediatr Dent.* 2010; 32: 356-360.

22. Chenin DL. 3D cephalometrics: the new norm. *Alpha Omegan.* 2010: 103: 51- 56.

23. Evangelista K, Vasconcelos Kde F, Bumann A, Hirsch E, Nitka M, et al. Dehiscence and fenestration in patients with Class I and Class II Division 1 malocclusion assessed with cone-beam computed tomography. *Am J Orthod Dentofacial Orthop.* 2010; 138: 133.

24. Grauer D, Cevitanes LS, Proffit WR. Working with DICOM craniofacial images. *Am J Orthod Dentofacial Orthop.* 2009; 136: 460-470.



25. Kumar V, Ludlow J, Soares Cevidanes LH, Mol A. In Vivo Comparison of Conventional and Cone Beam CT Synthesized Cephalograms. *Angle Orthod.*2008; 78: 873-879.
26. Cotton TP, Geisler TM, Holden DT, Schwartz SA, Schindler WG. Endodontic applications of cone-beam volumetric tomography. *J Endod.* 2007 ;33(9):1121- 32.
27. Hassan B, Metska ME, Ozok AR, van der Stelt P, Wesselink PR. Comparison of five cone beam computed tomography systems for the detection of vertical root fractures. *J Endod.* 2010;36(1):126-9.
28. de Paula-Silva FW, Wu MK, Leonardo MR, da Silva LA, Wesselink PR. Accuracy of periapical radiography and cone-beam computed tomography scans in diagnosing apical periodontitis using histopathological findings as a gold standard. *J Endod.* 2009 ;35(7):1009-12.
29. Vandenberghe B, Jacobs R, Yang J. Diagnostic validity (or acuity) of 2D CCD versus 3D CBCT images for assessing periodontal breakdown. *Oral Surg Oral Med Oral Pathol Oral Radiol Endod* 2007;104(3):395-401.
30. Misch KA, Yi ES, Sarment DP. Accuracy of cone beam computed tomography for periodontal defect measurements. *J Periodontol* 2006;77(7): 1261-1266.
31. Ito K, Yoshinuma N, Goke E, Arai Y, Shinoda K. Clinical application of a new compact computed tomography system for evaluating the outcome of regenerative therapy: A case report. *J Periodontol* 2001;72(5):696-702.
32. Yang F, Jacobs R, Willems G. Dental age estimation through volume matching of teeth imaged by cone-beam CT. *Forensic Sci Int* 2006;159 Suppl 1:S78-S83.
33. William C. Scarfe, Allan G. Farman, Cone beam computed tomography: A paradigm shift for clinical dentistry. *Australasian Dental Practice.*2007; 102-108.
34. S Manoj Kumar, PE Chandra Mouli, S Kailasam, PH Raghuram, S Sateesh, Karpagavalli Applications of Cone-Beam Computed Tomography in Dentistry *Journal of Indian Academy of Oral Medicine and Radiology,* October-December 2011;23(4):593-597