

## Case Report,

# Scleral Dellen: Early Complication of Pterygium Surgery and Literature Review.

Hatim Boui<sup>1</sup>, Yassine Mouzari<sup>2</sup>, Fouad Al Asri<sup>3</sup>, Karim Reda<sup>4</sup>, Abdelbarre Oubaaz<sup>5</sup>

<sup>1, 2,3,4,5</sup> Department Of Ophthalmology, Military Training Hospital Med-V, Rabat, Morocco

### Introduction:

The pterygium is a fibro-vascular, triangular neof ormation. It typically starts on the cornea in the area of the palpebral fissure, especially on the nasal side. The vision is compromised by its invasive and progressive nature [1]. Actually, the treatment is primarily symptomatic, using lubricants and anti-inflammatory agent. However radical treatment of pterygium is purely surgical. The recurrence of the lesion is the main surgical complication. Several surgical procedures are available to treat the pterygium, such as simple excision with sclera exposure, conjunctival closure, sliding conjunctival flaps and conjunctival autografts [2]. Furthermore, adjuvant therapy may also be used like; the cryotherapy, the contact radiotherapy, beta radiations or alternatively mitomycin C, to reduce the risk of recurrence. Severe Scleral Dellen is a rare and early postoperative complication of pterygium surgery [2]. The various cases reported in the literature are mostly related to this surgical technique; simple excision of the conjunctiva, notably either without adjuvant treatment or using mitomycine C in preoperative [5, 6] or otherwise beta radiation. [7] In one case of the literature we find a scleral Dellen associated with pterygium excision then a simple conjunctival closure after minimal cauterization of the episcleral blood vessels. [2] The particularity of our case is that the scleral Dellen is associated with excision and simple suture of the conjunctiva without adjuvant treatment or cauterization of the vessels. The other particularity of this case is that it is to our knowledge the first case of scleral dellen reported in Morocco, and even at the African level.

### Case report:

This case is a 38-year-old military patient with no medical history

He was referred for primary pterygium located on the nasal side of the right eye the patient was scheduled for pterygium surgery. About the operating procedure, the anesthesia was a topical one, based on Oxybuprocaine 0, 4% subsequently we performed a simple excision of pterygium with conjunctival suture by stitches (silk 8/0), without any extra treatment intraoperatively and without cauterization. At the end of the procedure we applied eye drops containing Dexamethasone (1 mg/ml), Neomycin (3,500 IU/ml) and Polymyxin B (6,000 IU/ml) and we added ointment with Dexamethasone (1 mg/g), Neomycin (3,500 IU/g) and Polymyxine B (6,000 IU/g). Then we performed an occlusion with an eye dressing, the day after the surgery the control was satisfying. Then we prescribed topical corticosteroids in addition to antibiotics and artificial tears. 16 days later, the patient came back after noticing the appearance of a blackish brown spot at the nasal side of the right eye associated with mild eye pain. The examination then regained a corrected visual acuity of 10/10 in both eyes, an intraocular pressure of 16 mmHg in the right eye and 15 mmHg in the left eye.

The slit lamp examination of the involved eye revealed a severe scleral thinning, surrounded by an oedematous conjunctiva and the visualization of the ciliary body through the fine sclera. The conjunctival sutures were no longer in place. Talking about the scleral lesion, it was blackish brown, located at 1.25 mm from the limb in the nasal side; measuring 1.25 mm wide and 1.75 mm

high (figure 1) Moreover, the anterior chamber was optically empty and had normal depth, the iris had normal color and trophicity.

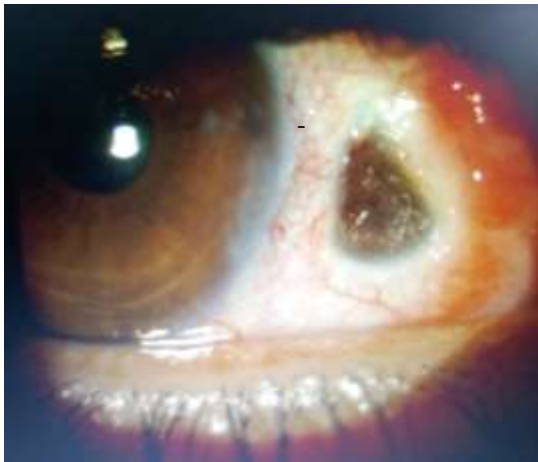


Figure 1: the initial appearance of scleral Dellen

The light reflex was also preserved. Furthermore the examination of the eye was without any abnormality Our conduct has consisted of the hospitalization of the patient then the administration of a local antibiotherapy and artificial tears abundantly (hourly drop) then occlusion by eye dressing in the same way that a daily surveillance of the lesion evolution. An eye covering had been discussed, but we opted for a sunset. After three days, we observed a scleral cicatrization, followed by a gradual covering of the sclera by conjunctiva. Seven days later a conjunctival bud appeared. Its excision had been carried out only two after the second week. The pictures below show the evolution of the patient. (Figure 2)

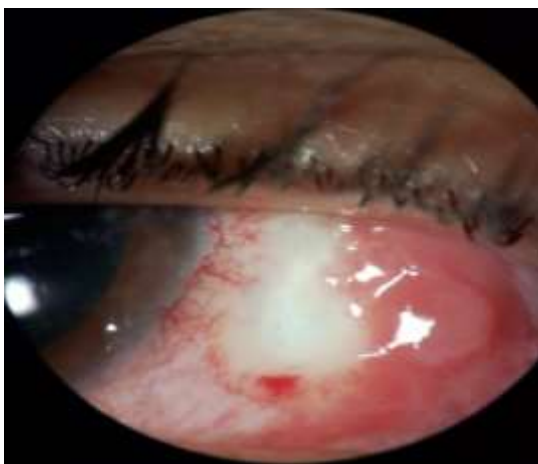

Figure 2: the evolution of scleral Dellen day 3

After the patient improvement, we referred him to an internist doctor for more investigations in the light of searching other underlying pathology. The physical examination and the laboratory tests (blood count, biochemistry, rheumatoid factor, auto antibodies testing and infectious serology) showed no infectious nor autoimmune or inflammatory disease.

### Discussion:

Several surgical techniques can be performed to treat a pterygium. The techniques related to a scleral Dellen occurrence are either simple excision with bare sclera [3,4,5,6,7] or scleral excision with simple conjunctival suture [2], as the case we report here. In the first cases exposing the sclera would promote its dryness and would therefore be a risk factor of scleral thinning. However in our case as in that described by Garcia-Medina and collaborators, we performed a conjunctival suture with two stitches to cover the sclera. Otherwise, both of the stitches were not found later, which suggests that, like in the Garcia-Medina report; a bad handling by the patient (eye rubbing), loose stitches or even both. [2] Thus, the sclera would have been exposed in the two cases. According to Chen and Noonan this exposed sclera with accumulation of granulation is at the origin of the Dellen effect. [3] Cauterization of the episcleral blood vessels and in particular the limbus vessels are used to reduce the risk of pterygium recurrence after surgery [8], but in some cases it is only used to prevent bleeding during surgery [2]. According to Garcia-Medina, this cauterization could be an element favoring the occurrence of scleral Dellen, as it can cause local ischemia [2]. In our case the cauterization was not carried out. Mitomycin C is an antibiotic, an anti-neoplastic agent that selectively inhibits DNA synthesis, cell division and protein division. The mechanism of its action appears to be the inhibition of the fibroblasts proliferation at the episclera level. [9]

Scleral ulceration is described in cases of pterygium surgery using Mitomycin C, in a proportion varying from 5 to 19% [10]. The use of Mitomycin C to prevent pterygium recurrence may play a role in the development of scleral Dellen. However, the use of Mitomycin C as an adjuvant to pterygium surgery, was only carried out in two studies [5,6] of all those reporting the occurrence of Dellen scleral as a complication of pterygium surgery. Thus, Mitomycin C could play a

promoting role, but which must be minimized compared to the other possible factors similarly, beta radiations have only been reported as an adjunct treatment to pterygium surgery in a single article [7]. This could minimize its role as a factor favoring the occurrence of scleral Dellen Subconjunctival anesthesia containing a vasoconstrictor (epinephrine) has also been suspected as a risk factor of scleral Dellen after pterygium surgery [2]. As it may be a contributing factor to local ischemia. Local corticosteroid therapy used as a post-operative treatment potentiates collagenases and inhibits collagen synthesis and wound healing and could thus contribute to the onset of scleral Dellen. [4] Regarding the treatment of this complication, the graft of a conjunctival flap was performed in two cases [3, 6] with favorable evolution. In all other cases, only medical treatment has been successfully initiated [2, 4, 5, 7]. In our case we opted for medical treatment only, including local antibiotic therapy, intensive lubrication with artificial tears (hourly drop) and the occlusion of the eye. The evolution was also favorable under this treatment with the appearance of a conjunctival bud on the seventh day. We removed it the second week. Hence, our case is similar to the Garcias-Medina and collaborators one, concerning the surgical technique, and also the scleral Dellen treatment. Although the difference and the particularity of our case was the absence of cauterization use during the surgical act.

#### **Conclusion:**

Scleral Dellen is rare complication of pterygium surgery, which occurs early after the surgical act. Its exact physiopathology remains unknown, but some factors may be incriminated; first of them is the surgical technique as a simple excision with exposed sclera. Also the per-operative cauterization of the episcleral vessels and the use of local corticosteroid therapy postoperatively. This complication can occur in patients, without any particular medical or ophthalmological history or any underlying pathology. It could also occur for primary pterygium. Medical treatment alone may be appropriate to manage this complication.

#### **References:**

- [1.] Kammoun B, Kharrat W, Zouari K, Zribi W, Kemiha N, Fourati M, et al. Ptérygion: Traitement chirurgical. *J Fr Ophtalmol* 2001;24:823–8.
- [2.] Garcia-Medina J, Del-Rio-Vellosillo M, Zanon-Moreno V, Ortiz-Gomariz A, Morcillo-Guardiola M, Pinazo-Duran M. Severe scleral dellen as an early complication of pterygium excision with simple conjunctival closure and review of the literature. *Arq Bras Oftalmol* 2014;77:182–4.
- [3.] Chen S, Noonan C. Scleral dellen complicating primary pterygium excision. *Eye* 2000;14:100–1.
- [4.] Mitra S, Ganesh A, Shenoy R. Scleral dellen complicating primary pterygium excision. *Eye*. 2000;14 (Pt 6):924-5.
- [5.] Tsai YY, Lin JM, Shy JD. Acute scleral thinning after pterygium excision with intraoperative mitomycin C: a case report of scleral dellen after bare sclera technique and review of the literature. *Cornea*. 2002;21(2):227-9.
- [6.] Safianik B, Ben-Zion I, Garzozzi HJ. Serious corneoscleral complications after pterygium excision with mitomycin C. *Br J Ophthalmol*. 2002;86(3):357-8.
- [7.] Hicks RR, Irvine AR, Spencer WH. Scleral Dellen. *Arch Ophthalmol* 1975;93:88–9.
- [8.] Das S. Recurrence-free pterygium surgery with special surgical technique. *Med J Dr DY Patil Vidyapeeth* 2018;11:492–8.
- [9.] Davari M, Gheytsi H, Davari E. Subconjunctival Mitomycin C Injection into Pterygium Decreases Its Size and Reduces Associated Complications, 2016.
- [10.] Martins TG, Costa AL, Alves MR, Chammas R, Schor P. Mitomycin C in pterygium treatment. *Int J Ophthalmol*. 2016 Mar 18;9(3):465-8.