

Case Report,

Migratory Bronchial Foreign Body: Role of Serial Radiographs and Review of Literature

E.E. Afiadigwe¹, E.N. Chime², G. Obasikene³ B C Ezeanolue⁴

^{1,3} Department of Otorhinolaryngology, Nnamdi Azikiwe University Teaching Hospital, Nnewi, Nigeria

^{2,4} Department of Otolaryngology, University of Nigeria Teaching Hospital, Enugu, Nigeria

Email: ea.afiadigwe@unizik.edu.ng

Abstract:

Foreign body impaction in the airway poses a great challenge of management to any Laryngology facility. Prompt localization of the foreign body and its endoscopic removal are the panacea for the successful extraction of the foreign body

Tracheobronchial foreign bodies depending on their size and site of initial impaction can migrate to other locations in the tracheobronchial tree making their identification and subsequent extraction more challenging for the endoscopist. We present here and review the literature on three cases that throw up such challenges that were successfully managed by the authors to highlight this. Serial radiograph can be useful in the management of such cases especially if delay occurred in its extraction after initial radiograph assessment.

Key words: Foreign body, tracheobronchial tree, Chest radiograph, bronchoscopy

Interoduction:

Foreign body inhalation constitutes life threatening emergencies confronting the Otorhinolaryngologist all over the world. It is more common in children less than four years of age and is also a common cause of accidental death in this age group^{1,2}. Objects commonly inhaled include organic substances such as nuts, resins, seeds and improperly chewed pieces of food, and inorganic objects inhaled include small nails and pins, pencil erasers and components of toys among others. The diagnosis and management can be challenging especially as most incidents occur unwitnessed resulting in delayed or missed diagnosis. Inorganic foreign bodies may be asymptomatic for a variable length of time and may be associated with changing locations. Complications can be seen due to foreign body aspiration both in the acute phase including asphyxia, hemoptysis, cough, respiratory failure, acute infections, and in the chronic period which include bronchiectasis, abscess and atelectasis due to recurrent infections.^{3,4} Though the literature is saturated with cases of

airway foreign body, but report of cases of migration from one bronchus to the other are relatively rare. Whenever there is a delay between time of diagnosis and surgical intervention, migration may lead to missed diagnosis, prolonged or failed procedure and may even lead to operating on the wrong side. We hereby present the report of three cases of inter-bronchial migrating foreign bodies managed successfully in our centers and highlight the role of serial radiograph to avert futile intervention and review the literature

CASE SERIES REPORTS:

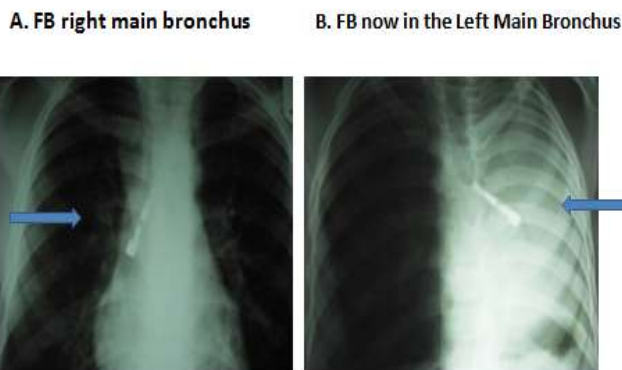
Case 1.

A 9-year old male accidentally inhaled a component of a plastic lighter encasing metal coil he was playing with. Though the history was unequivocal, he had no symptoms. The parents took him for chest X-ray which demonstrated the foreign body in the right main bronchus.

The child was brought to us a week after. On examination the child was not in respiratory distress and the chest was clinically clear.

However, in view of the clinical history and plain chest radiograph findings, bronchoscopy was prescribed but they declined and resorted to faith healing prayers since patient remained symptomless. (Figure 1a.)

Fig 1: Metallic foreign body migrated from R to L main bronchus



The child reported movement of the foreign body as he coughed so the parents believed it would be coughed out sooner than later hence the delay. However out of their curiosity they did a repeat chest X-ray two weeks later which now localized the foreign body in the contralateral left main bronchus. (Figure 1b)

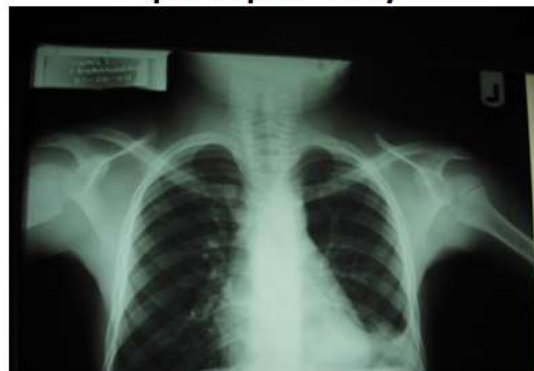Apart from the foreign body that was demonstrated, there was a collapse of the left lung and mediastinal shift to the left. There were no other significant findings. By this time, the child had developed symptoms, of cough, mild fever and easy fatigability. He was then represented to our facility. Patient was offered bronchoscopy to which they consented this time around. Emergency bronchoscopy and extraction of the foreign body was done, and airway suctioned clear of retained purulent secretions. (Figure 2)

Fig 2: The removed foreign body on the right and a prototype(right) beside it



He had rapid resolution of all symptoms and a post- bronchoscopy. Chest X-ray done two days later showed a re-inflated left lung. (Figure 3) On the 3rd post-bronchoscopy day, he was discharged home in good health to complete his course of antibiotics.

Fig 3: CXR of same patient two days post operatively

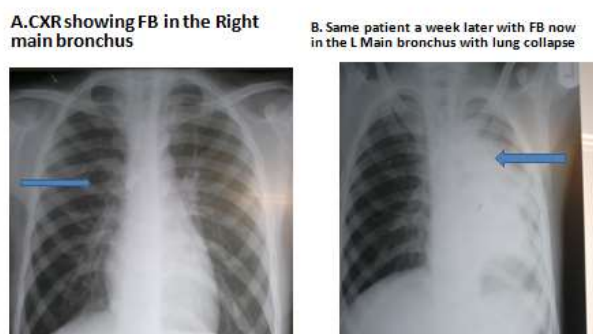


Case 2:

Master OK, a 4-year old male, was referred from another hospital to our facility with 21-day history of foreign body inhalation. An attempted extraction of the foreign body at rigid bronchoscopy seven days prior to the presentation to us, in the referral hospital failed. On presentation, he was clinically stable but for reduced air entry in the left lower lung zone. The first chest radiograph taken at the referral hospital, before the failed intervention, showed an opaque shadow in the right main bronchus and collapse of the right lower lung segment.

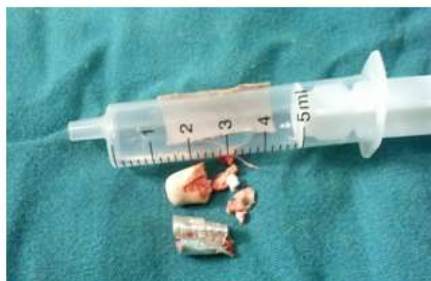A repeat chest radiograph taken one week after the failed rigid bronchoscopy showed an opaque shadow in the contralateral left main bronchus and re-expansion of the hitherto collapsed right lower lung segment. (Figures 4a and 4b).

Fig 4: CXR showing foreign foreign body



We performed rigid bronchoscopy a day after presentation, and a pencil-eraser with its metallic casing was removed from the left main bronchus. (Figure 5)

Fig 5: Picture showing the extracted eraser and its metallic casing disassembled.

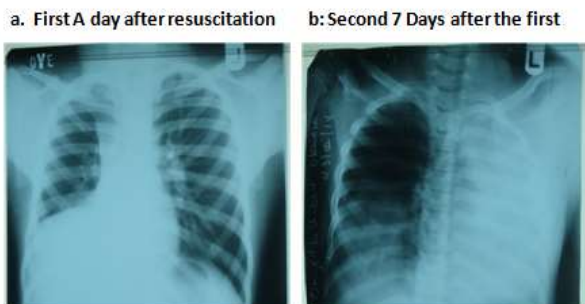


A repeat post-bronchoscopy chest X-ray showed no foreign body shadow and clear lung fields. He was discharged a day after the foreign body removal to the referring physician. A feedback from the referral hospital attested to the patient remaining clinically stable since after the removal of the foreign body at rigid bronchoscopy.

CASE 3: ⁵

An 8-year old boy was brought to our facility in an ambulance, from a location that is 250 kilometres away. The history was that of accidental aspiration of a plastic pen stopper-end about 3 weeks earlier while playing with it in his mouth. He was taken to a neighbourhood clinic a day later because of irritating cough. The parents were reassured and medicines for cough was dispensed to him at the Clinic. The cough persisted but was considered non-significant by the parents.

Fig 6:C-xrays showing Foreign body first in the Right(a) and later in the Left(b)



A week later, the condition took a dramatic turn for the worse when he suddenly passed out while at

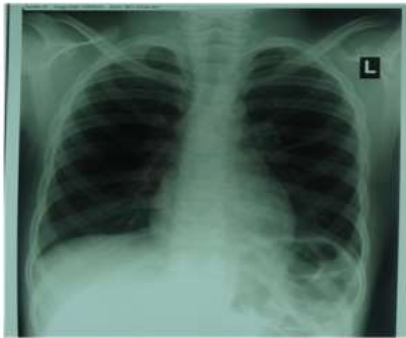school playground. The parents were called, and they evacuated him to be hospitalised for resuscitation at the Emergency Room of a government hospital in another state of the federation. He was investigated including plain X-ray examinations. Figure 6a below is image of a plain chest radiograph taken then. There was logistic delay in receiving prompt treatment so they consulted another doctor. The attending doctor felt that the X-ray film he was viewing was not in agreement with the clinical findings of the child. He then ordered a repeat chest X-ray. The Figure 6b below showed the second plain chest x-ray taken 7 days after the first one. Note opacity of the left lung fields, tracheal and mediastinal shift to the left, emphysematous right lung field and partial re-aeration of the right lower lung field. His clinical condition deteriorated, and child was having severe respiratory distress. He was commenced on intra-nasal oxygen, referred, and transported in the ambulance to our facility. On presentation, his Oxygen saturation, SPO2 was 93 to 94% but started dropping precipitously when the oxygen was momentarily discontinued, to test his saturation level in breathing atmospheric air. The oxygen delivery tubes were immediately reconnected. An emergency rigid bronchoscopy was done under general anaesthesia. Operative findings were normal tracheobronchial tree but with a plastic cone-shaped object impacted in the left secondary bronchus. This was extracted with grasping forceps. (Figure 7) Air way was suction cleared of retained secretions.

Fig 7: Foreign body extracted from Case 3



Check chest X-ray (Figure 8) done 8 hours after bronchoscopic extraction of the foreign body showed resolution of chest radiographic disorders to normal findings.

Fig8: CXR of patient(Case3) 8hrs
Post op



Discussion:

Foreign body (FB) aspiration is common in otorhinolaryngological practice. However, migration of aspirated foreign bodies is uncommonly reported in literature.⁶ we reported three such unique cases here. Children younger than three years old, with the peak incidence between one to two years of age account for the majority of cases of airway foreign bodies.^{6,7,8,9,10} Male preponderance has been reported and all patients in this series are males¹¹. Their ages were higher at 4, 8 and 9 years. A foreign body aspirated into the air passage can lodge in the larynx, trachea, or bronchi. Of these cases, 80% to 90% are found in the bronchi because the size of most aspirated foreign bodies and their configuration allow passage through the larynx and trachea. Larger objects however become impacted in the larynx or trachea, at times causing complete obstruction, a acute emergency¹². Organic foreign bodies are the most common items aspirated by children, whereas in adults a variety of items may be encountered. In this series the foreign bodies were in the bronchi and only migrated from one side to the other with attendant changes in clinical features in a significant number of patients, after aspiration of foreign bodies, clinical features including choking attacks, coughing, wheezing asphyxia and sudden death can be observed in the acute period. In some cases especially aspiration of inorganic material, this is followed by the latent phase during which the patient appears asymptomatic as happened in our first and third cases.

The diagnosis of foreign bodies is easily established using plain radiographs when the item aspirated is radio-opaque as in our first two cases. However most aspirated FBs are radiolucent and are not detected with plain radiograph unless

accompanying complications, such as lung collapse, emphysema or mediastinal shift set in^{13,14}. Absence of radio-opaque shadow in a plain chest radiographs does not exclude the possibility of foreign body aspiration; but chest radiographs are necessary as it may localize a FB and increase the chances of definitive diagnosis even in the absence of a positive history.¹⁵ Bronchoscopy is the treatment modality for foreign bodies in the tracheobronchial tree^{16,17}. It is also a diagnostic procedure and hence recommended in all patients with history of FBs aspiration with minimal or no radiological signs. Hence, various researchers have opined that Otolaryngologist must proceed for bronchoscopy even when there is a mere suspicion of foreign body aspiration.^{9,13,17} After lodging in one side, preoperative migration of the foreign body to contralateral side is a possibility as we encountered. The shape and chemical nature of the foreign body influences this tendency to migrate. Forceful expiratory and inspiratory tidal air flow in the bronchi could be blowing the foreign body in and out of bronchi. Coughing action would aid these movements. A relatively bigger internal diameter of the bronchi to the size of the foreign bodies may contribute to ability to be blown from one side to another by the tidal air flow. Irregularly shaped objects and sharply pointed objects tend to stick to the mucosa of the tracheobronchial tree and would not flap about.^{18,19}

Our cases were inorganic foreign bodies that are generally inert, and these may migrate even when they have been aspirated a long time previously.^{18,19}

Early diagnosis and prompt removal are crucial to good clinical outcome. Missed or delayed diagnosis of migratory foreign bodies is invariably fatal¹⁵. Diagnosis of FB aspiration in children could be challenging, and often the delay in diagnosis and treatment result from several factors such as physician misdiagnosis, failure by caregivers to seek early medical attention, discharge against medical advice, among others^{11,20,21,22}. In our third case the initial Physician missed the diagnosis and adopted a conservative approach but the second one was able to interrogate the discrepancies of radiograph and clinical findings. The three cases presented illustrated the need to have recent radiograph. Numerous authors have observed that bronchial foreign bodies predominantly are lodged in the right main bronchus compared to the left, citing the anatomy as the explanation.^{3,9} These cases in our series had the foreign body localized in the right

main bronchus before migration to the left. Migration is thought to be associated with bouts of cough or sometimes induction of anesthesia. The endoscopist should always assume that a foreign body may have migrated and that there may be additional foreign bodies that are missed initially thus justifying a check into the other bronchus with a 'second look' after foreign body extraction.

Conclusion:

Foreign bodies in the tracheobronchial tree may migrate especially if treatment was delayed. It is advisable to get a most recent radiograph before bronchoscopy to facilitate localization and prevent unwarranted prolongation of operating time. This does not exonerate the Endoscopist from clinical assessment for changes in patients' local signs just before commencing bronchoscopy

References:

- [1.] Mantel K, Butenandt I. Tracheobronchial Foreign Body Aspiration in Childhood: a report of 224 cases. *Eur J Pediatr* 1986; 145: 221-6
- [2.] Schmidt H, Manegold BC. Foreign Body Aspiration in Children. *Surg Endosc* 2000; 14 (7): 644-8.
- [3.] Kim IG, Brummit WM, Humphry A, Siomra SW, Wallace, WB. Foreign Body in the Airways: A Review of 202 Cases. *Laryngoscope* 1973; 83; 347.
- [4.] Sayir F, Cobanoglu U, Sertoğullarından B, Mergan D, Cerrahisi G, Hastalıkları G et al. A Foreign Body Aspiration Showing Migration and Penetration: Hordeum Murinum. *J Clin Anal Med* 2012; 3 (4): 454-6.
- [5.] Ezeanolue BC. Do not be afraid and do not fail to Rescue: a discourse on the challenges confronting the Nigeria Health Sector. 36th Convocation Lecture of the National Postgraduate Medical College of Nigeria. Ijanikin Nigeria 20 September 2018.
- [6.] Arun, K C, Sinha B K, Guragain, R. Migrating foreign body bronchus, Nepalese Journal of ENT Head & Neck Surgery Vol. 2 No.2 Issue2 (July-Dec 2011), 22-24.
- [7.] Majori M, Fecci L, Monica M, Casali AG. Airway Foreign bodies. *Monaldi Arch Ches Dis* 2011; 75; 1, 86-8.
- [8.] Eren S, Balci AE, Dikici B, Dobra M, Eren MN Foreign body aspiration in children: experience of 1160 cases. *Ann Trop Paediatr* 2003; 23; 31-7
- [9.] Srppnath J, Mahendrakar V. Management of Tracheo-bronchial Foreign Bodies - A Retrospective Analysis. *Indian Journal of Otolaryngology and Head and Neck Surgery* Vol. 54 No. 2, April - June 2002; 127-131.
- [10.] Tan Hk, Brown K, McGill T, Kenna MA, Lund DP, Healy GB Airway Foreign bodies (FB); a 10-year review. *Int J Pediatr Otorhinolaryngol* 2000; 56;91-9.
- [11.] Eyekpegba, OJ, Onakpoya, UU, Obiajunwa, PO, Famurewa, OC, Ogunrombi, AB. Missed Distal Tracheal Foreign Body in Consecutive Bronchoscopies in a 6-year-old Boy. *Nigerian Journal of Surgery*, 2019; Vol 23 (1); 67-70
- [12.] Raman Wadhera, Sat Paul Gulati, Vijay Kalra, and Anju Ghai, Migrating Foreign Body in the Bronchus, *Otolaryngology–Head and Neck Surgery* 145(4) 2011, 701-702
- [13.] Orji, FT, Akpeh, Jo Tracheobronchial Foreign Body Aspiration in Children: How Reliable Are Clinical and Radiological Signs in the Diagnosis? *Clin Otolaryngology* 2010 Dec; 35(6):479-85.
- [14.] Haddadi, S, Marzban, S, Nemati, S, Kiakelayeh, SR, Parvizi, A, Heidarzadeh, A. Tracheobronchial Foreign-Bodies in Children; A 7 Year Retrospective Study. *Iran J Otorhinolaryngol* 2015 Sep; 27(82):377-85
- [15.] Oviawe, O, Abhulimhen- Iyoha, B.I, Obaseki, D.E. Migrating Foreign body in the tracheobronchial tree of Children: Report of two cases. *The Nigerian Postgraduate Medical journal*, vol.18, No.2, June 2011. 154-157
- [16.] Saquib Mallick M, Rauf Khan A, Al-Bassam A. Late presentation of tracheobronchial foreign body aspiration in children. *J Trop Pediatr* 2005; 51:145-8
- [17.] 17: Ihssan Ali Hais Elamery. Head Scurf pin Aspiration, A sub type of Foreign Body Aspiration. *Diyala Journal of Medicine*, June, 2019. 101 Vol.16. 101-106.
- [18.] Ryutaro Kikuchi, Noritaka Isowa, Hirokazu Tokuyasu, Yuji Kawasaki. Intraoperative migration of a nail from the left B10 b to the main bronchus. *Interactive Cardiovascular and Thoracic Surgery* 6 (2007) 92-3.

- [19.] Parray, T, Abraham, E, Apuya, J, Ghafoor A, Siddiqui M. Migratory Foreign Body from right to left lung. The Internet Journal of Anaesthesiology. 2009 Volume 24 Number 1
- [20.] Hilliard, T, Sim, R Saunders,M, Hewer,SL, Henderson,J. Delayed diagnosis of foreign body aspiration in children. Emerg Med J 2003;20:100–101
- [21.] Chew HS, Kun H, Tan K, Airway Foreign Body in Children. International Journal of Clinical Medicine, 2012, 3, 655-660. Published Online December 2012 (<http://www.SciRP.org/journal/ijcm>) (655) {delay due to phys} <http://dx.doi.org/10.4236/ijcm.2012.37117>
- [22.] Sivakumar E, Ramasubramaniam P. Foreign Body Aspiration in Children. Int J Contemp Pediatr. 2020 Jan;7(1):94-98 <https://www.researchgate.net/publication/338152269> [accessed Apr 24 2020].