

International Journal Of Medical Science And Clinical Inventions

Volume 2 issue 06 2015 page no. 1032-1034 ISSN: 2348-991X

Available Online At: <http://valleyinternational.net/index.php/our-jou/ijmsci>

# ICH/IVH A Consequence Of Non Oliguric Hyperkalemia With Hypoglycemia In A Late Preterm With Perinatal Asphyxia: A Case Report

C. Rohit kiran<sup>1</sup>, Sudhanshu kumar Das<sup>2</sup>, S. Udayakanth<sup>3</sup>, M. Amarendra<sup>4</sup>

<sup>1</sup> Post graduate, KIMs medical college , <sup>2</sup> Assistant Professor of KIMs medical college ,

<sup>3</sup> Associate Professor, Mallareddy institute of medical science, Hyderabad

<sup>4</sup> Associate Professor KIMs medical college, Amalapuram, A.P

**Corresponding Author:** Dr Sudhanshu kumar das,

Assistant Professor, Dept. Of Pediatrics, KIMS medical college, Amalapuram, A.P

## Abstract:

*Nonoliguric hyperkalemia (NOHK) is common during the first days after birth in premature infants with gestational age <28 weeks. It was rarely reported in term or late preterm infants. Here we presented a case of a late preterm 36 weeks gestation baby, delivered by NVD had seizure due to stroke/IVH confirmed by USG brain with hyperkalemia (7 Mg/dl) and hypoglycemia (37mg/dl) at 24 hrs of life . Our aim is to present the rare cases along with review of the literature.*

**Key Words-** Nonoliguric hyperkalemia, Late preterm, Apgar score ,Intraventricular hemorrhage.

## Introduction

Nonoliguric hyperkalemia (NOHK) has been defined as serum potassium 7 mmol/L during the first 72 hours of life in the presence of urinary output of >1 mL/kg/h .<sup>1</sup> It was reported that more than 80% of babies with NOHK were ELBW infants with gestational age below 28 weeks.<sup>2</sup> This reversible condition does not appear to be related to renal failure, increased potassium intake, or excessive bruising.<sup>3</sup> It was significantly associated with fetal distress, early metabolic acidosis, early hyperglycemia, and absence of antenatal steroid administration by decreasing potassium transport towards the intracellular space and intracellular potassium into the extracellular space by leaking or shifting.<sup>4,5</sup> Neonatal hyperkalemia could result in cardiac arrhythmias and has been associated with the development of periventricular leukomalacia , brain hemorrhage and sudden death.<sup>4</sup>

Here we are presenting a case of nonoliguric hyperkalemia in a late preterm baby which was due to birth asphyxia with hypoglycemia in association with intraventricular hemorrhage.

## Case Report

A 24hrs old male baby was admitted with history of cardiopulmonary arrest.,who revived after resuscitation with bag and mask in the Nicu. He is a late preterm 36 wks gestation baby, delivered to a primi mother by NVD . He did not cry immediately after birth ,with apgar score 4 , 6 at 1, 5 min respectively ,required bag and mask ventilation for 10 second.. There was no history of any maternal illness complicating the pregnancy. . He was on breast feed at 2 hrs of life. At the time of admission ,his heart rate was 0/min , no spontaneous respiratory efforts and bluish discoloration of body . Physical examination

revealed a intrauterine growth retarded baby with a weight of 1.7 kg, length 45 cm .Cardiovascular and Respiratory examination revealed no abnormality. Gastrointestinal system was normal. Central nervous system revealed hypertonia in all four limbs . He developed tonic type of seizure, 15 minutes after resuscitation .Laboratory investigation showed random blood sugar 37mg/dl ,hemoglobin-17.3 gm%, hematocrit 62% and white blood cell count 9,000with normal differential and platelets. Serum urea nitrogen was 15 mg%, creatinine 0.9 mg%. Serum electrolytes were Na- 132mg/dl and K- 7 mg/dl . Urinalysis showed a specific gravity of 1.015, pH 7, and negative protein and cells with urine output > 1 ml/kg/hr. Abdominal and pelvic ultrasound revealed no abnormalities. Electrocardiogram showed peak T waves, increasing PR interval, wide QRS complex with 174 bpm of the heart rate.

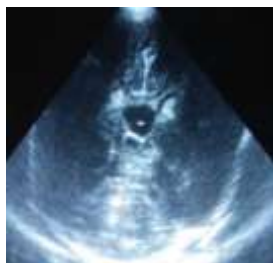


Fig1: Ultrasonogram of brain showing increased echogenicity in thalamus and basal ganglia

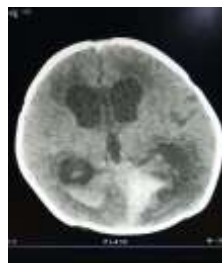

Fig2: CT scan of brain showing ICH and IVH

Ultrasonogram of brain showed HIE changes (increased echogenicity in thalamus and basal ganglia ). CT scan of brain showed increased hyperdensity in occipital horn of ventricle and in parenchyma.

### Discussion

A study by Yaseen *et al.*<sup>6</sup> demonstrated that more than 80% of babies with NOHK were

extremely low birth weight infants .The mechanism of NOHK is suggested mainly an immature function of Na/K ATPase activity in severe prematurity resulting in an internal potassium from intracellular to plasma. In 1977, Perkkiö and Rähkä reported a single episode of hyperkalaemia at the age of 17 hrs in an otherwise healthy premature infant, representing the first description of a clinical entity now referred to as nonoliguric hyperkalaemia of the premature infants.<sup>7</sup> It is more common in extremely low birth weight infants than term infants and the reported incidence varies widely between 11% and 52%.. .

We think that the biochemical abnormalities in this baby were due to decreased potassium transport towards the intracellular space resulted from birth asphyxia, but in a study by Thayyil *et al.*<sup>8</sup> no any association with Apgar scores or gestation with hyperkalemia was found.. As neonatal hypoxia and neonatal hypoglycemia all contribute to brain injury, one should separate the injuries of the two factors on the basis of the imaging appearance. Barkovich *et al.*<sup>9</sup> found that the pattern of brain damage in neonatal hypoglycemia was mainly localized primarily to the parietal and occipital cortex of the brain, whereas the common types of injury in the preterm brain from ischemia are intraventricular hemorrhage (IVH) and periventricular white matter injury. Rutherford *et al.*<sup>10</sup> recommended that DWI is a clinically useful for the early identification of ischaemic tissue in the neonatal brain. The treatment of hyperkalemia in infants varies among institutions. Calcium gluconate was admitted if characteristic electrocardiogram developed. The limitations of this report were that the creatinine clearance and fractional excretion of Na and K were not calculated to understand the renal function.

### conclusion,

NOHK mainly affects extremely low birth weight premature infants and rarely in term or late preterm. It is associated with other electrolyte disturbances with high morbidity and mortality. In our report hyperkalemia due to asphyxia resulted in cardiac arrhythmias and has been associated with the development of brain hemorrhage. A future study with larger samples is needed.

## Reference

1. Vemgal P, Ohlsson A. Interventions for non-oliguric hyperkalaemia in preterm neonates. *Cochrane Database Syst Rev* 2007;1:CD005257.
2. Brion LP, Schwartz GJ, Campbell D, et al. Early hyperkalaemia in very low birthweight infants in the absence of oliguria. *Arch Dis Child* 1989;64:270-2.
3. Mildenerger E, Versmold HT. Pathogenesis and therapy of non-oliguric hyperkalaemia of the premature infant. *Eur J Pediatr* 2002;161:415-22.
4. Sato K, Kondo T, Iwao H, et al. Internal potassium shift in premature infants: cause of nonoliguric hyperkalemia. *J Pediatr* 1995;126:109-13.
5. Stefano JL, Norman ME, Morales MC, et al. Decreased erythrocyte Na<sup>+</sup>,K<sup>(+)</sup>-ATPase activity associated with cellular potassium loss in extremely low birth weight infants with nonoliguric hyperkalemia. *J Pediatr* 1993;122:276-84.
6. Yaseen H. Nonoliguric hyperkalemia in neonates: a case-controlled study. *Am J Perinatol* 2009;26:185-9.
7. Perkkiö M, Rähä N. Neonatal hyperkalaemia. *Lancet* 1977;2:143.
8. Thayyil S, Kempley ST, Sinha A. Can early-onset nonoliguric hyperkalemia be

predicted in extremely premature infants? *Am J Perinatol* 2008;25:129-33.

9. Barkovich AJ, Ali FA, Rowley HA, et al. Imaging patterns of neonatal hypoglycemia. *AJNR Am J Neuroradiol* 1998;19:523-8.
10. Rutherford M, Malamateniou C, McGuinness A, et al. Magnetic resonance imaging in hypoxic-ischaemic encephalopathy. *Early Hum Dev* 2010;86:351-60.