

Case report,

Prostate Cancer Metastasis Causing Occipital Condyle Syndrome: A Rare Clinical Entity

Nurlan İsayev, MD¹; Levent Yücel, MD²; Hatice Seçil Akyıldız, MD³; Hazan Başak, MD³; Süha Beton, MD³; Cem Meço, MD^{3,4}

¹ Department of Otorhinolaryngology, HB Guven Clinic, Baku, Azerbaijan

² Department of Otorhinolaryngology, University of Health Sciences, Gülhane Training and Research Hospital, Ankara, Turkey

³ Department of Otorhinolaryngology, Faculty of Medicine, University of Ankara, Ankara, Turkey

⁴ Department of Otorhinolaryngology, Salzburg University Paracelsus Medical School, Salzburg, Austria

Email Address: leventyucel51@hotmail.com

Abstract:

Introduction: Prostate cancer metastasis to clivus and occipital condyle are extremely rare. We present a case with metastasis of prostate cancer to skull base causing occipital condyle syndrome (OCS).

Case Presentation: A-56-year-old man was referred to our clinic with complaints of dysphagia for two months and headache on his right occipital region for five months. There was deviation of the tongue to the right side in his physical examination. He underwent a surgery for prostate adenocarcinoma for two years ago. Magnetic resonance imaging and computed tomography showed a mass destructing to the clivus and right occipital condyle. Biopsy confirmed the prostate adenocarcinoma metastasis. The patient died after two months from diagnosis of skull base metastasis.

Conclusion: Otolaryngologists, urologists and neurologists should be aware for early diagnosis of OCS in a patient with prostate cancer. Early physical and radiological examination of the patients may improve the prognosis.

Keywords: Headache, hypoglossal nerve palsy, occipital condyle syndrome, prostate cancer, skull base.

Interoduction:

The course of hypoglossal nerve (CN XII) predisposes many different etiologies for palsy. Carotid endarterectomy, direct laryngoscopy, intubation are main operative causes of CN XII palsy [1]. Trauma, radiation and primary or metastatic tumors of skull base are nonoperative causes of CN XII palsy and metastatic malignancies are account for 13% for all CN XII palsies [2].

Prostate cancer is the most common cancer in males but skull base metastasis is rare [3, 4]. Many different clinical forms has been described before such as occipital condyle syndrome (OCS), Villaret's syndrome, Collet-Sicard syndrome [5, 6]. OCS consists of unilateral occipital pain that may radiate to mastoid, ear and vertex with ipsilateral CN XII palsy and mainly caused by metastatic cancer [5]. Prostate cancer metastasis to clivus and occipital condyle are extremely rare and

only a few cases have been reported [7]. We present a case with late metastasis of prostate cancer to skull base causing OCS.

Case presentation:

A-56-year-old man was referred to our clinic with complaints of dysphagia for two months and headache on his right occipital region that radiated to mastoid and ear without any tenderness for five months. There was deviation of the tongue to the right side and hypotonia of anterior two thirds of tongue in his physical examination (Figure 1) and other cranial nerves' functions were normal. His medical history included a surgery for prostate adenocarcinoma 2 years ago and received hormonal therapy for multiple bone and lung metastasis. The bone scintigraphy performed 7 months before diagnosis of skull base metastasis showed that all metastatic lesions disappeared with hormonal therapy except for L1 vertebra. A

magnetic resonance imaging (MRI) revealed a mass located in the clivus and right occipital condyle and destructed them, showing diffusion restriction, hypointense in T1-weighted images, hyperintense in STIR sequences and enhancing in post-contrast series (Figure 2). The destruction of clivus and occipital condyle was confirmed with paranasal sinus computed tomography (CT) (Figure 3). The prostate specific antigen (PSA) value was 6.58 ng/ml.

The preliminary diagnosis was prostate cancer metastasis to skull base, occipital condyle syndrome, and endoscopic transnasal transsphenoidal biopsy was performed. The pathological examination confirmed the prostate adenocarcinoma metastasis. The patient was not a candidate for a skull base surgery. The patient's performance got worse after second dose of chemotherapy and radiotherapy, and the treatment had to be stopped. Narcotic drugs for severe headache were administered. He died after two months from diagnosis of skull base metastasis.

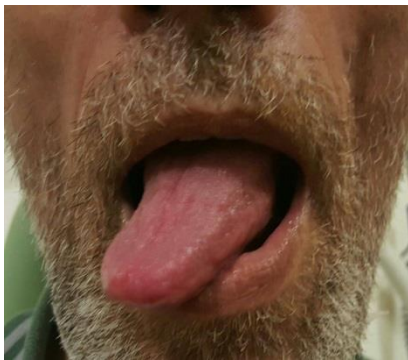

Figure1: The deviation to the right side and atrophy of right two anterior thirds of tongue.

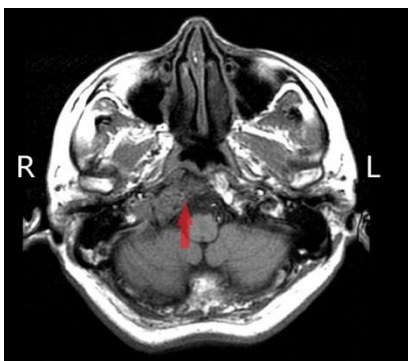


Figure2: Axial T1-weighted MRI image shows a mass located in the clivus and right occipital condyle (Red arrow: metastasis).

Discussion:

The course of CN XII is divided into five parts: the first is medullar, second cisternal, third skull base, fourth nasopharyngeal or carotid and fifth sublingual part [8]. There are many etiologies for CN XII palsy and the symptoms are depend on

where the lesion is. Prostate cancer metastasis to skull base is approximately responsible for 2,5% of all CN XII palsy [2]. Greenberg described first OCS in 1981 in a skull base metastasis series [9]. In this series, he also described Villaret's syndrome and Collet-Sicard syndrome. The lower four cranial nerve palsy is called for Collet-Sicard syndrome and when it is associated with Horner syndrome, this is known as Villaret's syndrome. Finally, occipital headache with CN XII palsy, as in our case, has been called OCS.

OCS is twice as frequent in men and metastasis to skull base is late process of the disease as in our case [7]. However, OCS may be the initial symptom of the metastatic cancer as described "visible part of the iceberg" by Raggabi et al [10]. In a series of 11 patients, the CN XII palsy in OCS may occur after headache by several to 10 weeks [5]. In our case, CN XII palsy occurred after 3 months severe headache. In this series, there was tenderness of the occipital region in all patients in contrast to our case.

The diagnosis of skull base metastasis is mainly with CT and MRI. MRI is superior to CT for demonstrating soft tissue masses with 82% sensivity and enhanced sagittal and axial T1-weighted images with normal hyperintense fat by hypointense soft tissue are the most useful sequeance for detecting tumor [7]. Additional tests such as PSA is also recommended. The biopsy from the metastasis may be difficult to perform in contrast to our case and in a recent study, a new method has been described for biopsy called "minimally invasive tubular approach" [11].

The outcome of the prostate cancer with OCS is very poor and the survival was 2 months in our case. The treatment mainly consists of radiotherapy and/or chemotherapy. The conventional analgesics are not enough for OCS pain [7]. Narcotic analgesics are usually needed as in our case.

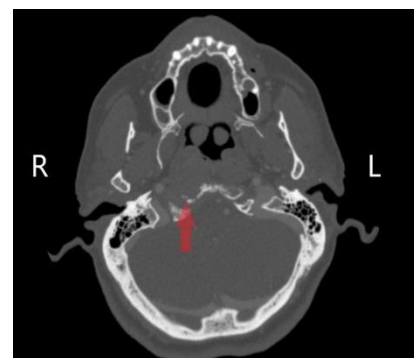


Figure3: Axial CT image shows the destruction of clivus and right occipital condyle (Red arrow: metastasis).

Conclusion:

Otolaryngologists, urologists and neurologists should be aware for early diagnosis of OCS in a patient with prostate cancer. Early physical and radiological examination of the patients may improve the prognosis.

Acknowledgements

None

Author contributions

Conception – N.İ., L.Y., H.S.A.; Design – L.Y., H.S.A., S.B.; Supervision – H.B., S.B., C.M.; Fundings – Not applicable; Data Collection and/or Processing –N.İ., L.Y., H.S.A., H.B; Analysis and/or Interpretation –.; N.İ., H.B., S.B.; Literature Review- L.Y., N.İ., H.S.A., H.B., S.B., C.M.; Writing Manuscript – N.İ., L.Y.; Critical Review – H.B., S.B., C.M.

Funding

This study did not receive any specific grant from funding agencies in the public, commercial, or not-for-profit sectors.

Conflict of interest

The authors declare that they have no conflict of interest.

Ethical approval

Not required.

Informed consent

Written informed consent was obtained from Patients family” who participated in this study.

References:

[1] Yücel L, Büyükatalay ZÇ, Yorulmaz İ. A rare complication of direct laryngoscopy: unilateral hypoglossal nerve palsy. *ENTcase* 2020; 6: 66-70. http://entcase.net/manuscript_in_pdf_yeni/563/makale/laringoloji/a-rare-complication-of-direct-laryngoscopy-unilateral-hypoglossal-nerve-palsy.htm

[2] Stino AM, Smith BE, Temkit M, Reddy SN. Hypoglossal nerve palsy: 245 cases. *Muscle Nerve* 2016; 54: 1050-1054. <https://doi.org/10.1002/mus.25197>

[3] Shah SH. Reversible, isolated, unilateral hypoglossal nerve palsy due to metastatic prostate cancer. *Palliat Med* 2006; 20: 639-640. <https://doi.org/10.1177/026921630602000605>

[4] Douglas JE, Lee JY, Rajasekaran K. Cranial Nerve VI Palsy as Presenting Sign of Previously Undiagnosed Metastatic Prostate

Adenocarcinoma to the Clivus. *Biomed Hub* 2020; 5: 1-4. <https://doi.org/10.1159/000510303>

[5] Capobianco DJ, Brazis PW, Rubino FA, Dalton JN. Occipital condyle syndrome. *Headache* 2002; 42: 142-146. <https://doi.org/10.1046/j.1526-4610.2002.02032.x>

[6] Gutierrez S, Warner T, McCormack E et al. Lower cranial nerve syndromes: a review. *Neurosurg Rev* 2020; 1-11. <https://doi.org/10.1007/s10143-020-01344-w>

[7] Rodríguez Pardo J, Lara Lara M, Sanz Cuesta BE et al. Occipital condyle syndrome: a red flag for malignancy. *Comprehensive literature review and new case report. Headache* 2017; 57: 699-708. <https://doi.org/10.1111/head.13008>

[8] Guarnizo A, Glikstein R, Torres C. Imaging Features of isolated hypoglossal nerve palsy. *J Neuroradiol* 2020; 47: 136-150. <https://doi.org/10.1016/j.neurad.2019.04.006>

[9] Greenberg HS, Deck MD, Vikram B et al. Metastasis to the base of the skull clinical findings in 43 patients. *Neurology* 1981; 31: 530-530. <https://doi.org/10.1212/wnl.31.5.530>

[10] Raggabi A, Lalya I, Bourazza A. Occipital condyle syndrome: the visible part of the iceberg. *Pan Afr Med J* 2019; 33: 268-268. <https://doi.org/10.11604/pamj.2019.33.268.19280>

[11] Platt A, Stamates MM, Wong RH. Minimally Invasive Tubular Approach for Occipital Condylar Biopsy and Resection: Case Report and Review of Literature. *World Neurosurg* 2020; 137: 276-280. <https://doi.org/10.1016/j.wneu.2020.02.066>