

## Research Article,

# Effect of Microneedling Associated With Drug Delivery on Facial Rejuvenation: Clinical and Histological Evaluation

Rafaella Rêgo Maia<sup>1</sup>; Rodrigo Marcel Valentim da Silva<sup>2</sup>; Stephany Luanna Queiroga Farias<sup>3</sup>; Liliane Santos de Vasconcellos<sup>1</sup>; Eneida de Moraes Carreiro<sup>4</sup>; Patrícia Froes Meyer<sup>4</sup>; Fábio dos Santos Borges<sup>5</sup>; Felipe Alexandre Afonso<sup>1</sup>; Fernando César Câmara de Oliveira<sup>1</sup>; Ciro Dantas Soares<sup>6</sup>; Joyce Rodrigues<sup>7</sup>

<sup>1</sup> Federal University of Rio Grande do Norte (UFRN), Natal, RN, Brazil.

<sup>2</sup> Estácio de Sá University, Natal, RN, Brazil.

<sup>3</sup> Potiguar University (UNP), Natal, RN, Brazil.

<sup>4</sup> University Centre of Rio Grande do Norte (UNI-RN), Natal, RN, Brazil.

<sup>5</sup> Estácio de Sá University, Rio de Janeiro, RJ, Brazil.

<sup>6</sup> Campinas State University (UNICAMP), Campinas, Brazil.

<sup>7</sup> São Judas Tadeu University, Butantã, Brazil.

Email Address: [maia.rafaella20@gmail.com](mailto:maia.rafaella20@gmail.com)

### Abstract:

**Introduction:** Microneedling has been used to treat different human connective tissue disorders, promoting an increase in the permeation of active ingredients, to favour local vascularization and collagen production.

**Objective:** To investigate the effects of microneedling associated with the permeation of cosmetological actives (drug delivery) on facial rejuvenation.

**Method:** This was a controlled clinical trial, in which 30 volunteers with facial aging were recruited and distributed into 2 groups. G1 was treated with microneedling with associated saline and G2 received microneedling with associated drug delivery (with growth factors) in the entire facial region (full face). Both groups received two treatment sessions with an interval of 30 days between them. For result evaluation, photos were clinically analysed before and after the interventions, the facial symmetry was verified through the measurement of angles and measurement of the facial region, and a histological analysis of the eyelid region of two patients who underwent surgery blepharoplasty was carried out.

**Results:** Both groups presented satisfactory clinical results in the photographs' visual analysis. In the evaluation of facial symmetry, G2 showed an improvement in the measurements of the paralateral nasal L-projection, nasolabial F-crease, right and left lateral palpebral crease, with  $p < 0.01$ . In the histological analysis, G2 showed higher collagen and elastin increase than G1, with greater predominance of better-quality collagen (type I) when drug delivery was performed.

**Conclusion:** The association of microneedling with growth factors promotes a greater production of collagen fibres and connective tissue reorganization, compared to microneedling with no cosmetological assets.

**Keywords:** Aging; Growth Factors; Collagen; Rejuvenation.

### Introduction:

Microneedling or collagen induction therapy is a technique that uses a roller-shaped applicator with its surface studded with needles that puncture the skin surface, producing micro lesions and ruptures that generate an inflammatory response and induces the reorganization of collagen and elastin

<sup>1,2</sup>. Collagen induction does not cause the total de-epithelialization observed in ablative techniques; thus, it favours the remodelling of depressed scars and wrinkles with less aggression and limitations<sup>3,4</sup>. In the microneedling technique there is also the "removal" of the epidermis' protective layer, causing a new production of cells, keratin,

and collagen fibres to occur, repairing the damaged areas. Due to the removal of the protective layer, the release of cytokines and the dissociation of keratinocytes causes a vasodilation, after which the keratinocytes migrate to the site, restoring the injured tissue<sup>5, 6</sup>. Microneedling has been widely used as a transdermal transport system, allowing the permeation of drugs or active substances into the skin, being used for the treatment of acne scars, stretch marks, flaccidity, alopecia, among others<sup>7, 8, 9</sup>.

Among the substances that could be used in this permeation response in order to activate collagen and promote healing, the TGF  $\beta$ 3 (Transforming growth factor  $\beta$ 3) is worth a mention, as it is capable of acting on the growth, proliferation, and differentiation of several types of cells, mainly fibroblasts. It is one of the most potent fibrogenic mediators, able to considerably increase the levels of collagen and elastin of the skin and it is highly inflammatory<sup>10</sup>. The EGF (epidermal growth factor), obtained through biotechnology by using the recombinant protein technique, is 100% homologous to human proteins and has healing, tissue repair, and filler actions<sup>11</sup>. The silicon also appears to have a stimulating effect on collagen synthesis, as it is believed that the enzyme proline hydroxylase, resulting from collagen synthesis, reaches its maximum activity only in the presence of an adequate silicon concentration. The hyaluronic acid's low molecular weight, in addition to filling, also stimulates the growth factor IGF-1 (insulin growth factor), responsible for the skin's germinative function, and it also decreases matrix metalloproteinases, preventing the degradation of structural proteins<sup>12, 13</sup>.

Despite the effects of microneedling and drug delivery when applied in isolation, and despite showing satisfactory results in facial rejuvenation, information still lacks regarding their combined use. Therefore, the purpose of this study was to investigate the effects of microneedling in association with the permeation of cosmetological assets (drug delivery) on facial rejuvenation.

### **Methodology:**

This was a randomized clinical trial. The volunteers were seen in a dermatofunctional physiotherapeutic treatment clinic and this study was submitted to the Research Ethics Committee (CEP) of Universidade Potiguar - UnP, approved

under number 023108/2019. Participants were instructed regarding the procedures they would undergo and signed the Free and Informed Consent Form.

### **Population and sample:**

This study sample consisted of 30 women of ages between 45 and 60 who presented facial skin aging (tissue flaccidity, wrinkles, elastosis), with no problems related to healing, keloid or any collagen-related disorders, in addition to serious metabolic diseases. Volunteers who gave up treatment before the end of interventions, absence from evaluations or sessions, and if there were any complications following the application were excluded.

### **Research tools:**

The applicator of the "Roller" type microneedling technique, branded by Doutor da Estética™ (São Paulo, Brazil) was used. It consists of 540 titanium microneedles with 1.5 mm in length studded in a cylinder; a surgical procedure punch; and Canon brand camera (EOS T7 Ef-S 18-55 F / 3.5-5.6 Is II Digital Camera, Canon, Black). For the drug delivery of cosmetological assets, Skin Fill™ was used, a single-dose fluid - manufactured by Mezzo Dermocosméticos™ (São Paulo, Brazil), with TGF-Beta 3 growth nanofactor, EGF growth nanofactor, hyaluronic acid, and silicon in its composition. To reduce pain sensitivity, the topical anaesthetic Dermomax™, 40 mg/g, manufactured by Aché Laboratories™ (Pernambuco, Brazil), was used. Antiseptic soap (2% chlorhexidine gluconate) by Laboratory Rioquímica™ (São Paulo, Brazil), sterile gauze and saline were used to clean the area to which microneedling was applied.

### **Experimental protocol:**

The study was carried out after the volunteers signed the informed consent form and in accordance with the ethical guidelines of the Declaration of Helsinki.

The volunteers were distributed into 2 groups named G1 and G2. In G1, microneedling was performed without active ingredients (sterile saline), and in G2, the microneedling was performed in association with Cosmetic Skin Fill™ monodose fluid - manufactured by Mezzo Dermocosméticos™ (São Paulo, Brazil)<sup>14</sup>.

The volunteers received two treatment sessions with an interval of 30 days between them. The treatment was performed on the entire facial

region (full face), specifically covering the forehead (frontal), glabella, eye corners (“crow's feet”), upper and lower eyelid, zygomatic arch, orbicular region of the eyes and zygomatic bone, orbicular region of the mouth, mandible, nasogenian groove, and mentum.

To receive the procedure, the facial skin was cleaned with antiseptic soap, then a topical anaesthetic was applied, remaining on the skin for 30 minutes, and the excess was removed when necessary and after the end of this period. Then, the facial region was divided into sub-areas for greater precision of the microneedling action, which was applied with minimal manual pressure and short, fast movements, with an average of 6 to 8 application strokes in each of the four directions (horizontal, vertical, diagonal right and left). In each treated subarea, the local bleeding, when occurred, was cleaned with a sterile gauze soaked in saline. After the end of the microneedling procedure and cleaning the local bleeding, the placebo (saline) or cosmetic product was applied and massaged until its total absorption.

collaborators (2007)<sup>16</sup> were also applied. A 2D-photographic analysis was also performed, using Dolphin Imaging Brazil - Renovatio software, using parallel lines, angles for facial symmetry analysis, configuring a standardization of the facial image for tissue sagging analysis<sup>17, 18</sup> (Figure 1).

Figure 1A shows the nasolabial F-crease - frontal view, formed by the angle of two tangent lines between the labial commissure and the nasolabial crease, and its increase means that the crease has been repositioned to the medial region (“groove” decrease). Figure 1B shows L-cervical - cervical angle - lateral view, which consists of the angle formed by two lines, tangent to the upper and lower cervical projections, so that its increase indicates a decrease in sagging.

In the facial symmetry evaluation, figure 1C shows the measurement of the L-paralateronasal projection, which consists of the angle formed by two lines, tangent to the lateral nasal and nasolabial projections, indicating an increase in the paralateronasal projection (characterizing the filling in the nasal region), and the reduction indicates decreased sagging. Figure 1D consists of the angle of the lateral mandibular projection - frontal view, the angle being formed by two lines, tangent to the lateral and inferior projection of the zygomatic region, and its increase means the projection (less sagging) has decreased.

Figure 1E represents the lateral eyelid F-wrinkle - frontal view, formed by the angle composed by two tangent lines between the ocular corners and the lateral wrinkle, and the decrease means the wrinkle has been repositioned upwards (decreases sagging). Figure 1F shows the L-eyelid crease - side view, with the angle formed by two tangent lines being the lateral eyelid crease and the back of the nose, which means the crease has been repositioned upwards (decreased sagging)<sup>17,18</sup>.

Two volunteers were selected for the blepharoplasty surgical procedure, in which the eyelid flap was removed: one subject from G1 and one from G2. The removed skin was unblocked in paraffin for the preparation of slides and qualitative analysis by means of optical microscopy. The evaluations were carried out using haematoxylin and eosin (HE) 40x, 100x, 400x for the verification of dermal, epidermal and hypodermic tissue morphology. The analysed criteria were: presence of edema, acute and chronic inflammatory process, presence of

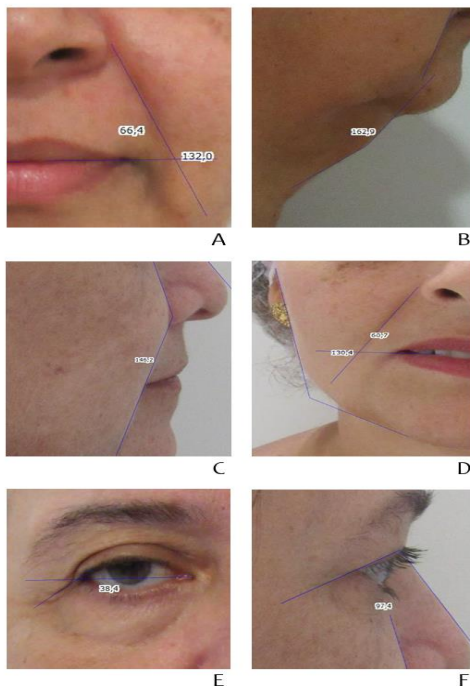


Figure 1: Photographic analysis of the length and angulation measurements of facial symmetry.

Result evaluation was performed in three stages: before treatment, 30 days after the 1st procedure (D30), and 30 days after the 2nd procedure (D60). The Narins15 Global Aesthetic Improvement Scale (GAIS) questionnaire and a satisfaction questionnaire adapted from Segot-Chicq and

fibroblasts, neocollagen and mature collagen, and type of present collagen. Histological analysis was performed with the two volunteers who underwent blepharoplasty (Figure 2). This material was used to check for inflammatory process, the presence of collagen, the types of collagen produced, and the growth factor.

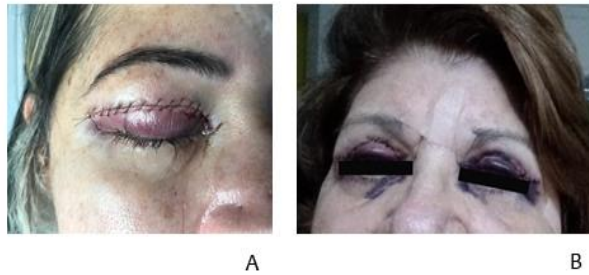


Figure2: A: Patient from G1 who underwent blepharoplasty surgery. B: Patient from G2 who und

**Data analysis:**

The descriptive and inferential statistics of the data were performed using the SPSS 22.0 program (Statistical Package for the Social Science - version 22.0). Data normality was observed through the Kolmogorov-Smirnov (KS) test. For comparisons of the measurements obtained in all evaluations (before, 30 and 60 days), the ANOVA test of repeated measurements with post hoc Bonferroni was applied. The level of significance was set at 95% ( $p < 0.05$ ).

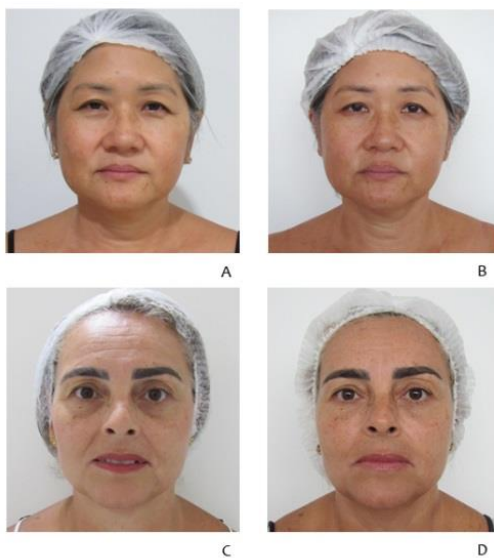

Figure3: A: Photo taken before the microneedling intervention (G1); B: Photo taken after the microneedling intervention (G1); C: Photo taken before the microneedling intervention (G2); D: Photo taken after the microneedling intervention (G2).

**Results:**

After all applications, 9 volunteers withdrew from the research and 21 volunteers remained until the end, out of which 12 from G1 and 9 from G2.

**Clinical Analysis of Photographs:**

Figure 3 shows the clinical results presented through photos.

**Analysis of facial symmetry using software:**

Figure 4 represents the results of the facial symmetry software analysis, which investigated the three analysed stages through different angles and lengths.

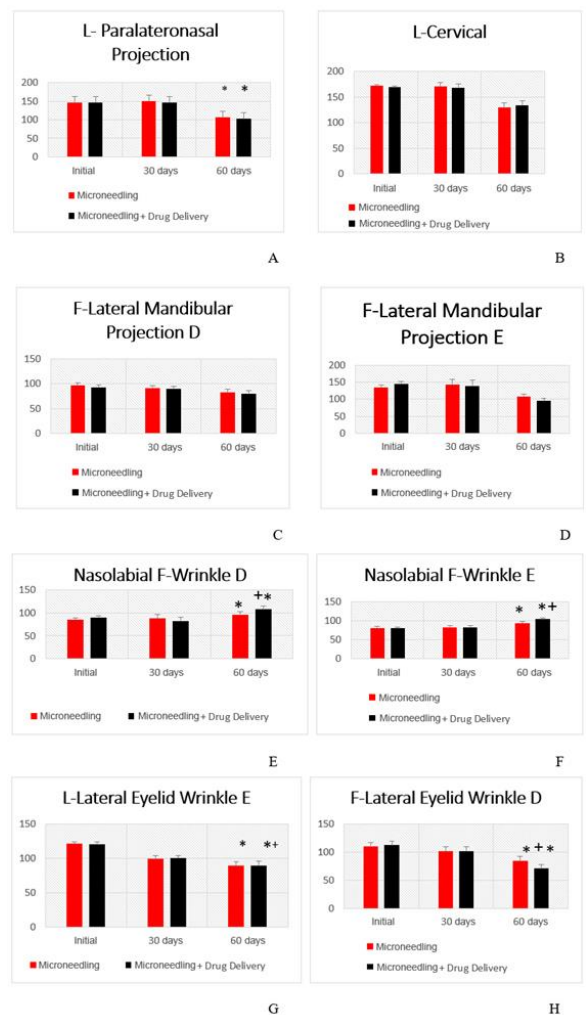


Figure4: Results of the analysis run by the facial symmetry assessment software, before and after the intervention.

\*Significant difference ( $p < 0.05$ ) when compared to the initial moment.

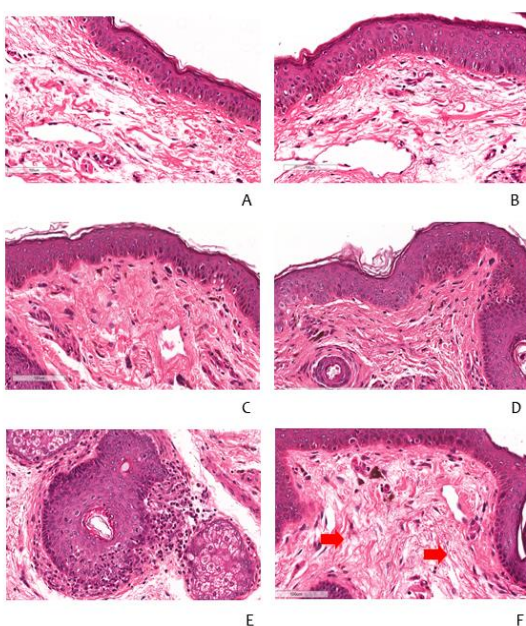
+ Significant difference ( $p < 0.05$ ) when comparing the microneedling group and microneedling drug delivery group.

The measures of the F- Lateral Mandibular Projection D, F Lateral Mandibular Projection E,

L-Cervical showed no significant difference in the initial evaluations compared to the final moment, as well as between the groups. In the evaluation of facial symmetry, the L- Paralateronasal Projection, showed a significant reduction of this measure 60 days from the initial intervention in G1 ( $p = 0.01$ ), and G2 ( $p = 0.02$ ). In the analysis of the right and left Nasolabial F-Wrinkle, there was a significant increase within both groups ( $p = 0.01$  for G1 and  $p = 0.02$  for G2), however there is a difference with a greater increase in G2 when compared to G1, with all differences verified in the analysis of the measurements made after 60 days. In the L-Lateral Eyelid Wrinkle analysis, right and left showed a significant increase in G2 ( $p = 0.01$  and  $p = 0.04$ ), when compared to G1 ( $p = 0.03$  and  $p = 0.01$ ), with all differences verified in the analysis of the measurements made after 60 days. In the analysis of the tracing of the L-Lateral eyelid wrinkle right there was a significant increase in the values of G2 ( $p = 0.03$ ) in comparison to G1 ( $p = 0.01$ ), with all differences noticed at 60 days.

**Qualitative and quantitative analysis of the skin fragment histological material:**

Figures 5 and 6 show the results of the histological analysis of the material removed in the blepharoplasty, in which the following were analysed: inflammatory process, presence of collagen, types of produced collagen, and the presence of growth factor.



Figures 5 and 6 show the results of the histological analysis

of the material removed in the blepharoplasty, in which the following were analysed: inflammatory process, presence of collagen, types of produced collagen, and the presence of growth factor.

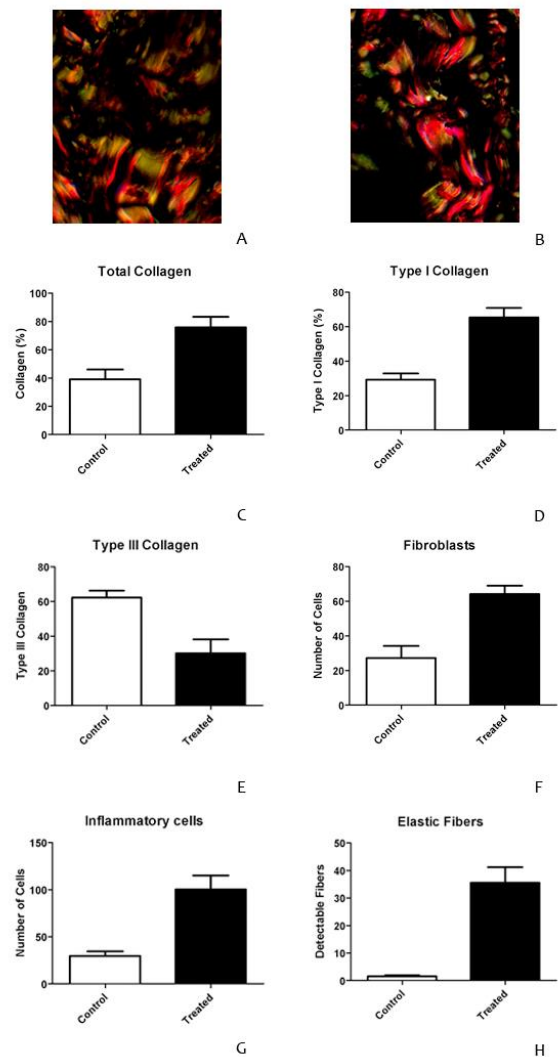


Figure 6: A: G1: predominant type III collagen (in green) B: G2: predominant type I collagen (in red) - greater quality and resistance. C: Amount of Collagen. D: Type I collagen. E: Type III collagen. F: Number of fibroblasts. G: Number of Inflammatory Cells. H: Detection and quantification of elastic fibres.

Figures 5A and 5B show G1 results. Very mild inflammation was found, with collagen formation in the treated region. However, with a characteristic of laxity. Figures 5C, 5D, 5E, and 5F, represent G2 after 30 days, with an increase in the number of fibroblasts and melanocytic activity. A concentration of dense collagen and an increase in the amount of elastic fibres was also observed. In figures 6A and 6B, G1 showed an increase in the amount of collagen, mainly of

type-I collagen. In Figures 6E, a predominance of type-III collagen in G1. Figures 6F, 6G, and 6H presented an increase in the amount of fibroblasts, inflammatory cells, and elastic fibres.

The microneedling treatment associated with drug delivery was able to induce neocollagenesis and proliferation of elastic fibres. An increase in the amount of type I collagen was verified, that is, collagen of greater resistance and quality. Perifollicular inflammation is directly associated to the formation of new collagen fibres and the proliferation of fibroblasts, as observed in the group treated with cosmetological actives. G2 also showed proliferation of melanocytes and accumulation of melanophages, which can cause clinically perceptible pigmentation.

#### **Analysis of adverse reaction and satisfaction questionnaires:**

In the analysis of the adverse reaction and satisfaction questionnaires, regarding hyperaemia (redness), G1 volunteers presented an incidence of 50.0%, whereas G2 had 66.6% of the volunteers reporting hyperaemia. The observed hyperaemia remained for a period of approximately 2 to 3 h after the procedure was performed. In both groups. In the analysis of satisfaction with the clinical results obtained, it can be observed that in G1, 16.7% reported skin texture improvement, while in G2, 88.8% reported texture improvement. Regarding the satisfaction with treatment, considering skin firmness, in both groups, an improvement of 100% was reported by the volunteers. Regarding the treatment concept description, the work was considered excellent by 58.3% of the G1 participants, and by 88.8% of the G2 participants.

#### **Discussion:**

The purpose of this study was to analyse the effects of microneedling associated or not with growth factors to improve the clinical and aesthetic aspect of wrinkles and, consequently, facial aging. The reduction of collagen characterized in wrinkles promotes a disorganization of connective tissue fibres<sup>15</sup>. It is suggested that microneedling promotes a cell activity increase with fibroblast-induced collagen production<sup>19</sup>. It has been described that when microneedling is applied in conjunction with growth factors present in topical cosmetics, different responses are observed. In general, an increase in the fibroblast activation and collagen

and elastin production increase, favour the reorganization of connective tissue, thus promoting a reduction in facial flaccidity<sup>20, 21</sup>. Some studies have been developed using cosmeceuticals to promote facial rejuvenation. There is a decrease in the speed of collagen and elastin degradation, so that the release of growth factors favours rejuvenation<sup>22</sup>. Products similar to those used in this study, based on growth factors, have become an important topical treatment modality to treat signs of skin aging, such as fine lines, deep wrinkles, dryness, sagging and skin texture irregularities. Another 12-week study aimed at dermal and epidermal restructuring of aged skin<sup>23</sup> used data from expert classification, corneometer, and cutometer evaluations, as well as 2D and 3D image analyses, and found significant improvements in appearance, firmness, elasticity and hydration of facial skin. The elements that improved most dramatically in the investigators' ratings include gloss, firmness, tactile elasticity, texture smoothness, overall appearance, and wrinkles. In this study, an improvement response in facial symmetry can be observed, indicating connective tissue remodelling caused by the induction of collagen, mainly after around 60 days. G2 volunteers showed a more intensified response than G1 individuals. It was observed that microneedling favours the penetration of active ingredients that induce collagen modulation and therefore, it favours joint tissue reorganization, stimulating better skin support, as well as the remodelling of the connective tissue<sup>24, 25</sup>.

The microneedling treatment with cosmetological actives was able to induce neocollagenesis and elastic fibre proliferation, and the treated skin showed an increase in the amount of type I collagen, that is, a collagen of greater resistance and quality. Perifollicular inflammation is directly associated to the formation of new collagen fibres and fibroblast proliferation, as observed within the individuals from the group treated with growth factors. Regarding histological analysis, greater amounts of collagen and elastic fibres were noticed when also associated to microneedling and growth factors. Among the components used in this study, the use of TGF-beta 3 growth factors, EGF factor are worth mentioning. The combination of the Silicon and hyaluronic acid effects promotes biochemical modulation of the connective tissue. The low molecular weight of

the hyaluronic acid promotes greater cohesion between cells and the synthesis of pro-collagen, which increases skin firmness. The TGF-beta 3 acts directly on the extracellular matrix, increasing the quality of basic fibroblast growth. Silicon has a stimulating effect on the collagen synthesis. The EGF factor favours re-epithelialization after the microneedling application, stimulating keratinocyte differentiation, promoting the replacement of injured tissue and favouring the deposition of granulation tissue, also reducing skin pigmentation and maintaining an inflammatory response<sup>10, 11, 22, 23, 24, 25, 26, 27</sup>. In the photographic analysis, it was observed that both groups showed some reduction in the expression of wrinkles and flaccidity; however, the group that used microneedling associated with drug delivery showed greater effect on the facial symmetry pattern. For the manifestation of these results, it is suggested that the association of growth factors may modulate the inflammatory response induced by microneedling, with greater fibroblast activity and collagen production, with tissue reorganization, minimizing the inflammatory response<sup>10,12</sup>. The presence of melanophages in the tissue of the treated group was observed in the histological analysis. This finding may have been evident due to an intense inflammatory response, as described by some authors<sup>26</sup>. Local hyperstimulation, generated by the association of microneedling and growth factors, can induce cellular activity increase, with intense epithelial and melanocytic activity<sup>27</sup>. Therefore, it is suggested that the combination of active ingredients in the appropriate concentration and formulation is chosen when using microneedling to minimize the risk of hyperchromic lesions caused by melanophage hyperactivity. Despite this histological finding, there were no cases of adverse hyperpigmentation reactions in the analysed group. Regarding other adverse reactions, all were controlled and expected as temporary hyperaemia, lasting from 1 to 3h, which is a common response after microneedling. Regarding patient satisfaction, the questionnaires showed satisfactory results regarding skin firmness in both groups; however, those from G2 showed improved upper skin texture, which can be indicative of a considerable increase in collagen production. The volunteers from G2 reported greater satisfaction, stating the treatment was excellent. These responses add to previous

observations of greater clinical improvement in patients who received the combination of interventions, indicating that there was reorganization and production of collagen in the connective tissue<sup>9, 28, 29</sup>. This study's limitation was the absence of use of additional equipment such as corneometers, cutometers, or ultrasounds to investigate the firmness and disposition of collagen fibres. It is suggested that further studies are carried out considering the use of such assessment instruments, as well as with new drug delivery combinations and a greater number of interventions.

### **Conclusion:**

The association of microneedling with growth factors promoted a greater production of collagen and elastic fibres, and a notable reorganization of the connective tissue, promoting clinical results with greater effect on facial rejuvenation when compared to the application of microneedling without cosmetological actives.

### **Declaration of Conflicting Interests:**

The author(s) declared no potential conflicts of interest with respect to the research, authorship, and/or publication of this article.

### **Funding:**

The author(s) received no financial support for the research, authorship, and/or publication of this article.

### **References:**

- [1] Agamia NF, Embaby MH, El-sheikh S. Comparative study between microneedling alone and microneedling combined with platelet-rich plasma in the treatment of striae distensae using clinical and histopathological assessment. *Journal of the Egyptian Women's Dermatologic Society*. 2016 13(3): 187-193.  
<https://www.ingentaconnect.com/content/wk/ewx/2016/00000013/00000003/art00012>
- [2] Contin LA. Alopecia androgeneética masculina tratada com microagulhamento isolado e associado a minoxidil. *Minoxidil injetável pela técnica de microinfusão de medicamentos pela pele. Surg. Cosmet. Dermatol.* 2016 8(2): 158-161.  
<http://www.surgicalcosmetic.org.br/detalhe-artigo/485>

- [3] Sharad J. Combination of microneedling and glycolic acid peels for the treatment of acne scars in dark skin. *Journal of Cosmetic Dermatology*. 2011 10(4): 317-323.  
<https://onlinelibrary.wiley.com/doi/abs/10.1111/j.1473-2165.2011.00583.x>
- [4] Lima AA, Souza TH, Grignoli LCE. Os benefícios do Microagulhamento no tratamento das disfunções estéticas. *Revista Científica da FHO*. 2015 13(1).
- [5] Dhurat R, Mathapati S. Response to microneedling treatment in men with androgenetic alopecia who failed to respond to conventional therapy. *Indian journal of dermatology*. 2015 May;60(3):260.  
<https://dx.doi.org/10.4103%2F0019-5154.156361>
- [6] Lima EVA, Lima MA, Takano D. Microagulhamento: estudo experimental de classificação da injúria provocada. *Surg Cosmet Dermatol*. 2013 5(2): 110-114.  
<https://www.redalyc.org/articulo.oa?id=265527948004>
- [7] Kim YC, Park JH, Prausnitz MR. Microneedles for drug and vaccine delivery. *Advanced drug delivery reviews*. 2012 Nov 1;64(14):1547-68.  
<https://www.sciencedirect.com/science/article/abs/pii/S0169409X12001251>
- [8] Gholami S, Mohebi MM, Hajizadeh-Saffar E, Ghanian MH, Zarkesh I, Baharvand H. Fabrication of microporous inorganic microneedles by centrifugal casting method for transdermal extraction and delivery. *International journal of pharmaceutics*. 2019 Mar 10;558:299-310.  
<https://www.sciencedirect.com/science/article/abs/pii/S0378517319300298>
- [9] Sasaki GH. Micro-needling depth penetration, presence of pigment particles, and fluorescein-stained platelets: clinical usage for aesthetic concerns. *Aesthetic surgery journal*. 2016 Aug 16;37(1):71-83.  
<https://academic.oup.com/asj/article/37/1/71/2705996?login=true>
- [10] Derynck R, Lindquist PB, Lee A, Wen D, Tamm J, Graycar JL, Rhee L, Mason AJ, Miller DA, Coffey RJ, et al. A new type of transforming growth factor-beta, TGF-beta 3. *EMBO J*. 1988 Dec 1;7(12):3737-43.  
<https://www.embopress.org/doi/abs/10.1002/j.1460-2075.1988.tb03257.x>
- [11] Rayego-Mateos S, Rodrigues-Diez R, Morgado-Pascual JL, Valentijn F, Valdivielso JM, Goldschmeding R, Ruiz-Ortega M. Role of Epidermal Growth Factor Receptor (EGFR) and Its Ligands in Kidney Inflammation and Damage. *Mediators Inflamm*. 2018 Dec 23;2018:8739473.  
<https://www.hindawi.com/journals/mi/2018/8739473/>
- [12] Barrientos S, Stojadinovic O, Golinko MS, Brem H, Tomic-Canic M. Growth factors and cytokines in wound healing. *Wound Repair Regen*. 2008 Sep-Oct;16(5):585-601.  
<https://onlinelibrary.wiley.com/doi/full/10.1111/j.1524-475X.2008.00410.x>
- [13] Kemp MG, Spandau DF, Travers JB. Impact of Age and Insulin-Like Growth Factor-1 on DNA Damage Responses in UV-Irradiated Human Skin. *Molecules*. 2017 Feb 26;22(3).  
<https://www.mdpi.com/1420-3049/22/3/356>
- [14] Mezzo - Fluido monodose - STRILL, Rio de Janeiro, p. 1, 1 dez. 2017.  
[https://www.tcimport.com.br/CONCEPT\\_STRILL\\_\\_Estrias\\_\\_Fluido\\_monodoseMEZZO/prod-4442738/](https://www.tcimport.com.br/CONCEPT_STRILL__Estrias__Fluido_monodoseMEZZO/prod-4442738/)
- [15] Narins RS, Brandt F, Leyden J, Lorenc ZP, Rubin M, Smith S. A randomized, double-blind, multicenter comparison of the efficacy and tolerability of restylane versus zyplast for the correction of nasolabial folds. *Dermatol Surg*. 2003 Jun;29(6):588-95.  
<https://onlinelibrary.wiley.com/doi/abs/10.1046/j.1524-4725.2003.29150.x>
- [16] Segot-Chicq E, Compan-Zaouati D, Wolkenstein P, Consoli S, Rodary C, Delvigne V, Guillou V, Poli F.



- Development and validation of a questionnaire to evaluate how a cosmetic product for oily skin is able to improve well-being in women. *J Eur Acad Dermatol Venereol*. 2007 Oct;21(9):1181-6.
- <https://onlinelibrary.wiley.com/doi/abs/10.1111/j.1468-3083.2007.02193.x>
- [17] Xia, James J., Jaime Gateno, and John F. Teichgraeber. New clinical protocol to evaluate craniomaxillofacial deformity and plan surgical correction. *Journal of Oral and Maxillofacial Surgery*. 2009; 67.10: 2093-2106.
- [https://www.joms.org/article/S0278-2391\(09\)00552-7/pdf](https://www.joms.org/article/S0278-2391(09)00552-7/pdf)
- [18] Bobek S, Farrell B, Choi C, Farrell B, Weimer K, Tucker M. Virtual surgical planning for orthognathic surgery using digital data transfer and an intraoral fiducial marker: the charlotte method. *J Oral Maxillofac Surg*. 2015 Jun;73(6):1143-58.
- <https://www.sciencedirect.com/science/article/abs/pii/S0278239114017996>
- [19] Aust MC, Fernandes D, Kolokythas P, Kaplan HM, Vogt PM. Percutaneous collagen induction thrapy: an alternative treatment for scars, wrinkles, and skin laxity. *Plast Reconstr Surg*. 2008;121(4):1421-9.
- [https://journals.lww.com/plasreconsurg/Fulltext/2008/04000/Laser\\_Resurfacing\\_of\\_Smallpox\\_Scars.46.aspx](https://journals.lww.com/plasreconsurg/Fulltext/2008/04000/Laser_Resurfacing_of_Smallpox_Scars.46.aspx)
- [20] Wermeling DP, Banks SL, Hudson DA. Et al. Microneedles permit transdermal delivery of skin-impermeant medication to humans. *PNAS*; 2008;12(105): 2058-63.
- <https://www.pnas.org/content/105/6/2058.short>
- [21] Kalil CLPV, Campos VB, Chaves CRP, Pitassi LHU, Cignachi S. Comparative, randomized, double-blind study of microneedling associated with drug delivery for rejuvenating the skin of the anterior thorax region. *Surg Cosmet Dermatol*. 2015;7(3):211-216.
- <http://www.surgicalcosmetic.org.br/detalhe-artigo/416/Comparative--randomized--double-blind-study-of-microneedling-associated-with-drug-delivery-for-rejuvenating-the-skin-of-the-anterior-thorax-region>
- [22] Baumann L How to Use Oral and Topical Cosmeceuticals to Prevent and Treat Skin Aging. *Facial Plast Surg Clin North Am*. 2018 Nov; 26(4):407-413.
- [https://www.facialplastic.theclinics.com/article/S1064-7406\(18\)30026-9/pdf](https://www.facialplastic.theclinics.com/article/S1064-7406(18)30026-9/pdf)
- [23] Barone F, Bashey S, Woodin Jr. FW. Clinical Evidence of Dermal and Epidermal Restructuring from a Biologically Active Growth Factor Serum for Skin Rejuvenation. *J Drugs Dermatol*. 2019 Mar 1;18(3):290-295.
- <https://jddonline.com/articles/dermatology/S1545961619P0290X>
- [24] Al-Qallaf B, Das DB. Optimizing Microneedle Arrays to Increase Skin Permeability for Transdermal Drug Delivery. *Ann New York Acad Sci*. 2009; 1161: 83-94
- <https://nyaspubs.onlinelibrary.wiley.com/doi/abs/10.1111/j.1749-6632.2009.04083.x>
- [25] Lee YB, Eun YS, Lee JH, Cheon MS, Park YG, Cho BK, Park HJ. Effects of topical application of growth factors followed by microneedle therapy in women with female pattern hair loss: a pilot study. *The Journal of dermatology*. 2013 Jan;40(1):81-3.
- <https://onlinelibrary.wiley.com/doi/abs/10.1111/j.1346-8138.2012.01680.x>
- [26] Rastrelli M, Tropea S, Rossi CR, Alaibac M. Melanoma: epidemiology, risk factors, pathogenesis, diagnosis and classification. *In Vivo*. 2014 Nov-Dec;28(6):1005-11.
- <https://iv.iiarjournals.org/content/28/6/1005.short>
- [27] Waddell A, Star P, Guitera P. Advances in the use of reflectance confocal microscopy in melanoma. *Melanoma Manag*. 2018 May 10;5(1):MMT04.
- [28] Lee K, Goudie MJ, Tebon P, Sun W, Luo Z, Lee J, Zhang S, Fetah K, Kim HJ, Xue Y, Darabi MA, Ahadian S, Sarikhani E,

Ryu W, Gu Z, Weiss PS, Dokmeci MR, Ashammakhi N, Khademhosseini A. Non-transdermal microneedles for advanced drug delivery. *Adv Drug Deliv Rev.* 2019 Dec 11. Pii: S0169-409X (19)30240-6.

<https://www.sciencedirect.com/science/article/abs/pii/S0169409X19302406>

- [29] Badran, M, Kuntsche, J, Fahr, A. Skin penetration enhancement by a microneedle device (Dermaroller®) in vitro: dependency on needle size and applied formulation. *Eur J Pharm Sci.* 2009; 36(4-5):511-23.

<https://www.sciencedirect.com/science/article/abs/pii/S0928098708004867>