

International Journal Of Medical Science And Clinical Inventions

Volume 2 issue 08 2015 page no. 1266-1274 ISSN: 2348-991X

Available Online At: <http://valleyinternational.net/index.php/our-jou/ijmsci>

Histopathological Effect Of Clomiphene On Testis .

Dr Rohul Afza MBBS, MS¹ , Dr Ashfaq Ul Hassan MBBS, MS², Dr Shazia Nazir MBBS³ , MD Prof Muzzafar . MBBS MS⁴

¹Senior Resident Department of Anatomy SKIMS Medical College Srinagar, India.

²Consultant Department of Anatomy SKIMS Medical College Srinagar, India.

³Senior Resident Department of Biochemistry SKIMS Medical College Srinagar, India.

⁴Ex Prof and Head . Anatomy GMC Srinagar

Corresponding Author : Dr Ashfaq ul Hassan

Head Department of Anatomy SKIMS Medical College Srinagar, India.

Email: ashhassan@rediffmail.com

Abstract:

Clomiphene is a commonly used drug . It is used for Multiple Purposes and the role of clomiphene is under investigation in more diseases. The effect of Clomiphene is not limited to the tissues only but serious side effects on long term use have been reported. The current study is aimed at determining the effects of Clomiphene on Testis. From time to time the experimental work has been carried out to study the effect of clomiphene on different reproductive organs. The present study was made to find out the actions of clomiphene in the male by providing observation on the influence of clomiphene on the microscopic structure of the male reproductive organs in sexually mature animals (rats). These include the stages of spermatogenesis affected in the testis.

Key words: *Clomiphene, seminiferous tubule, Hypothalamus,infertility, estrogen, estradiol*

Introduction

Clomiphene citrate is a synthetic analogue of the non-steroidal estrogen chlorotrianisene, 1-(p-(diethylaminoethoxy)-phenyl)-1, 2 diphenyl-2-chloro-ethylene. Clomiphene citrate, has a remarkable structural similarity to Estradiol which enables it to bind to estradiol receptors in various tissues such as the hypothalamus, hypothalamus cerebri, ovaries, uterus and cervix. However unlike estradiol, Clomiphene citrate is unable to induce the synthesis of new estradiol receptors, a process essential for the continuous binding of estradiol to the target cells as well as the expression of estrogenic action. The most commonly accepted simplistic view of

Clomiphene citrate action in the induction of ovulation is that it binds to the estradiol receptors in the hypothalamus to create a state of hypoestrogenicity, thereby causing an enhanced Gonadotropin-releasing hormone (GnRH) release followed by an increased secretion of gonadotropins which induces ovulation. The intrafollicular concentrations of Follicle stimulating hormone (FSH), Luteinizing hormone (LH), Estradiol and Androgens contribute to follicular growth.

Clomiphene is most widely used drug in the treatment of anovulatory infertility. Ovulatory disturbances are present in 15-25% of couples with infertility. Clomiphene has also been used in

conjunction with human gonadotropin and in vitro fertilization programmes. Clomiphene has been used in treatment of male infertility due to oligospermia to stimulate gonadotropin release and enhance spermatogenesis. For male infertility 25 mg daily given for 24 days in a month with 6 days rest for up to produced estrogenic action.

Clomiphene is commonly used by male anabolic steroid users to bind the estrogen receptors in their bodies, thereby blocking the effects of estrogen i.e., gynecomastia. It also restores the body's natural production of testosterone. It is commonly used as a "recovery drug" and taken toward the end of a steroid cycle.

Material and Methods

The present study was aimed to determine the effect of clomiphene citrate on reproductive organs of rats.

In the present study the experimental animals used were albino rats weighing on an average 150 gms. 64 healthy rats were used for the experimental study. The animals were studied in four groups.

GROUP A-(control group)-in this group 16 rats were used. These were fed with routine food and tap water daily.

In addition to the routine food and tap water 48 other rats were administered clomiphene citrate orally mixed with flour and water as pellets.

According to the dose the treated rats were classified into following groups-

GROUP B-It comprised of 16 rats and were administered .5 mg/ 100 gm daily.

GROUP C-It comprised of 16 rats and were administered 3.5 mg/ 100 mg daily.

GROUP D- It comprised of 16 rats and were administered 5 mg/ 100 gm daily.

Dose of the drug was calculated from human therapeutic dose. The animals were kept in four different cages comprising of group A,B,C and D.

Each day routine diet was prepared for animals in each group. The diet would comprise of different vegetables and gram. Each animal from the cage was taken out fed with its usual food. The group A animals had routine food whereas the group B,C and D animals in addition to routine food were fed with clomiphene citrate mixed with flour as pellets. The process of administration was continued up to twelve weeks regularly.

Four rats from each group were killed at intervals of 2,4,8 & 12 weeks respectively.

The tissues were processed manually for block making as follows:

S.NO	STEP	MEDIUM	TYPE
1	Fixation	10% Formaline	12 hrs
2	Dehydration	Acetone	12 hrs
3	Clearing	Benzene	6 hrs 3 changes at intervals of 2 hrs
4	Wax embedding	Paraffin wax at 56 degrees	3 hrs 3-4 changes

Observations:

The present study is aimed to observe the effects of clomiphene citrate on reproductive organs of male albino rats. In all 64 animals were used. These animals were grouped in various groups. Group A comprised the control group. Groups B,

C and D received drug. Groups were subdivided into subgroups on the basis of duration of treatment. Progressive decrease in rate of weight gain was observed in general (Chart No; 1). The organs namely, Testis, Epididymis, Seminal vesicles and Prostate of male albino rats were studied both macroscopically and microscopically.

Average body weight (in gms) of male albino rats

GROUP	BEFORE EXPERIMENTATION	AFTER EXPERIMENTATION			
		2 nd week	4 th week	8 th week	12 th week
A	150	198	259	328	350
B	145	150	162	170	183
C	148	155	160	168	172
D	148	150	158	162	170

For observation rats were grouped as given below:

GROUP	CONTROL	B	C	D
DOSAGE	NORMAL LAB DIET	2.5 mg/ 100 gms/ day	3.5 mg/ 100 gms/ day	5 mg/ 100 gms/ day
NO OF MALE ALBINO RATS	16	16	16	16

GROUPS	SUBGROUPS ON THE BASIS OF DURATION OF TREATMENT			
	2 nd week	4 th week	8 th week	12 th week
A	A1	A2	A3	A4
B	B1	B2	B3	B4
C	C1	C2	C3	C4
D	D1	D2	D3	D4

On gross examination, testes were oval shaped and brown in colour and were soft in consistency in all groups. A slight to moderate decrease in weight of testis was noticed from 4th and 12th weeks of experiment

Chart showing average weights (in mgs) of testis

GROUP	SUBGROUPS	TIME WEEKS	TESTIS mgs/ 100 gm B.W
A	A1	2	54
	A2	4	52
	A3	8	50
	A4	12	50
B	B1	2	53
	B2	4	49
	B3	8	45
	B4	12	40
C	C1	2	50
	C2	4	44
	C3	8	40
	C4	12	28
D	D1	2	48
	D2	4	43
	D3	8	39
	D4	12	20

MICROSCOPIC

GROUP B; in this group rats were administered the lowest dose of clomiphene, 2.5 mg/100/ day. Microscopic changes in the testis appeared after eight weeks (B3) of treatment in this group.

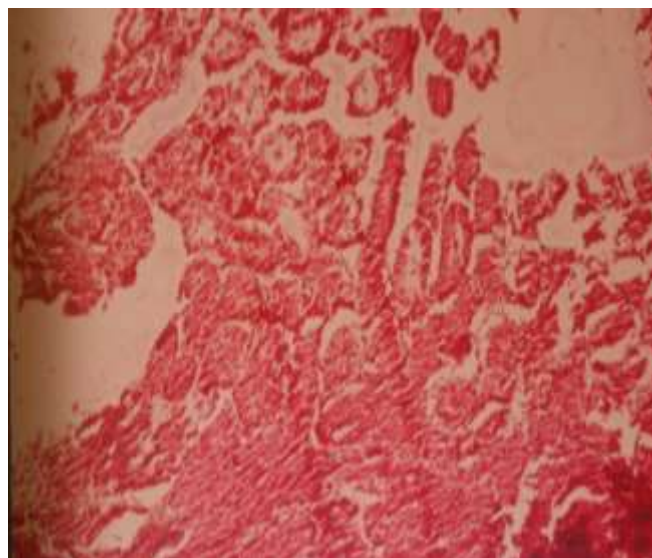


Fig 1 : Microscopic structure of Normal testis Lower Magnification

B1; Seminiferous tubules contain sertoli cells and germ cells in different stages of development, including spermatogonia, spermatocytes, and may types of spermatids. No obvious change seen. (Fig.2)

B2; Findings same as B1. No changes observed in this group also (Fig. 2)

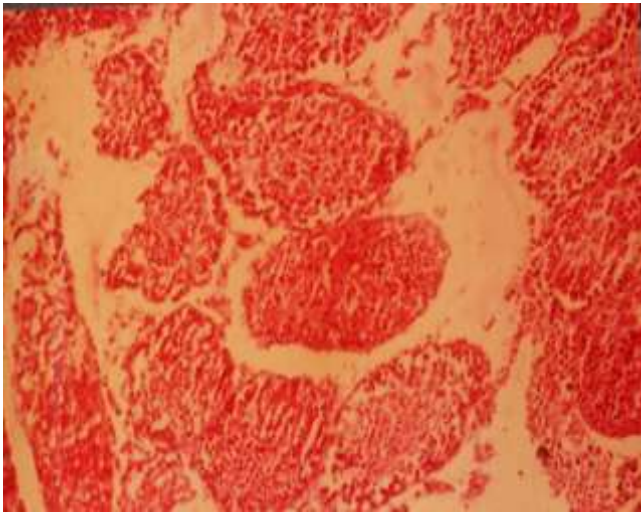


Fig2: Micrograph of Testis of Rat in Group B1 Showing Seminiferous Tubules containing Different stages of germ Cells . Higher Magnification

B3; Sperms were absent. Late spermatids decreased in number and in some specimens they appeared to be completely absent. Early stages of germ cells were not affected. (Fig 4)

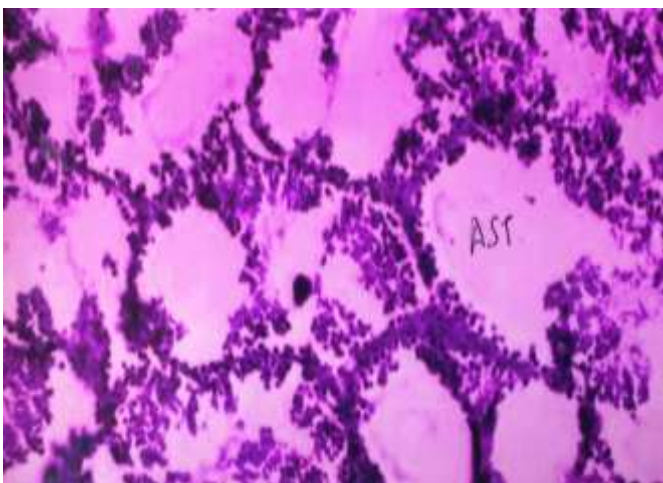


Fig4 : Micrograph of Testis of Rat in Group D3 Showing Atrophic Seminiferous Tubules.

B4; More extensive alterations were seen in this group in which early stages of germ cells were affected as well as late stages in the form of

decreased spermatogonia, primary spermatocytes and early spermatids.

GROUP C; In this group rats were administered the intermediate dose of clomiphene, 3.5mg/100/day. Microscopic changes were present in the majority of treated animals at eight week interval (C3) and in all of those treated for 12 weeks (C4).

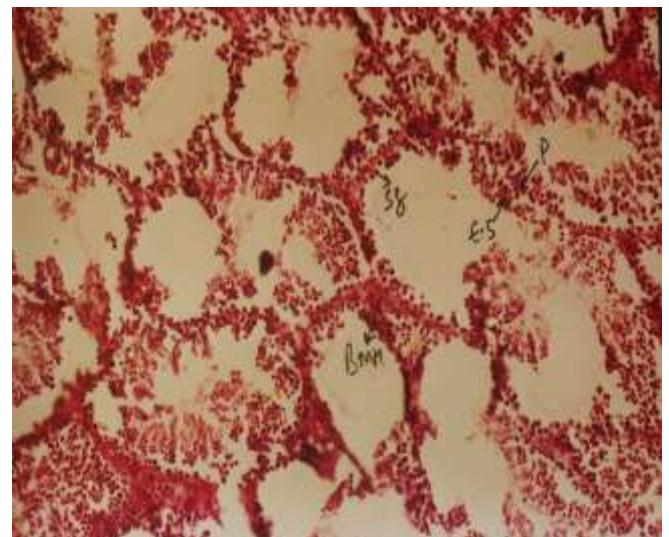


Fig3 : Micrograph of Testis of Rat in Group C4 Showing Seminiferous Tubules containing decreased sperms with basal membrane hyperplasia .

C1; Seminiferous tubules contain germ cells in different stages of development. No change from normal detected.

C2; Findings same as C1. No obvious change seen.

C3; Late spermatids were greatly decreased in number, and in some specimens they appeared to be completely absent. Early spermatids, spermatocytes and spermatogonia were abundant.

C4; More extensive alterations were seen in this group in which early stages of germ cells were

affected as well as late stages in the form of decreased spermatogonia, primary spermatocytes and early spermatids. Some degenerating primary spermatocytes were also seen. Basement membrane hyperplasia was seen in some tubules.

GROUP D; In this group rats were administered the highest dose of clomiphene, 5mg/100/day, Microscopic changes were present in most of the treated rats.

D1; Seminiferous tubules contain germ cells in different stages of development. Spermatogonia, spermatocytes and early spermatids were present but late spermatids with condensed nuclei were decreased.

D2; Late spermatids decreased in number and in some specimens they appeared to be completely absent. Early stages of germ cells were slightly affected.

D3; More extensive alterations were seen in this group in which many atrophic seminiferous tubules are seen in which early stages of germ cells primary spermatocytes and early spermatids.

D4; Changes were more pronounced. Completely atrophied seminiferous tubules were seen. Germ cells were scarce, the only possible representatives of the germ cell line being a few round or oval cells which lay next to the basal lamina and thus may have been spermatogonia. Basement membrane hyperplasia was seen in some tubules. Degenerating cells were rarely observed, possibly because most of the germ cell population had undergone necrosis at an earlier time

Discussion

The present study was conducted on 64 albino rats and divided into various groups. Group A served

as control and these animals were fed with normal laboratory food with plain water as drinking fluid. The animals of each group were sacrificed at intervals of 2,4,8 and 12 weeks respectively. The aim was to observe the gross and histological changes, if any on Testis.. For microscopic study the slides were stained with haematoxylin and eosin.

Weight of animal

It has been considered in the present experimental work. Before experimentation the average weight of group A,B,C and D was 15, 145, 148 and 140 gms respectively and at the completion of 12 weeks was 350, 183, 172 and 170 gms respectively. This was indicative of progressive decrease in rate of weight gain of animals, possibly due to degenerative changes in reproductive organs.

Holtkamp ¹ observed dose related progressive decrease in rate of body weight gain. Rats receiving the highest dose of 7mg/100mgs/day gained 33 gms in weight while control animals gained 65 mgs.

Similar effects were also observed by Charles Flickinger ²They found that with increase in dose and duration of drug intake there was progressive decrease in rate of body weight gain. Rats receiving the highest dose of 5 mgs/ 100gms/ day for 12 weeks gained 20 gms in weight while control animals gained 100 mgs.

TESTIS

In the present study the effects of clomiphene citrate at therapeutic dosage were studied on the gross and histological structure of testis of albino rat.

Mild decrease in weight of Testis was noticed from 4th and 8th weeks of clomiphene therapy followed by gross decrease in weight from 8th to 12th weeks.¹

Histologically, in rats treated with clomiphene for up to eight weeks, it revealed diminution in late spermatids suggesting that germ cells developed up to approximately stages 6-7 of spermiogenesis and then underwent degeneration. In rats treated for 12 weeks more extensive changes in form of degenerating primary spermatocytes or even absence of spermatocytes suggest that with prolonged treated earlier stages of germ cells are affected and also degenerate. Since it was not possible to identify the stage of all the necrotic cells, some degeneration of spermatocytes might have occurred in animals treated for less than 12 weeks. Furthermore, the methods used in the present study did not include a quantitative analysis of the different types of germ cells remaining, so even though alterations in early stages of germ cells were not detected in most of the specimens, alterations in their numbers may have occurred.

Holtkamp demonstrated that in immature male rats clomiphene in dose from 1mg/kg/day and greater yielded lower relative weights of testis. Degree of lowering was dose dependent. Spermatogenesis was altered.

W.O.Nelson ³ observed weights of testis were decreased at all doses above 0.25mg/ kg and were at hypophysectomy levels at doses of 2.5mg/ kg and higher. Spermatogenesis halted at the early spermatid stage.

PAULSON D. ⁴ observed clomiphene at a dose level 50mg daily stimulated spermatogenesis while higher doses of 200-400 mg daily depressed spermatogenesis. Testicular biopsy in these men

demonstrated that clomiphene citrate at all dose levels produced reduction of testicular mass with concomitant mild hyalinization of tubular membranes. All cell types were present at each dose level of clomiphene administration. However upto 60% of spermatids were damaged in subjects whose sperm counts decreased. The histology of the germinal epithelium returned to normal after discontinuing the clomiphene citrate trials.

Charles. observed the weights of the testis were less than those of control animals at longer intervals of treatment. Microscopic alterations in the testis included a scarcity or even absence of late spermatids, the presence of necrotic cap-phase spermatids and accumulation of lipid droplets and large lysosome like structures in Sertoli cells. In rats treated for the longest interval, 12 wks, testicular changes were even more extensive; degenerating primary spermatocytes were observed and in one rat germ cells were virtually completely absent and seminiferous tubules were occupied by sertoli cells. The Leydig cells of treated animals were smaller than those of normal or control rats.

SINGH S.K ⁵ observed that the drug produced significant reduction in testicular weight with severe degenerative changes in seminiferous tubules in testis of musk shrew. Leydig cells were also atrophied.

Balasubramanian ⁶ observed that when clomiphene citrate was administered to immature male mice, it resulted in initial increase in testicular size with subsequent shrinkage. Histology of the testis revealed normal spermatogenesis by 30 days post treatment but arrest in spermatogenesis was evident by 60 days post treatment.

The testicular changes following clomiphene administration in the present study resemble the effects of hypophysectomy in the rat, in which both spermatids and primary spermatocytes underwent degeneration [Clermont and Morgentaler]⁷. The similarity between the effects of clomiphene and hypophysectomy on the seminiferous tubules, and the observed decrease in size of Leydig cells in clomiphene treated rats are both in accord with the reported action of clomiphene in suppressing gonadotropin secretion by the pituitary gland in male rats [Kalra]⁸

The alterations in the seminiferous epithelium and probably the result of an insufficient supply of testosterone, because decreased stimulation of Leydig cells by LH causes a decline in their size and secretion of testosterone, which normally acts on the seminiferous tubules to play a role in maintenance of spermatogenesis Steinberger⁹. In all these instances cap-phase spermatids degenerated and late spermatids were reduced or absent.

The similarities between the effects of clomiphene and of other antifertility agents on the testis might be explained in the following way. Progestins decrease gonadotrophin secretion and thus could cause effects similar to those of the non steroidal compound clomiphene. Cyproterone acetate could produce similar changes because it competes with testosterone for receptors in target cells and reduces androgen stimulation of the reproductive organs and it also has some progestational side activity Steinbeck⁹

The extensive alterations in the seminiferous epithelium of rats treated with clomiphene for 12 weeks, including the degeneration and loss of primary spermatocytes, were not observed following treatment with cyproterone acetate Loving¹⁰, progestin, or progestin and testosterone

[, in which degeneration of germ cells appeared to be confined to cap-phase and later spermatids. However, degeneration of spermatocytes did occur after hypophysectomy. In addition, a light microscopic study of the influence of different doses of clomiphene on the testes of immature rats showed that as the animals matured spermatogenesis was arrested at the early spermatid stages with low doses but with higher doses of clomiphene or in the presence of estrogen, spermatogenesis was arrested at the stage of primary spermatocytes. Therefore, the nature of the changes in germ cells may be a function of the degree of suppression of gonadotropin release and the length of treatment.

In the present study the changes in the testes of animals treated for up to eight weeks with any of the doses of clomiphene, were similar. In testes of rats treated with clomiphene for 12 weeks more extensive alterations were observed. Thus it is concluded that the testis manifests both gross and are more evident after the 12th week of clomiphene therapy.

Conclusion:

Long term effects show extensive degeneration and loss of primary spermatocyte. spermatogenesis was arrested at the early spermatid and the degree of suppression of gonadotropin release and the length of treatment is responsible for severe changes. And that the testis manifests macroscopic as well as microscopic changes.

References:

1. HOLTKAMP, D.E. ,J. G. GRESLIN. ,C.A. ROOT and L.J.LERNER[1960]; Gonadotropin inhibiting and antifecundity effects of clomiphene. Proc. soc. exp. Biol., N.Y., 105; 197-201.

2. CHARLES. J. FLICKINGER [1977]; Effect of clomiphene on the structure of the Testis, Epididymis and sex accessory glands of the rat. AM. J. ANAT., 149; 533-562.
3. NELSON, W. O., and D. J. PATANELLI [1962]; Effect of clomiphene on testis and pituitaries of male rats. fed. proc., 21; 437.
4. PAULSON, D. F., and J. WACKSMAN [1976]; Clomiphene citrate in management of male infertility J. UROL. 115; 73-76.
5. SINGH SK [1983]; Effect of clomiphene citrate on the testis, epididymis and accessory sex glands of the musk shrew (*Suncus murinus* L.).Ann Endocrinol, 44(2):131-8.
6. BARDIN, C.W.,G.T.ROSS and M.B.LIPSETT (1967); Site of action of clomiphene citrate in men; A study of the pituitary-leyding cell axis.J.CLIN.ENDOCR.,27;1558-1564.
7. CLERMONT, Y., and H. MORGENTALER [1955]; Quantitative study of spermatogenesis in the hypophysectomized rat. Endocrinology, 57; 369-38
8. . KALRA, S. P and M. R .PRASAD [1967] a; Effect of clomiphene on fertility in male rats. J. REPROD_ FERTIL 14; 39-48.
9. STEINBECK, II., M. MEI IRING and F. NEUMANN [1971]; Comparison of the effects of cyproterone, cyproterone acetate and oestadiol on testicular function, accessory sexual glands and fertility in a long term study on rats. J. Reprod. Fert, 26; 65-76.