

## “Management Of Fractures Of Patella Olecranon, Malleoli By Tension Band Wiring Method”

Dr. Karra Bansilal M.S.Ortho<sup>1</sup>, Dr. Srujith Kommera M.S.Ortho<sup>2</sup>

Asst. Professor, Dept. Of Orthopaedics, Government Medical College, Nizamabad, Telangana, India.

Senior resident, Dept. Of Orthopaedics, Government Medical College, Nizamabad, India.

**ABSTRACT:** Fractures of the eccentrically loaded bones like patella, olecranon and medial malleolus are one of the most common fractures encountered by an orthopaedic surgeon, with better operative techniques, internal fixation of these fractures with tension band wiring has become an accepted mode of treatment with its matching outcome results enabling the patient to smoothly resume his work without hampering his day-to-day life. Internal fixation of fractures hastens healing and rehabilitation. It also allows for early mobilization of the joint thereby preventing stiffness of joints and other complications related to immobilization. The aim of the study is to prove tension band wiring is a simple, inexpensive technique and effective means of fixing fracture based on biomechanical principle with minimum complications. Fifty cases of fractures were treated with tension band wiring, which comprised of fracture patella 20 cases, fracture olecranon 15 cases and medial malleolus 15 cases. Operated during period of 2013 to 2015. About 96% of fractures had united after 12 weeks. One case of wire migration was noted and superficial infection in one case who was a diabetic patient. In present study, there were 50% excellent, 32% good, 14% fair and 4% poor results.

**Keywords:** Tension Band Wiring, Olecranon, Patella, Malleoli.

**INTRODUCTION:** Fractures of the eccentrically loaded bones like patella, olecranon and medial malleolus are one of the most common fractures encountered by an orthopaedic surgeon. They continue to pose vexing problems as these being intraarticular are being subjected to continuous deforming forces from muscles. It is also difficult to restore the desired anatomical continuity and congruity of their articular surfaces after reduction and thereby causing complications like early onset of arthritis, stiffness of joints, non-union etc<sup>13</sup>. Hence, with better operative techniques, internal fixation of these fractures with tension band wiring has become an accepted mode of treatment with its matching outcome results enabling the patient to smoothly resume his work without hampering his day-to-day life. Internal fixation of fractures hastens healing and rehabilitation<sup>14</sup>. It also allows for early mobilization of the joint thereby preventing stiffness of joints and other complications related to immobilization.

### AIMS AND OBJECTIVES:

1. To clinically evaluate results of tension band wiring technique.
2. To compare the results of my study with the work reported till now

### PRINCIPLES OF TENSION BAND WIRING<sup>1</sup>

The tension band technique converts a tensile force into a compressive force. This enables improved fracture healing, as stability is improved when tensile forces are reduced at the fracture site. Tension banding is particularly useful in the setting of fractures where a muscle pull produces distraction of the fracture fragments, such as fractures of the patella, olecranon, greater tuberosity of the humerus, or greater trochanter of the femur and medial malleolus<sup>10</sup>. Tension bands can enable immediate motion at the involved joint, which allows for an improved functional outcome.

### Biomechanic principles<sup>3</sup>:

Biomechanic principles Tension banding is a principle and not a particular implant. To apply an implant with a tension band technique, a device is fixed eccentrically to the convex side of the fractured bone (fig1). Since a curved structure has a compression side and a tension side when an axial load is applied, the device on tension side neutralizes the forces under an axial load. The essential prerequisite is, there must be cortical contact on the compressive side, which is the side opposite to the implant. If there is a cortical defect or comminution on the compressive side, the implant will undergo bending stress and be subjected to early fatigue failure. A tension band can produce compression statically or dynamically<sup>6</sup>. If a tension band produces fairly constant force at the fracture site during motion, such as at the medial malleolus, it is called a STATIC TENSION BAND. Conversely, if the compression increases with motion, such as in the patella with knee flexion, the tension band is called DYNAMIC<sup>5</sup>.

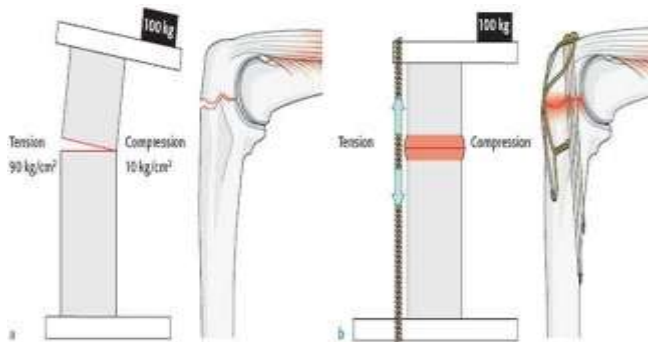


Fig. 1: Tension band principle

**Key concepts:**

The following prerequisites are essential:

1. There must be intact cortical contact on the side opposite the tension band.
2. The fixation must be able to withstand tensile force.
3. The bone or fracture pattern must be able to withstand compressive force.

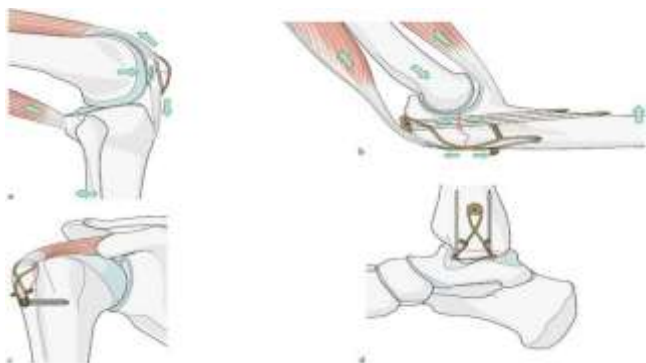


Fig. 2: Tension band applied at various sites

**Advantages of Tension Band Wiring<sup>4</sup>:**

It is inexpensive and effective method of internal fixation. Less cumbersome good patient compliance, early mobilization of the joint is possible. Maintains the approximate continuity of the bone without affecting the healing process even after the joint is mobilized.

**CLASSIFICATIONS:**

**OLECRANON**

**Depending on amount of articular surface involvement**

- Type 1: Fracture involves the proximal third of the articular surface.  
 Type 2: Fracture involves the middle third.  
 Type 3: Fracture involves the distal third.

**Colton's Classification**

This reflects displacement and the shape of fracture.

- A). Non-displaced and stable (less than 2 mm of displacement and no change in position with gentle flexion to 90 degrees.  
 B).

- Displaced
- Avulsion
- Transverse fracture
- Comminuted fracture
- Fracture dislocation

**Muller's Classification (AO/ASIF)**

- Transverse fracture opposite to deepest part of trochlear notch.
- Oblique fracture running distally from midpoint of trochlear notch.
- Comminuted fracture.
- Fracture olecranon associated with other injuries around the elbow.

**PATELLA**

**Orthopaedic trauma association classification**

- 1. Non-displaced:**
  1. Transverse
  2. Stellate
  3. Vertical
- 2. Displaced:**
  1. Transverse
  2. Stellate
  3. Polar –Proximal and Distal
- 3. Osteochondral**

**AO Classification**

- A: Patella extra-articular.  
 A1: Patella extra-articular avulsion.  
 A2: Patella extra-articular, isolated body.  
  
 B: Partial articular, extensor mechanism intact.  
 B1: Partial articular vertical, lateral
  1. Simple
  2. Multifragmentary
 B2: Partial articular, vertical, medial
  1. Simple
  2. Multifragmentary
 B3: Partial articular, multifragmentary.  
  
 C: Complete articular, disrupted extensor mechanism.  
 C1: Complete articular, transverse
  1. Middle
  2. Proximal
  3. Distal
 C2: Complete articular, transverse plus two fragments
  1. Middle
  2. Proximal
  3. Distal
 C3: Complete articular, complex
  1. 3 fragments
  2. >3 fragments
  3. Non-Reconstructible

**Displaced fractures:** It is defined displaced, if fractures fragment separation is more than 3 mm or an articular incongruity of 2 mm or more.

**Multifragmented fractures** (Stellate fracture) result from direct compression with varying degrees of comminution and displacement.

**Unusual fracture patterns:** Kroner first described osteochondral fractures, which are usually seen in patients 15 to 20 years of age. These fractures involve either the medial facet of patella or lateral femoral condyle after subluxation or dislocation of patella.

## ANKLE FRACTURES

### 1. Lauge-Hansen Classification

#### A. Supination-Adduction

1. Transverse avulsion type fracture of the fibula
2. Vertical fracture of the medial malleolus.

#### B. Supination-Eversion (External Rotation)

1. Disruption of the anterior tibiofibular ligament.
2. Spiral oblique fracture of the distal fibula.
3. Disruption of the posterior tibiofibular ligament or fracture of the posterior malleolus.
4. Fracture of the medial malleolus or rupture of the deltoid ligament.

#### C. Pronation-Abduction

1. Transverse fracture of the medial malleolus or rupture of the deltoid ligament.
2. Rupture of the syndesmotomous ligaments or avulsion fracture of their insertions.
3. Short, horizontal, oblique fracture of the fibula above the level of the joint.

#### D. Pronation eversion (External rotation) (PER)

1. Transverse fracture of the medial malleolus or disruption of the deltoid ligament.
2. Disruption of the anterior tibiofibular ligament.
3. Short oblique fracture of the fibula above the level of the joint.
4. Rupture of posterior tibiofibular ligament or avulsion fracture of the posterolateral tibia.

#### E. Pronation dorsiflexion (PD)

1. Fracture of the medial malleolus.
2. Fracture of the anterior margin of tibia.
3. Supramalleolar fracture of the fibula.
4. Transverse fracture of the posterior tibial surface.

### Denis Weber Classification:

This is based on the position and appearance of fibular fracture.

Type A: Fracture of the fibula below the level of tibial plafond.

Type B: Oblique fracture of the lateral malleolus.

Type C:

C1: Oblique fracture of the fibula proximal to the disrupted tibiofibular ligament

C2: More proximal fibular fracture with extensive disruption of the interosseous membrane.

### Handerson's radiological classification:

- a. Isolated fracture of lateral, medial, anterior or posterior malleolus.
- b. Bimalleolar fractures.
- c. Trimalleolar fractures

### Ashhurst and Bromer classification:

- a. Fracture caused by external rotation
- b. Abduction fracture
- c. Adduction fracture
- d. Axial rotation fracture

## OPERATIVE TECHNIQUE

### Anaesthesia

Spinal anaesthesia was given for surgery of patellar and malleolar fracture.

Regional block or general anaesthesia for surgery of olecranon fracture was given considering patient's condition.

### Patient positioning

Patient was positioned supine in patella fractures.

Lateral side in malleolar and olecranon fractures.

### Tourniquet

Pneumatic tourniquet was applied to arm after exsanguination for olecranon fracture and to thigh in patellar and malleolar fracture.

### Painting and draping

Affected part was scrubbed, painted and draped.

## MANAGEMENT OF PATELLA FRACTURES<sup>9</sup>:

It is based on the type of fracture.

### The goals of treatment are:

1. Preserve the patella function.
2. Restore continuity of extensor mechanism
3. Reduce complications associated with articular surface.

### Treatment options include:

1. **Non-operative treatment:** It is indicated for
  - a. Undisplaced fractures with an intact extensor mechanism.
  - b. Fragment displacement less than 3 mm or articular displacement more than 2mm
  - c. A cylinder cast is applied with knee in extension from groin to just above ankle.
2. **Operative treatment:** It is indicated for:
  - a. Displaced fractures for more than 3 mm separation of fragments.
  - b. Articular displacement more than 2 mm.
  - c. Comminuted fractures.

- d. Osteochondral fracture with displacement of loose body in the joint.
- e. Open fractures

#### OPERATIVE TECHNIQUE:

A midline longitudinal incision approximately 12.5 cms long was taken. The skin and subcutaneous tissue were reflected medially and laterally to expose the anterior surface of patella.

Fracture surfaces were cleaned of blood clot and small fragments. Thorough lavage was given. Fracture fragments were reduced anatomically with towel clips or bone holding forceps restoring smooth articular surface.

2 mm Kirschner wires were drilled from inferior to superior parallel to each other. These wires were placed 5 mm deep to anterior surface and protruding beyond the patella and quadriceps tendon attachments to the inferior and superior fragments.

An 18-gauge stainless steel wire was passed transversely through the quadriceps tendon attachment deep to the protruding Kirschner wires. Then over the anterior surface of patella, then transversely through patellar tendon attachment on the inferior fragment and deep to the protruding Kirschner wires, then back over the anterior surface and tightened at upper end. The reduction was checked by palpating the under surface of patella. The upper ends of the two Kirschner wires were bent anteriorly and cut short and rotated embedding posteriorly.

#### Types of patellar fixation

##### 1. Circumferential wire loop fixation

A wire loop is threaded through the soft tissues around the patella. Rigid fixation is not achieved and hence it is largely been replaced by more rigid fixation techniques to permit early motion of the joint.

##### 2. Magnusson wiring

Two holes are made through the proximal fragments beginning at the medial or lateral borders of the quadriceps tendon and directed obliquely downwards to open on the fracture surface. Two holes in the distal fragment are drilled and their apertures are faced opposite to those of the proximal fragment. Stainless steel wire is threaded distally through the medial holes and then proximally through the lateral holes. After opposing the fragments the ends of the wire are drawn taut and twisted together.

##### 3. Tension band wiring

Here two sets of wires are used, one passed transversely through the insertion of quadriceps tendon immediately adjacent to the superior pole then passing anteriorly over the superficial surface of patella and in a similar way through the insertion of patellar tendon. The wire is tightened until the fracture is slightly over corrected or opened on the articular surface. The second wire is passed through transverse holes drilled in the superior and inferior poles of the anterior patellar surface and tightened.

##### 4. Modified tension band wiring

Two Kirschners wires are drilled from the inferior to superior poles through each fragment as parallel as possible. 18-gauge wire is passed transversely through the quadriceps tendon attachment deep beneath the protruding Kirschner wires, then over the anterior surface of the reduced patella,

then transversely through the patellar tendon attachment on the inferior fragment and deep beneath the protruding Kirschner wires, then back over the anterior patellar surface and then tightened at the upper end.

Alternatively, the wire can be placed in the figure of eight fashion.

##### 5. Lotke longitudinal anterior band wiring

A steel wire is passed through a hole drilled on the medial side of each fragment passing at the lower border and then through a hole drilled on the lateral side and tightened at the upper hole.

##### 6. Partial patellectomy:

Indicated when there is severe comminution of one pole that is not amenable to internal fixation.

##### 7. Total patellectomy:

Recommended for highly displaced, comminuted patella fracture, where reconstruction of patellar surface is not possible and those fractures that are not amenable to internal fixation.

#### After treatment

The limb was placed in extension in a posterior splint. Isometric exercises were started on first postoperative day. Check dressing was done on 2nd postoperative day to know condition of operative wound. Following dressing, check x-ray in AP and lateral views were done. Active exercises were started after 2 weeks when wound was healed. Suture removal was done on twelfth postoperative day. Weight bearing was started after 6 weeks.

#### Complications of patellar fractures:

1. Fracture fragment separation and dehiscence of the fracture repair are uncommon. They generally result from either inadequate internal fixation or, in some cases, an inadequate period of postoperative joint support. Nummi reported a 7.4% incidence of late displacement after treatment of patellar fractures by closed methods. He noted an 11% incidence of loss of fragment position after osteosynthesis

2. Refractures are rare in nearly all series; the incidence varies from less than 1% to 5%. The trauma responsible for refracture is usually minimal. Treatment must be individualized to the patient. Repeat osteosynthesis may be necessary for moderate displacement and extensor mechanism insufficiency.

3. Avuncular necrosis is reported by most authors to be rare; however, Scapinelli reviewed 162 transverse fractures of which 41 showed partial evidence of necrosis; 38 of these involved the proximal fragment. Treatment consists of observation only. Patients usually regain full knee function within 6 to 8 months, and varying degrees of patellofemoral arthritis usually develop. Revascularization usually occurs spontaneously within 2 years.

4. Patellofemoral pain or osteoarthritic symptoms may develop as late sequelae of patellar fracture. Nummi reported a long-term incidence of patellofemoral arthritis of 56.4% in more than 700 fractures. Conservative

management of patellofemoral joint pain using non-steroidal anti-inflammatory agents and physical therapy is the mainstay of treatment. Under certain circumstances, the anterior tibial tubercle advancement advocated by Maquet may provide resolution of symptoms and improved extensor mechanism function; this is usually indicated in young patients with intractable knee pain.

5. Postoperative wound infection is managed by debridement and evaluation of the stability of the fixation. Wound infection with stable fixation and viable bone fragments is treated by debridement, irrigation, and closure over drains with intravenous antibiotics. Persistent infection in the presence of devitalized bone fragments requires excision of nonviable bone and plastic repair of the extensor mechanism. Any exposure of the knee articular cartilage to chronic infection results in progressive deterioration of both knee function and joint space. After repair of the residual extensor mechanism, the knee is immobilized until healing occurs. Partial to total patellectomy may be required to gain

control over the infection process. Loss of knee function and degenerative changes are common sequelae.

6. Non-union: There is a low incidence (2.4%) of patellar fracture nonunion. Non-union may be well tolerated by patients with limited or decreased functional demands on the knee. Nummi reported 14 of 17 non-unions as having satisfactory results. Repeat osteosynthesis may be indicated to obtain union in more active, young individuals. Partial patellectomy may be considered in the painful nonunion associated with avascular necrosis.

7. Painful retained hardware is common and is usually related to tendon or capsular irritation from Kirschner-wire penetration or the twisted ends of circulage wires. Removal of the hardware usually alleviates these symptoms. Fractures of the circulage wire are managed by removal if symptomatic. Cancellous 4.0- or 3.5-mm lag screws are difficult to remove if left for several years within hard young bone.

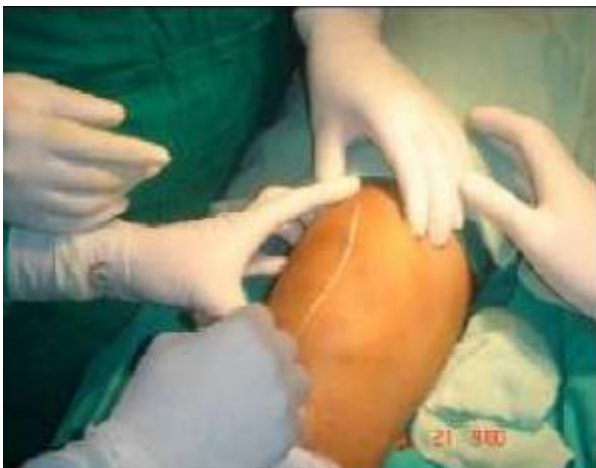

Fig. 3a. Incision

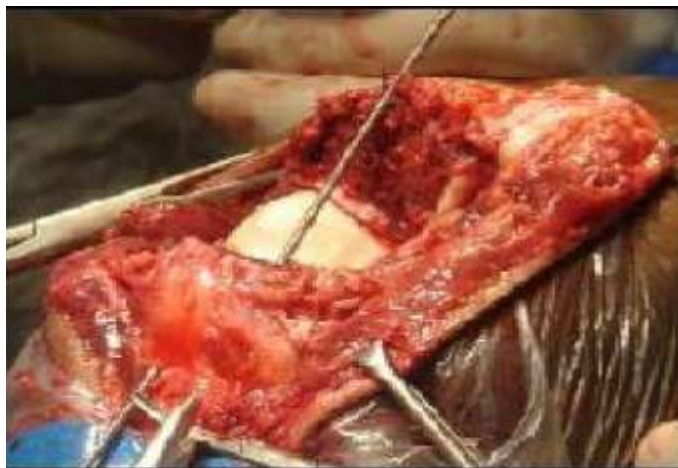

Fig. 3b. K wires into proximal fragment

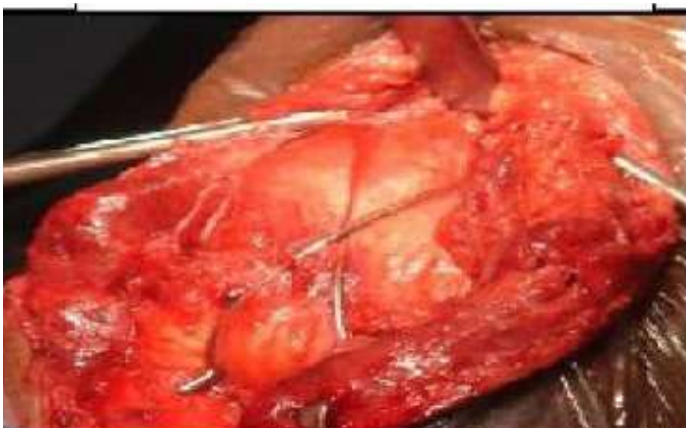

Fig. 3c. Figure 8 Applied

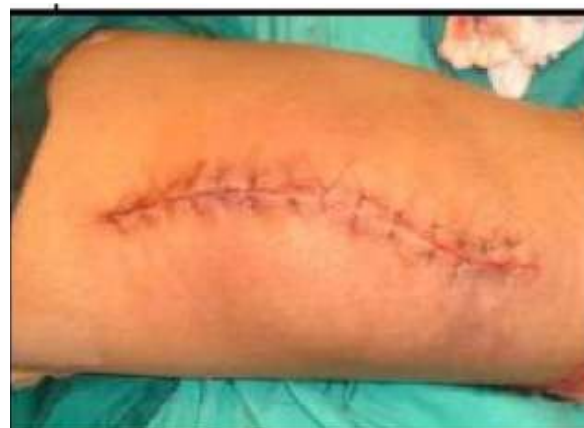
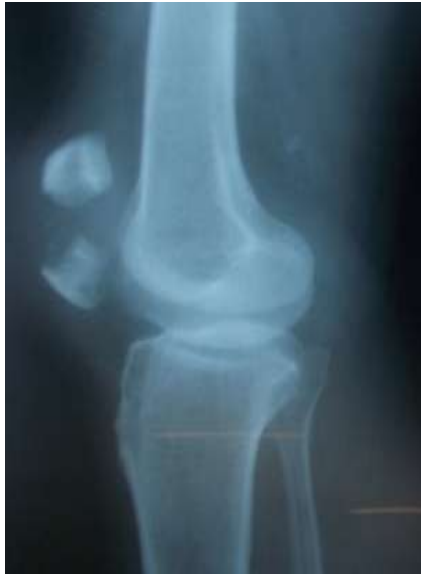
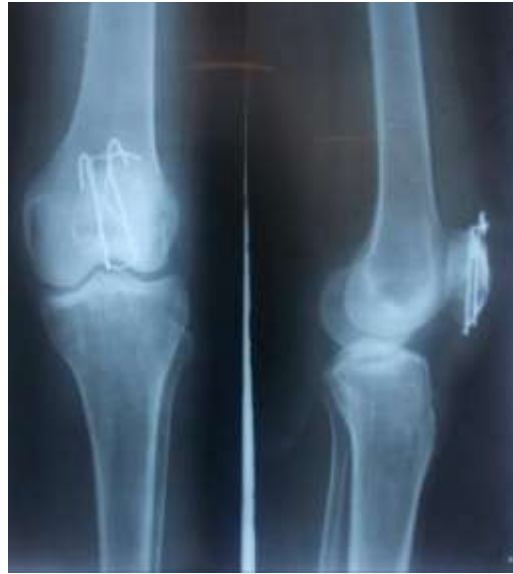Fig. 3d. Closure

X RAYS:



3e. Pre op



3f. Post op

#### MANAGEMENT OF OLECRANON FRACTURES:

**Undisplaced fractures:** Displacement is not more than 2 mm and there is no change in position with gentle flexion to 90° or with extension against gravity.

Most authors agree that undisplaced fractures may be treated by immobilization in long arm cast with elbow in 90° of flexion for 3 to 4 weeks followed by protected range of exercises, avoiding flexion past 90° until healing is complete radiographically.

The goals of treatment of displaced fractures are:

- Maintain power of elbow extension.
- Restore the congruity of articular surface. Restore the stability of the elbow.
- Prevent stiffness of joint.
- Early mobilization of joints.

#### OPERATIVE TECHNIQUE:

An incision 2.5 cms proximal to the olecranon and parallel with its lateral border was taken and carried distally for 7.5 cm. The fracture was exposed and fragments freshened. The fracture was reduced with a towel clip and a drill hole was made from side-to-side in the distal fragment. Two parallel Kirschner wires were passed perpendicular to fracture from proximal fragment into the medullary cavity. A 18-gauge stainless steel wire was passed through hole in distal fragment and then crossed in figure of eight over the posterior surface of olecranon and passed beneath the protruding Kirschner wire and aponeurosis of triceps muscle. The wire was tightened to achieve reduction and Kirschner wire bent and buried.

#### After treatment

The limb was immobilized in posterior splint at 90° of flexion. Check dressing was done on 2nd postoperative day to know condition of operative wound. Following dressing, check x-ray in AP and lateral views were done. Sutures were removed on twelfth postoperative day and gentle active assisted exercises were started. The splint was continued for four weeks.

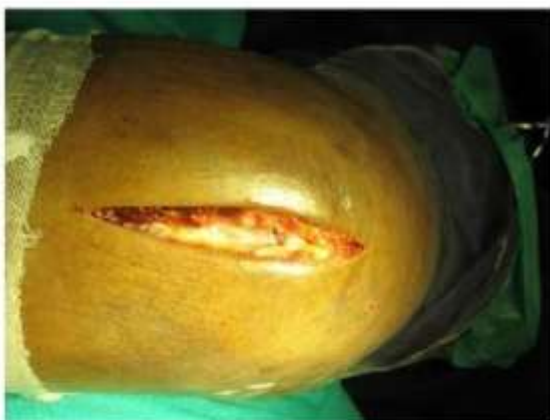

Fig 4a.Incision

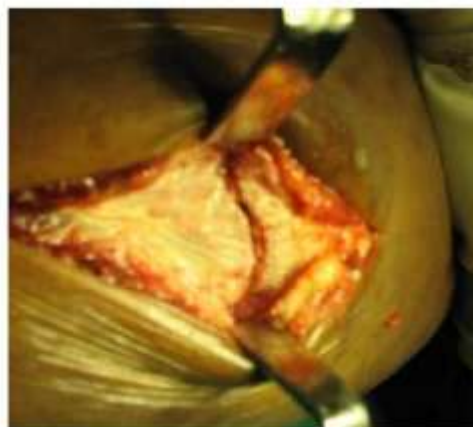

Fig 4b.Fracture Exposed

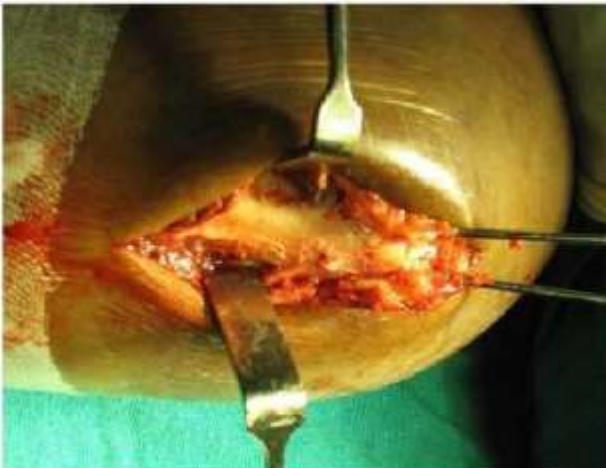


Fig 4c. K-Wires into Proximal Fragment

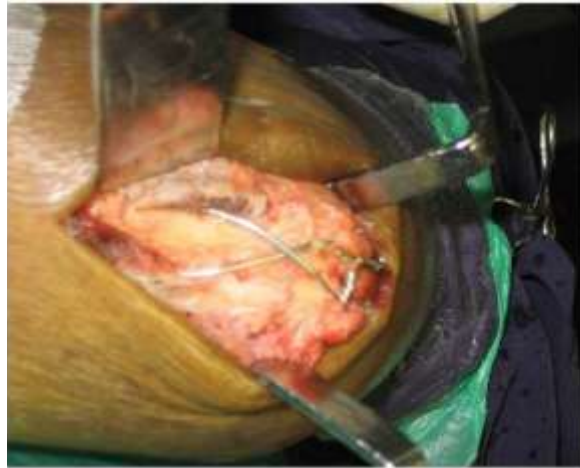
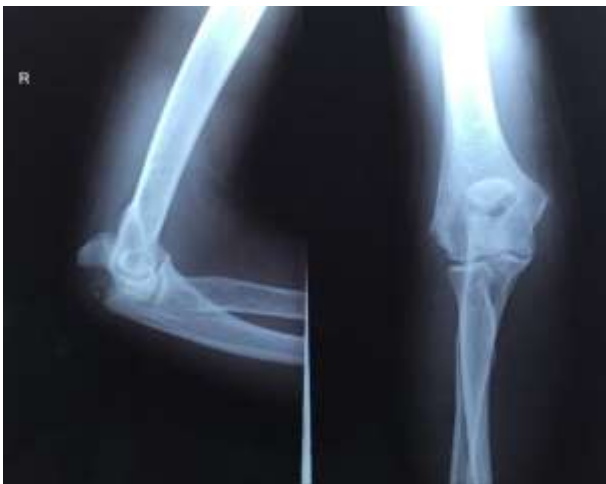
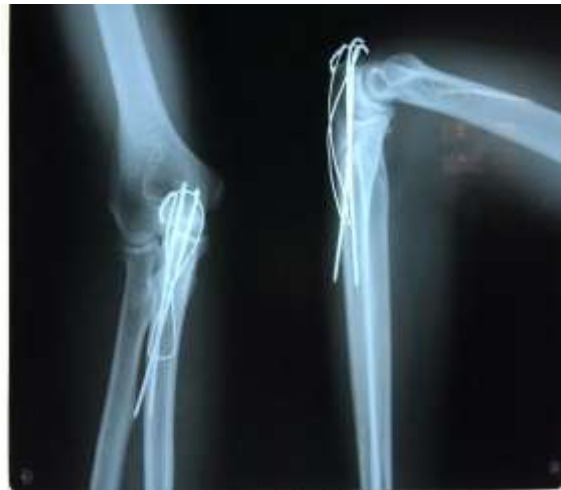Fig 4d. Figure 8 Applied

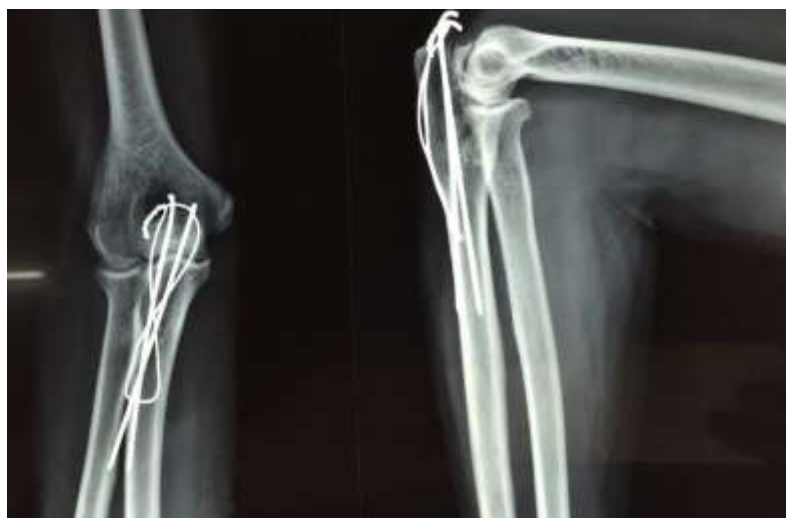**X RAYS:**



4e. Pre op



4f. Post op



4g. After 4 weeks follow up

**Complications of olecranon fractures:**

**1. Decreased range of motion**

Loss of motion can be minimized by firm internal fixation and early range of motion of the joint. Eriksson and colleagues reported that up to 50% of patients have limited

range of motion of the elbow after olecranon fractures, generally with loss of extension. However, in their series, the limitations were not great, and only 3% of the patients were aware of it.

### 2. Post-traumatic arthritis

If reduction to less than 2-mm offset cannot be obtained, the possibility of arthritis developing later is significant. In the event of articular cartilage loss, cancellous grafting in the defect may provide a fibrocartilaginous surface after graft revascularization.

### 3. Non-union

Nonunion of the olecranon has been reported to occur in 5% of olecranon fractures. The treatment of a nonunion should be suited to the patient. In a young, active patient the pseudoarthrosis may be taken down and the fracture site reapproximated and held with a tension-band wire or a suitable intramedullary device. Bone graft should be used to fill any defects in the fracture construct. Plate fixation may be needed, depending on the configuration of the fracture.

Excision of the proximal portion of the pseudoarthrosis and repair of the triceps tendon is also an acceptable method of management, especially in older patients.

### MEDIAL MALLEOLUS:

An anteromedial incision was taken 2 cms proximal to fracture line and extended distally approximately 2 cm distal to tip of medial malleolus. The fracture site was exposed and

freshened. Any interposed fold of periosteum was removed and loose fragments debrided. With a towel clip, the fracture was reduced. A transverse hole was drilled in proximal tibia about 2 cms from the fracture. Two parallel Kirschner wires were passed perpendicular to fracture site from distal fragment into the proximal fragment. An 18-gauge stainless steel wire was passed through the transverse hole and then over the medial surface and then beneath the protruding Kirschner wires. The wire was tightened to achieve reduction. The Kirschner wires were bent, cut and buried.

### After treatment:

Below knee POP slab was applied in neutral position. Check dressing was done on 2nd postoperative day to know condition of operative wound. Following dressing, check x-ray in AP and lateral views were done. Sutures were removed on twelfth postoperative day and active range of movements started. Weight bearing was allowed after 6 weeks.

### Discharge:

Patient was discharged on 12th postoperative day.

### Follow up:

Follow up was done on OPD basis at 4th, 8th and 12th week postoperatively with clinical and radiological evaluation and the results were assessed based on: Pain Swelling Tenderness at fracture site Movements of related joint Radiological union.

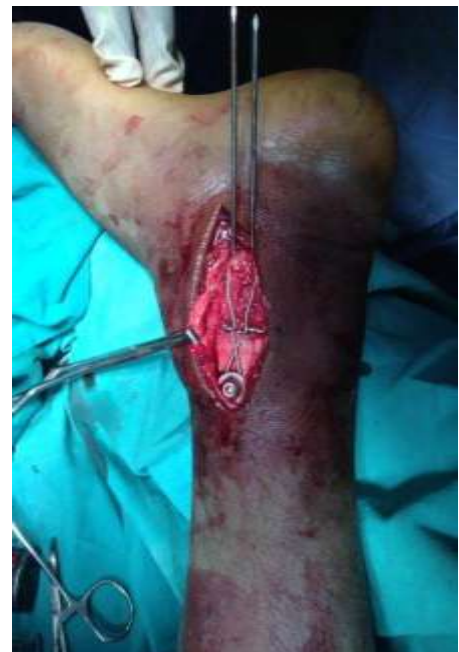
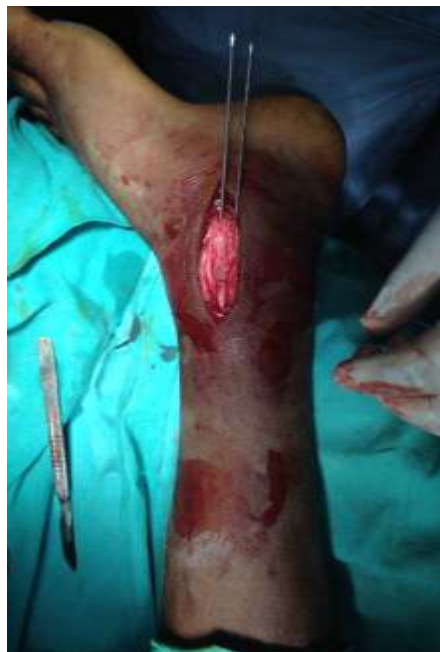
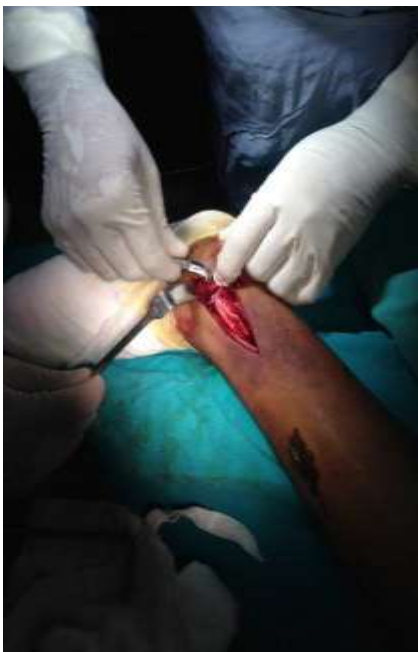Fig 5a. Exposure

Fig 5b. Fixation with K wire

Fig 5c. Tension Band wiring

### X Rays:



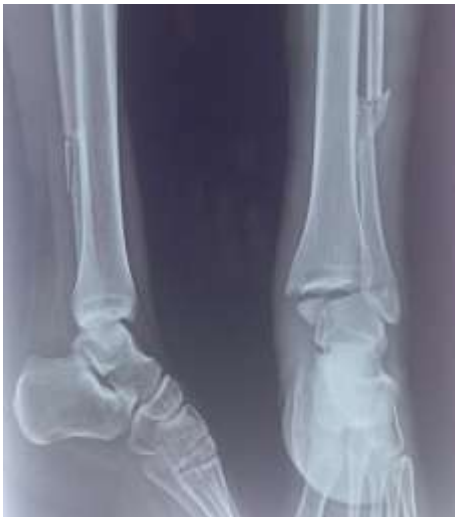

Fig 5d. Pre op

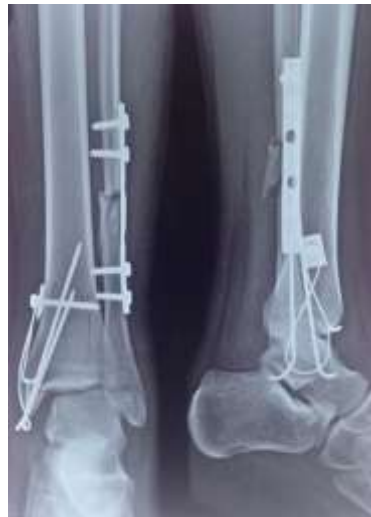

Fig 5e. Post op

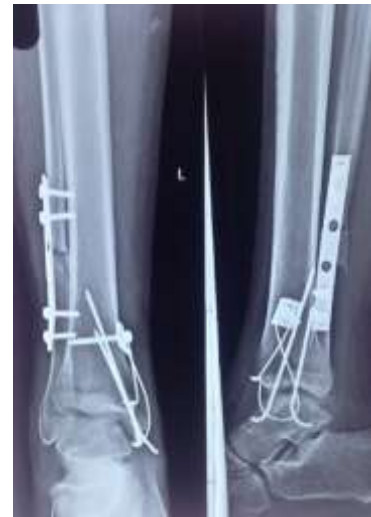

Fig 5f. After 4weeks

**Complications of medial malleolar fractures:**

**1. Non-union**

Most non-unions involve the medial malleolus. These are often avulsion injuries that were initially treated closed and fail to unite because of residual displacement of the fracture, interposed soft tissue, or associated lateral instability resulting in shearing forces on the fracture from the pull of the deltoid ligament. A nonunion in the distal portion of the medial malleolus is often not symptomatic especially if the lateral ankle is stable. Non-unions at the level of the joint may cause chronic pain, swelling, and a feeling of instability. Symptomatic non-unions have been treated with open reduction and internal fixation and sometimes with electrical stimulation. An exact reduction may be difficult because of resorption at the fracture site and remodeling of the fracture edges. Osteoporosis of the distal fragment may make fixation difficult. Gaps are filled with bone graft, and fixation is performed with either a tension band technique or cancellous screws.

**2. Wound Problems**

Marginal necrosis of skin edges after surgery occurs in about 3% of patients. Carragee and associates reviewed the early complications in 121 surgically treated closed ankle fractures and found that fractures with skin blisters or abrasions had more than double the overall complication rate. These problems can be decreased by avoiding surgery during the period of increased swelling; minimizing tourniquet time; careful handling of the soft tissues, especially the skin edges; gentle retraction; use of implants appropriate for the size of the fracture fragments; wound closure without tension; appropriate drainage of the wound; and avoiding constrictive postoperative dressings.

**3. Infections**

The infection rate in treating closed fractures with the current techniques of internal fixation is less than 2%. Superficial infections may resolve with local wound care and antibiotics. If needed, the incision can be reopened and the wound treated with dressing changes or whirlpool or both. Deep infections require formal exploration and

debridement of the joint. The fixation should be left in place if it is stable and the fracture is not healed. Preservation of the joint depends on the organism involved, amount of articular damage present, and response to treatment. Infections with bone involvement and most gram negative infections require extensive debridement, and an arthrodesis may be required as a salvage procedure.

**4. Arthritis**

Degenerative arthritis can result from damage to the articular cartilage at the time of the injury, from altered mechanics of the joint resulting from ligamentous instability or inadequate reduction of the fracture, or from both. Anatomical reduction does not totally prevent the development of degenerative changes because blunt injury to the articular surfaces is not correctable. Degenerative changes were reported in about 10% of fractures that were adequately reduced and in 85% of those inadequately reduced; these radiographic changes were usually present within 18 months of injury. The incidence of arthritis increases with the severity of the injury. An increased incidence was also found in older patients, especially in women with osteoporosis. Considering the frequency of ligament and bony injuries involving the ankle, the incidence of degenerative arthritis of the ankle is surprisingly low.

The clinical findings do not always correlate with the radiographic appearance of the joint. For symptomatic arthritis unresponsive to nonoperative modalities, an ankle arthrodesis is the most predictable reconstruction.

**MATERIAL AND METHODS:**

Patients who are admitted in department of Orthopaedics at Government Medical College, Nizamabad are taken for study after obtaining their consent.

This is prospective study from 1st Dec. 2013 to June 2015.

**Inclusion criteria:**

- Age more than 18 years.
- Includes both sex groups

- Fresh and old fractures of patella, olecranon and malleoli
- All types of fractures of patella, olecranon and malleoli
- Patient willing to give consent.
- 

**Exclusion criteria:**

- Age less than 18 years.
- Infected fractures.
- Pathological fractures.

As soon as the patient was admitted, a detailed history was taken and a meticulous examination of the patient was done. The required information was recorded and proforma was prepared. Radiographs were taken in approximate views and diagnosis was established by clinical and radiological means. Then splinting of fractures was done with above knee POP slab for patellar fractures above elbow POP slab for olecranon fractures and below knee POP slab for medial malleolar fracture. All patients were taken for elective surgery as soon as possible after necessary blood, urine and radiographic preoperative work-up.

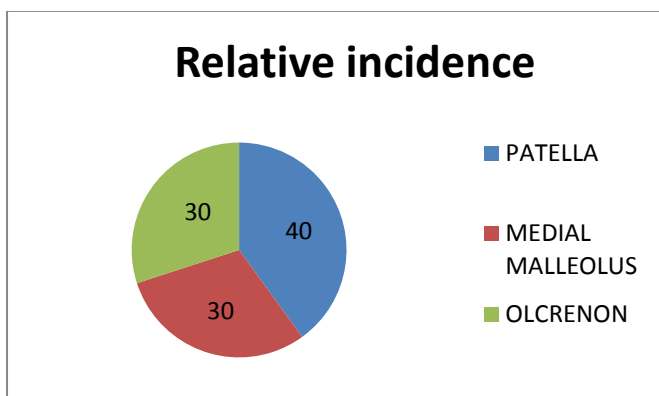
Patient's attenders were explained about the nature of injury and its possible complications and the need for surgery. Written and informed consent was obtained. Preoperative intravenous cephalosporin antibiotics were given and continued at 12 hourly interval postoperatively for five days and then switched to oral form till suture removal.

**RESULTS:**

The present study consisted of 50 cases of fractures of Patella, Olecranon, Medial Malleolus treated by tension band wiring at Government General Hospital, Nizamabad, Telangana between 1st December 2013 to 30th June 2015. The following observations were made in the present study.

**Table1: Relative incidence**

Fracture	Number of patients	Percentage (%)
Patella	20	40
Olecranon	15	30
Medial malleolus	15	30



**Chart 1: Relative incidence**

**Type of fracture:**

Transverse fractures (60%) were more common in present study

Indicating indirect trauma and transverse fractures go hand in hand most of time.

**Table2: Type of fracture**

Sl.no	Fracture	Total	Transverse	Oblique
1	Patella	20	14	6
2	Olecranon	15	8	7
3	Medial malleolus	15	8	7
	<b>Total</b>	<b>50</b>	<b>60%</b>	<b>40%</b>

**Table 3: Time taken for radiological union**

S. No.	Fracture	Total	4 weeks	8 weeks	12 weeks	16 weeks
1	Patella	20	2(10%)	16(80%)	2(10%)	-
2	Olecranon	15	-	12(80%)	3(20%)	-
3	Medial malleolus	15	-	10(66.6%)	4(26.6%)	1(6.6%)

**Table 4: Complications**

S.N O.	COMPLICATIONS	PATELLA	OLECRANON	MEDIAL MALLEOLUS
1	Joint stiffness	1	1	-
2	Superficial infection		1	1
3	Deep infection	-	-	-
4	Osteoporosis	-	-	-
5	Migration of k-wire			1

**Table 5: Evaluation of results**

S.N O.	FRACTURE	Total	Excellent	Good	Fair	Poor
1	Patella	20	10(50%)	8(40%)	2(10%)	-
2	Olecranon	15	9(60%)	3(20%)	2(13.3%)	1(6.6%)
3	Medial malleolus	15	6(40%)	5(33.3%)	3(20%)	1(6.6%)
Total		50	25(50%)	16(32%)	7(14%)	2(4%)

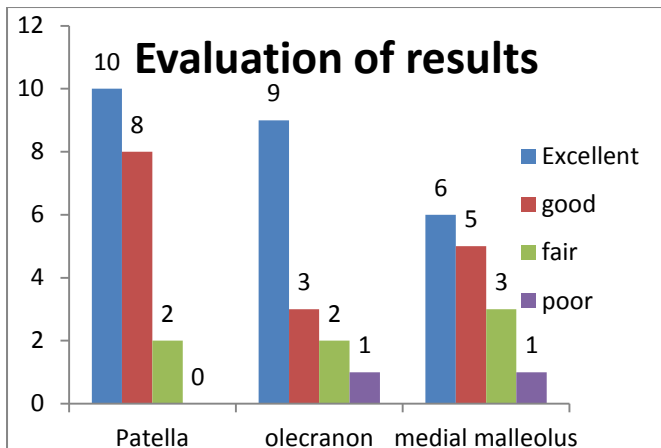


Chart 2: Evaluation of results

**DISCUSSION**

The aim of treatment of fracture is not only achieving union but also to preserve the optimum function of adjacent joints. In intraarticular fractures of patella, olecranon and medial malleolus it is important to maintain perfect anatomical reduction of fragments to obtain articular congruity by rigid fixation. The treatment of choice for these fractures is tension band wiring.

Tension band wiring was made use in our 50 cases. It has given favorable results in our experience. The findings, end results and other data will be analyzed and compared in the following discussion.

**Incidence:**

In present study of 50 cases of fractures of patella, olecranon and medial malleolus, patella fracture is the most common constituting 40%, next is shared by fracture olecranon and medial malleolus constituting 30% each. High incidence of patella fracture (56%) was reported by Maini and Kochar in their series of 107 cases 47.

Table 8: Results

**PATELLA OLECRANON**

Series	Excellent	Good	Fair	Poor	Excellent	Good	Fair	Poor
Dudani, Sancheti	93.3	-	-	-	-	-	-	-
Maini and Kochar	36.6	38.4	15	10	46.2	46.2	7.6	-
Pandit, Shah	-	-	-	-	75	25	-	-
Gary Wolfgang	-	-	-	-	73	15	-	-
Mathewson	-	-	-	-	90.48	9.52	-	-
Levack	-	50	35.7	14.3	-	-	-	-
Present study	50	40	10	-	60	20	13.3	6.66

**Type of fracture:** Transverse fractures (60%) were more common in present study  
 Indicating indirect trauma and transverse fractures go hand in hand most of time

Table 6: Type of fracture

Series	% of transverse fracture
Maini and Kochar	70
Daniel F. Murphy	57.5
Dudani and Sancheti	73.3
Present study	60

**Complications**

In our series, we came across superficial infection in one case of patella (3.33%), joint stiffness in one case of patella and two cases of medial malleolus (10%) and migration of K-wire in one case of medial malleolus (3.33%). Complications were noted more in medial malleolus because of less soft tissue coverage.

Table 7: Complication in other series

Series	No. of cases	% of infection
Pandit, Shah	20	15
Maini and Kochar	107	11
Gary Wolfgang	45	2.5
Present study	50	4

**Results:**

According to criteria outlined in methodology, best results in our study were obtained in fracture of patella followed by olecranon fracture and medial malleolus. In total of 50 cases, 25 (50%) had excellent results, 16 (32%) had good results, 7 (14%) had fair and poor result is 2(4%).

**Injury to ankle:**

In present study, the commonest type of ankle injury noted is supination – external rotation according to Lange-Hansen classification. With reference to Lauge- Hansen (1942) classification, supination – external rotation is commonest type of injury.

**Table 9: Injury to ankle**

Injury	Lindsj o (%) n=611	Lauge (%)n=22 9	Bostma n (%) n=56	Present study(%) ) n=15
Supination-Adduction	42	16	3.8	7.7
Supination-External rotation	42	71	96.2	46.15
Pronation-Abduction	17	5	-	23.07
Pronation-External rotation	13	7	7	15.38
Vertical compression	-	-	-	7.7

Most of the patients in our series were operated within period ranging from 2-10 days.

**Technical aspects**

**Ankle:**

In present study related to tension band wiring, we noted difficulty in maintaining reduction of fragments while introducing "K" wires, passing K wires through bone, soft tissue, bending ends of K-wires.

Skin necrosis with exposure of bent ends of K-wires was seen at medial side of ankle in one case due to migration of "K" wires.

Many workers (Macko and Szabo, Maini and Kochar) have met with similar complications.

**Summary**

Fifty cases of fractures were treated with tension band wiring, which comprised of fracture patella 20 cases, fracture olecranon 15 cases and medial malleolus 15 cases. The study comprised of 73.33% male patients and 26.67% female patients.

Right side and left side were equally involved. Fractures occurred irrespective of their occupation.

The commonest mode is road traffic accidents (RTA) that accounted for 40% of fractures.

The types of fractures included are transverse (60%) and oblique (40%).

All patients (90%) reported within 7 days of injury.

All patients were treated by open reduction and internal fixation by tension band wiring. Postoperatively, the limb

was immobilized for an average of 14 days. Isometric exercises were started from day 2. Non-weight bearing mobilization was started by 2 weeks. Weight bearing was allowed after 6 weeks. Follow-up was made at 4 weeks, 8 weeks and 12 weeks.

About 98% of fractures had united after 12 weeks. One case of medial malleolus took 16 weeks where wire migration was noted with superficial infection who was a diabetic patient.

In present study, there were 50% excellent, 32% good, 14% fair and 4% poor results

**CONCLUSION**

It was concluded from the present study that:

1. Tension band wiring by principle overcomes the distractive force, achieves compression at the fracture site and maintains the alignment by minimum hardware.
2. By achieving compression at fracture site, the fracture heals faster and the patient is back to work earlier.
3. The fixation enables early active movements of joints as early as four weeks when the fracture is healing, which reduces joint stiffness.
4. The long-term complications of prolonged immobilization like joint stiffness, muscle wasting, pressure sores, and osteoporosis are avoided.

Hence, it is concluded that tension band wiring is a simple, inexpensive technique and effective means of fixing fracture based on biomechanical principle with minimum complications.

**REFERENCES**

1. Campbell's Operative Orthopaedics, 10th ed, Vol. 3, 3032.
2. Macko D, Szabo RM. Complications of Tension band Wiring of Olecranon fractures. JBJS 1975; 578: 399.
3. Mullet H, Shannon F, Noel J, O'Rourke SK. Transcortical placement of K wires prevents backout: A clinical and biomechanical study of tension band wiring of olecranon fractures. JBJS 2000; 82-B Supplement I 15.
4. Van Linden SC, VAN Kampen A, Jaarsma RL. K wire position in tension band wiring technique affects stability of wires and long term outcome in surgical treatment of olecranon fractures. J shoulder Elbow Surgery 2012;21:405-411.
5. Carpenter JE, Kasman RA, Patel N. Biomechanical evaluation of current patella fracture fixation techniques. J Orthop Trauma. 1997; 11: 351-356.
6. Maini PS, Kochar. Rigid fixation of various fractures by tension band wiring. I J Orthop 1986 July; Vol. 20: 162.
7. Weening J. Orthop Trauma 2005 Feb; 19 (2): 102-108.

8. Chapman MW, editor, Chapman's orthopaedic Surgery, Philadelphia, Lippincott Williams and Wilkins, 3rd edition 2001; 444-450.
9. TY Fowler, MD; Kevin Pugh, MD; Alan S Litsky, MD; ScD; Benjamin C. Taylor, MD; Bruce G. French, MD Orthopedics August 2011- Vol 34 Issue 8: E349-E355.
10. Hung LK, Chan KM, Chow YN, Leung PC. Fractured patella: Operative treatment using the tension band principle. Injury 1985; 16: 343-347.
11. Van Linden SC, VAN Kampen A, Jaarsma RL. K wire position in tension band wiring technique affects stability of wires and long term outcome in surgical treatment of olecranon fractures. J shoulder Elbow Surgery 2012; 21:405-411.
12. Lindsjo Ulf. Operative treatment of ankle fracture dislocation. Clin Orthop 1985; 199: 28.
13. Lauge Hansen N. Fractures of Ankle III, Genetic Roentgenologic diagnosis of ankle fractures. AJR 1954; 71: 456-471.
14. Weening J. Orthop Trauma 2005 Feb; 19 (2): 102-108.
15. Levack B, Flannagan JP, Hobbs S. Results of surgical treatment of patellar fractures. JBJS 1985; 67B: 416-419.
16. Hung LK, Lee SY, Leung KS, et al. Partial patellectomy for patellar fracture: tension band wiring and early mobilization. J Orthop Trauma. 1993; 7: 252- 260.
17. Ricci WM, Tornetta P, Borrelli J Jr. J Orthop Trauma. 2012 Oct; 26(10):602-6
18. Bostman. Displaced malleolar fractures associated with spiral fracture of tibial shaft. Clin Orthop 1988; 228-202.
19. Pandit, Shah. Evaluation of results of Olecranon fractures treated by TBW. I J Orthop 1986 July; 20: 168.
20. Dudani, Sancheti. Management of patellar fracture with tension band wiring. I J Orthop 1981; 15: 43-48.
21. Mathewson MH, Mc. Creath SW. Tension band wiring in treatment of olecranon fractures. JBJS 1975; 57: 199.
22. Wolfgang G Burke F, Bush D. Surgical treatment of displaced olecranon fractures by tension band wiring technique. Clin Orthop 1987; 192.
23. Murphy DF, Greene WB, Domeron TB. Displaced olecranon fractures in adults. Clin Orthop 1987; 224: 215-223.