

## International Journal Of Medical Science And Clinical Inventions

Volume 3 issue 5 2016 page no. 1876-1881 e-ISSN: 2348-991X p-ISSN: 2454-9576

Available Online At: <http://valleyinternational.net/index.php/our-jou/ijmsci>

# Treatment Of Dental Fluorosis With Porcelain Veneers For Esthetically Compromised Maxillary Anteriors

Dr Dhanasekar Balakrishnan<sup>1</sup>, Dr Manawar Ahmad<sup>2</sup>, Dr Abdullatif Albinali<sup>3</sup>, Dr Ahmed Areashi<sup>4</sup>,  
Dr Hina Naim<sup>5</sup>

<sup>1</sup>Professor & Head of Department, Department of Prosthodontics, Manipal College of Dental Sciences, Manipal, India

<sup>2</sup>Assistant Professor, Department of Prosthodontics College of Dentistry, Jazan University, Saudi Arabia

<sup>3</sup>Senior Resident, Restorative Dentistry, Saudi Board

<sup>4</sup>Dental Intern, College of Dentistry, Jazan University, Saudi Arabia

<sup>5</sup>Assistant Professor, Department of Prosthodontics College of Dentistry, Jazan University, Saudi Arabia

**corresponding author:** Dr Manawar Ahmad

Assistant Professor, Department of Prosthodontics; College of Dentistry, Jazan University, Saudi Arabia

### Abstract

*The laminate veneer is a conservative alternative to full coverage for improving the appearance of an anterior tooth. Laminate veneers have evolved over the last several decades and become one of the esthetic dentistry's most popular restorations. A porcelain veneer is an extremely thin shell of porcelain applied directly to the tooth structure. This restoration can be used to improve the color of stained tooth, alter contours of misshapen teeth, and close interproximal spaces. Tooth preparation is minimal, remaining within enamel. The restoration derives its strength from the ability of a composite resin cement with a silane coupling agent, to bond with etched porcelain and etched enamel. It biomimetically restore the mechanical behavior of the crowns of teeth on which they are placed, i.e. they mimic or recover the biomechanics of the original tooth by means of the restorative material and technique. As a consequence, besides achieving natural appearance of the smile, the stress distribution in a tooth is also restored with porcelain veneers similar to that of a sound tooth. This case report illustrates the restoration of esthetically challenged maxillary anterior teeth using porcelain laminates with 3 years of follow up.*

**Key words:** Veneers, Porcelain, Laminates, Esthetics

### Introduction

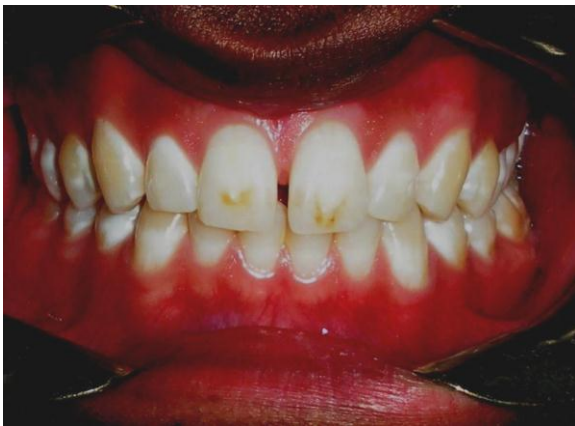Porcelain laminate veneers are among the most esthetic means of creating a more pleasing and beautiful smile. It allows for the alteration of tooth position, shape, size and color. They require a minimal amount of tooth preparation, approximately 0.5 mm to 0.7mm of surface enamel reduction. Therefore it is considered as more conservative restoration than a crown, which requires significant removal of sound tooth structure.<sup>1,2</sup> Although not the only alternative for all esthetic abnormalities, they are truly a remarkable restoration when they are the

treatment of choice. This article presents a case report with 3 years of follow up of a patient with dental fluorosis along with midline diastema.

### Case report

A 23 year old patient reported to the department of Prosthodontics, Manipal College of Dental Sciences, Manipal, India, with the chief complain of discolored maxillary anterior teeth along with the midline diastema. Intraoral examination revealed brown stains present among most of the maxillary teeth caused by dental fluorosis. The clinical examination also showed small lateral

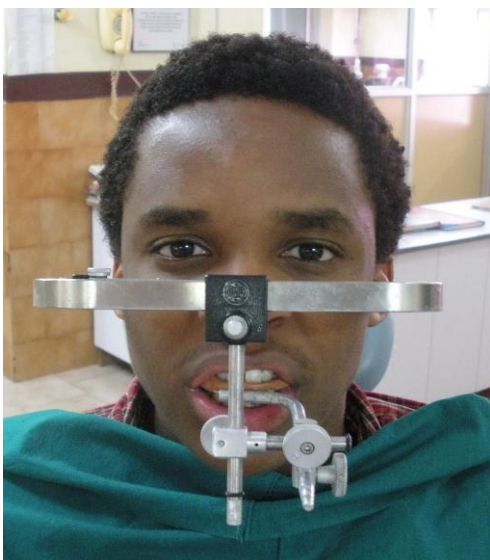incisors and 2mm wide midline diastema between the maxillary central incisors (Picture 1).



Picture 1. Intra oral view showing Dental Flourosis

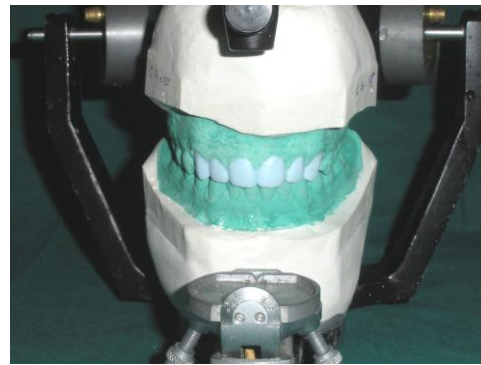
A treatment plan was devised and explained to the patient to restore the appearance of the patient's smile, with preparation of porcelain laminate veneers on the maxillary anterior affected teeth.

Diagnostic impressions of the maxillary and mandibular arches were made. Maxillary and mandibular primary casts were mounted in the semi adjustable articulator using face bow transfer (Picture 2).



Picture 2. Face bow transfer

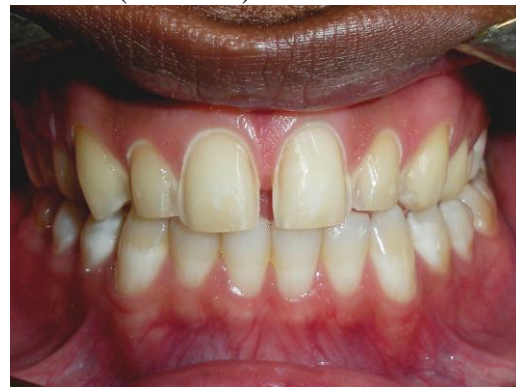Diagnostic wax-up was carried out in the prosthetic laboratory for all the affected maxillary anterior teeth to help in final contouring of the porcelain laminates (Picture 3).



Picture 3. Diagnostic wax-up of maxillary anterior tooth

It also helped to explain the treatment outcome to the patient.

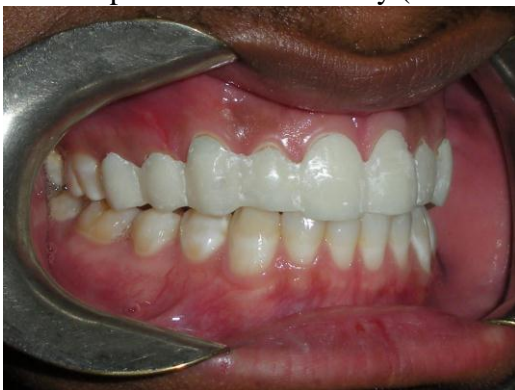Tooth preparation for the maxillary anterior teeth was carried out with minimal preparation following the guidelines for the porcelain laminate veneers (Picture 4).



Picture 4. Tooth preparation for laminates

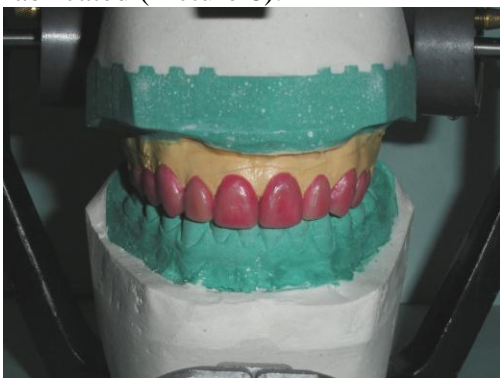Tooth preparation was minimal and limited to the enamel of the tooth. However sufficient enamel thickness was removed to provide adequate space for a correctly contoured laminate restoration. Depth orientation groove of 0.3mm depth was place on gingival half and 0.5mm depth on incisal half of the tooth was placed using three wheel diamond depth cutter. Remaining tooth structure of the facial surface was removed using round end tapered diamond. The proximal reduction was extended into the contact area. The contacts were opened to facilitate separation of the dies without damaging the inter proximal finish line. Chamfer finish line was placed within enamel at the level of gingival crest. The incisal edge was reduced such that porcelain overlaps the incisal edge, terminating on the lingual surface to provide a vertical stop that aid in the proper seating of the veneers. The incisal reduction was verified in centric and eccentric position for the sufficient

clearance. Before making final impression, a retraction cord of size 00 (Ultrapak, Ultradent, South Jordan, USA) was used to deflect the gingival soft tissue to expose the finish line. An addition polyvinyl siloxane impression (Zermack, Italy) was made for the maxillary arch using double mix single impression technique. Since the preparations were in the enamel, light activated microfilled composite resin was used to fabricate the temporary veneer. Two to three dots of etchants were applied on tooth surface and composite resin were built up on the prepared tooth to prevent the sensitivity (Picture 5).



Picture 5. Provisional restoration

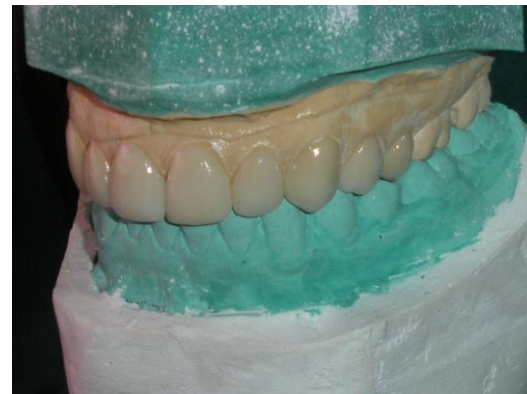The master casts were mounted on the semi-adjustable articulator and wax patterns were fabricated (Picture 6).



Picture 6. Wax pattern fabrication

In order to check the final contour and size of the porcelain laminates, these wax patterns were well tried on the prepared teeth of the maxillary arch with the great care to prevent any fracture. The wax patterns were sprued, invested and pressed using the IPS Empress Esthetic Ingots (Ivoclar Vivadent, USA) ceramic system. After cooling, the veneers were carefully removed by glass bead

air abrasion and checked for the marginal integrity on the original master die (Picture 7).

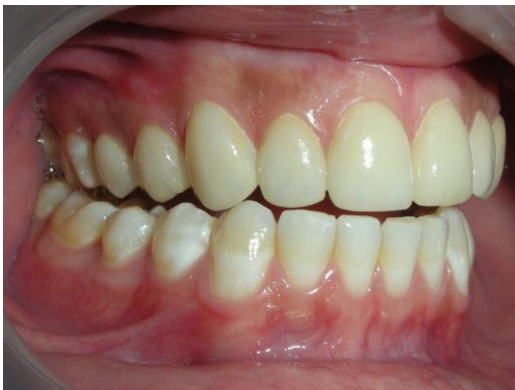

Picture 7. Laminate veneers after glazing

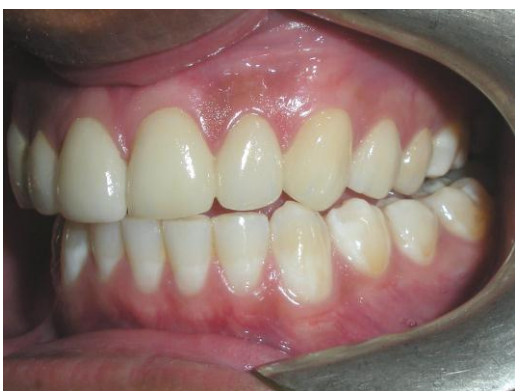The internal surface of the porcelain veneers were acid etched with 5% hydrofluoric acid solution for 30 seconds to produce micro structural pits that enhance the mechanical interlocking while cementation.

The prepared tooth were cleaned with non fluoride pumice. A drop of glycerine was applied to each tooth to help the veneer stay in mouth during the try-in. After verifying the marginal fit & proximal contacts in the try-in stage and determination of the cement color, the veneers were cleaned with acetone to remove any traces of impurities. Before luting, 37% phosphoric acid etchant gel was applied to the surface of the prepared tooth and allowed to remain for 30 seconds. The tooth surface was thoroughly rinsed with water for 60 seconds and air dried for dull, frosted-white appearance of properly etched enamel. It was followed by application of the primer and bonding agents (Scotchbond Multi Purpose System, 3M ESPE, St. Paul, USA) on the tooth surfaces.

The Relyx silane-based ceramic primer (3M ESPE, USA) was applied to the inner surfaces of the veneers for 60 seconds. Subsequently, the surfaces were dried using oil/moisture-free air for 5 seconds, and the Scotchbond Multi Purpose Plus adhesive (3M ESPE, USA) was applied to the internal areas of the veneers.<sup>3-5</sup> Luting procedure was performed individually for each veneer. Resin cements (Medium Value, Variolink Veneer, Ivoclar, Vivadent, USA) was used and light-cured for 10 seconds (Figures 8 and 9).




Picture 8. Right side intraoral view with canine guidance occlusion



Picture 9. Left side intraoral view with canine guidance occlusion

After the initial set, the flash was removed carefully before the resin cement is completely polymerized. Additional 45-60 seconds light curing was done from lingual and labial side. Once the luting agent was polymerized, fine grit flame diamond was used to trim excess cement. The occlusion was checked and adjusted. Final finishing was accomplished with porcelain polishing agents, including rubberized abrasives and diamond polishing paste. The proximal areas were polished with finishing strips.

Approximately one week after the placement of the laminates, patient was asked to return to the dental clinic for the treatment evaluation. The placement of the laminates and the gum tissue response were evaluated. Regular maintenance and dental check-ups were recommended so that veneers and oral health can be reviewed periodically. Thus porcelain laminate veneers allowed to successfully restore dental function and esthetics, resulting in a natural and esthetically pleasing smile (Figure 10).



Picture 10. Post treatment extra oral view of patient

### Discussion

Laminate veneers are the most conservative way to repair or enhance the appearance of the teeth and holds an important place in aesthetic dentistry. The long lasting thin porcelain shells that are bonded to the front of the teeth provide maximum esthetics in the patient's mouth. It involves very little tooth reduction so that the healthy tissues of the teeth are secured.

The idea of porcelain veneer is not new. In 1930-1940, Charles Pincus used thin porcelain veneers to improve the esthetics with use of denture adhesives to hold the veneers in place. The development of bis-GMA and composite resin restorative materials provided innovative opportunities to restored discolored or malposed tooth. In mid 1970 and early 1980, the composite resin laminate veneer, with or without facing evolved. The early composite resin bonding presented several problems, including a monochromatic appearance, with staining and loss of luster over time. The second evolution of veneers involved the development of preformed veneers that were joined to the etched tooth surface.<sup>6</sup> In early 1980 a method of bonding porcelain to acid etched enamel was developed. Etching the porcelain with, usually with hydrofluoric acid is the most important factor in determining bond strength between the composite resin luting agent and the porcelain veneers. The

mechanical strength obtained by etching the porcelain increases the shear bond strength by a factor of four when compared to unetched porcelain. The application of silane coupling agent also improves the bond strength. Silane coupling agent initiates the weak chemical bond between SiO<sub>2</sub> of the porcelain and bis-GMA polymer of the composite resin cement.<sup>7</sup> Thermocycling does not significantly reduce the strength of etched enamel/composite/etched porcelain bonding when a silane coupling agent is first applied to the porcelain.<sup>8-10</sup>

The improved shear bond strength of etched porcelain/silane/resin/etched enamel permits an expanded use of veneers, but sufficient enamel must remain to achieve an adequate bond. Indications for porcelain laminate veneers include enamel hypoplasia, tooth discoloration, intrinsic staining (tetracycline staining), fractured teeth, closure of diastemas, and correction of anatomically malformed anterior teeth.<sup>11</sup> Porcelain laminate veneer teeth can be considered as conservative approach to restore anterior guidance, specially on worn out mandibular incisors. An increase in incisal length up to 2mm does not significantly change the fracture resistance either the restoration or the tooth.<sup>12-15</sup>

## Conclusion

Technological advances in materials and techniques have been allowing to obtain natural esthetic results with conservative interventions. Such advances have enabled the development of more conservative techniques and increased the chances laminate veneers as very effective tools for both esthetic and functional rehabilitation. The use of ceramic veneers without tooth wear, reinforcing the concept that minimally invasive porcelain laminate veneers could become versatile and conservative allies in the field of esthetic dentistry.

## References

1. Pincus C. Building mouth personality. J Calif State Dent Assoc 1938;14: 125-9.

2. Peumans M, Van Meerbeek B, Lambrechts P, Vanherle G. Porcelain veneers: a review of the literature. J Dent 2000; 28:163-77.
3. Barghi N, Berry TG. Post-bonding crack formation in porcelain veneers. J Esthet Dent 1997;9:51-4.
4. Friedman M. Multiple potential of etched porcelain laminate veneers. J Am Dent Assoc 1987;115(Spec Iss): 83E-87.
5. Christensen GJ, Christensen RP. Clinical observations of porcelain veneers: a three-year report. J Esthet Dent 1991;3:174-9.
6. Calamia JR: Etched porcelain veneers: the current state of the art. Quintessence Int 1985; 16:5:5-12
7. Horn HR: Porcelain laminate veneers bonded to etched enamel. Dent Clin North Am 1983; 27:671-684
8. Lin CP, Douglas WH. Failure mechanisms at the human dentin-resin interface: a fracture mechanics approach. J Biomech 1994;27:1037-47.
9. Troedson M, Derand T. Shear stresses in the adhesive layer under porcelain veneers. A finite element method study. Acta Odontol Scand 1998; 56:257-62.
10. Stacey G: A shear stress analysis of the bonding of porcelain veneers to enamel. J Prosthet Dent 1993;70:395-402
11. Goldstein R: Diagnostic dilemma: To bond, laminate or crown? Int J Periodont Rest Dent 1987; 5: 9-29
12. Yoshikawa T, Sano H, Burrow MF, Tagami J, Pashley DH. Effects of dentin depth and cavity configuration on bond strength. J Dent Res 1999;78: 898-905.

13. Walls AW. The use of adhesively retained all-porcelain veneers during the management of fractured and worn anterior teeth: part 2. Clinical results after 5 years of follow-up. *Br Dent J* 1995;178:337-40.
14. Peumans M, Van Meerbeek B, Yoshida Y, Lambrechts P, Vanherle G. Porcelain veneers bonded to tooth structure: an ultra-morphological FE-SEM examination of the adhesive interface. *Dent Mater* 1999;15:105-19.
15. Wall JG, Reisbick MH, Johnston WM: Incisal edge strength of porcelain laminate veneers restoring mandibular incisors. *Int J Prosthodont* 1992; 5:441-446