

Histopathological Correlation of Adenomyosis and Leiomyoma in Hysterectomy Specimens As The Cause Of Abnormal Uterine Bleeding In Women Of 20-60 Years Age Group.

Dr.Aparna Langthasa¹, Dr.Chandanjyoti Saikia²

¹Assistant Professor , ²Demonstrator

Pathology department, Gauhati Medical College, Guwahati. Assam,India,

Abstract: *The objective was to study adenomyosis and leiomyoma as the cause of abnormal uterine bleeding in hysterectomy specimens. This was a study carried out on 326 hysterectomy specimens from March 2015 to December 2015, of subjects who presented to the department of obstetrics and gynaecology at Gauhati Medical College and Hospital with the complain of abnormal uterine bleeding. Data including age, parity, symptoms and clinical indication for hysterectomy was collected for the study and the histopathological findings were correlated. The specimens were processed routinely and stained with hematoxylin and eosin stain and examined microscopically. Women in the perimenopausal age (41-50 years) accounted for the highest number of cases (194, 59.50%) presenting with symptoms of AUB. In this age group adenomyosis was the found to be the commonest cause of AUB (147, 45.09%). The most common symptom was heavy menstrual bleeding followed by dysmenorrhea . Adenomyosis was clinically suspected in 201cases of which 177 (88.05%) cases were confirmed on histopathology. Leiomyoma (Fibroid) was clinically diagnosed in 125 cases and confirmed in 118 (94.4%) cases histologically .Clinical, radiological and pathological evaluation correlated well to diagnose leiomyoma (Fibroid) but were not of much help to diagnose adenomyosis. Adenomyosis still remains a clinical challenge; and so has to be kept in mind by the clinician, as well as pathologist in women with AUB.*

Keywords: *Abnormal uterine bleeding, Hysterectomy Adenomyosis, Leiomyoma.*

I. INTRODUCTION

Abnormal uterine bleeding in any period of life is considered serious and it accounts to a high percentage of out patient department attendance. Abnormal uterine bleeding occurs in 9 to 14 percent of women between menarche and menopause, significantly impacting quality of life. Abnormal uterine bleeding is of considerable clinical significance because of its numerous inorganic and organic causes.

Adenomyosis, is a common non- malignant condition of the uterus, characterized by the presence of endometrial glands as well as stromal elements situated at least 2.5mm below the endomyometrial junction The relationship between adenomyosis and the genesis of AUB is

unclear, lending strength to the notion that extensive additional research is required [1,2]

Benign fibromuscular tumors of the myometrium is called Leiomyoma or Fibroid. Leiomyoma is the most frequent benign lesion that causes abnormal uterine bleeding.

The prevalence of adenomyosis vary widely from 5% to 70%^[1,3] which is probably related to inconsistencies in the histopathologic criteria for diagnosis. On the contrary, leiomyomas have a high prevalence up to 70% in Caucasians and 80% in women of African ancestry.^[1,4] They also have a wide spectrum of size and location (subendometrial, intramural, subserosal or a combination of these). Furthermore, they have

wide varying rates of growth even in a single individual.

Hysterectomy is the definitive treatment for fibroids, adenomyosis not responding to medical treatment, hyperplasia and malignancy. A number of minimally invasive surgical options for hysterectomy do exist now and are promising like endometrial ablation, thermal balloon therapy and uterine artery embolization but restricted availability and cost factor limit them from being widely used.^[5,12] Therefore, hysterectomy still remains the widely accepted and practiced treatment of choice.

The purpose of our study was to find the prevalence of adenomyosis and leiomyoma as the cause of AUB by histopathological examination of hysterectomy specimens received in our department. The reason for selecting these two entities for our study was that adenomyosis and leiomyoma are the two most common causes for AUB. Adenomyosis presents with dysmenorrhea and AUB. The clinical presentation of leiomyoma depends on their size and location, the most common are AUB, pain and sensation of pressure. In both of them, AUB is the common presentation but unfortunately they cannot be differentiated solely on clinical ground and a histopathological examination is required.

II. MATERIALS AND METHOD

The study was carried out in the pathology department ,Gauhati Medical College ,from March 2015- Dec 2015. During this peroid, 482 hysterectomy was done

and specimens were received in the pathology laboratory. Out of these 326 cases were included in our study Inclusion criteria were women coming to outpatient department with complaint of AUB for which hysterectomy was performed. Patients in whom endometrial biopsies were inconclusive for the cause of AUB and subsequently underwent 4 hysterectomies were

also included in the study. Vaginal and abdominal hysterectomies done for complaints other than AUB and malignancies were excluded from the study. Data of these patients was collected in relation to patient's age, parity, presenting symptoms, ultrasonography findings and clinical indication for hysterectomy.

On gross examination, any apparent abnormality i.e., asymmetrical enlargement of the uterus, fibroid, polyp, any pinpoint/cystic areas of hemorrhage and endometrial thickening was noted. The number, size and location of the fibroid were also noted. Representative sections were taken, fixed in 10% formalin, routinely processed and stained with hematoxylineosin (H & E) stain and examined microscopically.

III. RESULT

A total of 326 cases were included in the study. Age of the patients ranged from 20 to 60 years. The largest group ($n=194$) was of perimenopausal age (41-50 years) contributing 59.50% of total cases in the study Table 1.

Serial No.	Age	No.of Cases	Percentage
1	20-30	8	2.45%
2	31-40	103	33.12%
3	41-50	194	59.50%
4	51-60	21	6.44%

Table:1 Showing age distribution of patients presenting with AUB.

In this age group, adenomyosis was the commonest pathology 43.29% ($n=84$) followed by leiomyoma 35.05% ($n=68$), whereas 21.64% ($n=42$) showed dual pathology of adenomyosis and leiomyoma,

Table 11.

Serial No.	Age	Adenomyosis	Leiomyoma	Dual
1	20-30	3	5	0
2	31-40	48	40	15
3	41-50	84	68	42
4	51-60	12	8	1

Table 11: Showing distribution of patients according to histopathological lesion.

Only a small number of patients ($n = 304$) had undergone radiological investigations preoperatively. The radiological diagnosis correlated well with the histopathological findings. 184 patients were given the provisional diagnosis of adenomyosis and 120 patients of fibroid on ultrasonography. Out of these in 177 (88.05%) patients the diagnosis of adenomyosis was confirmed on histopathology whereas all patients of fibroid uterus showed histopathological diagnosis of leiomyoma in 118 (94.4%) patients. The clinical diagnosis of adenomyosis with AUB was given in 201 patients and 125 patients were clinically suspected to have fibroid as a cause of AUB, Table III

Disease	Clinical	USG	Histopathology
Adenomyosis	201	184	177(88.05%)
Leiomyoma	125	120	118 (94.4%)

Table III: Showing correlation of histopathological diagnosis and radiological diagnosis.

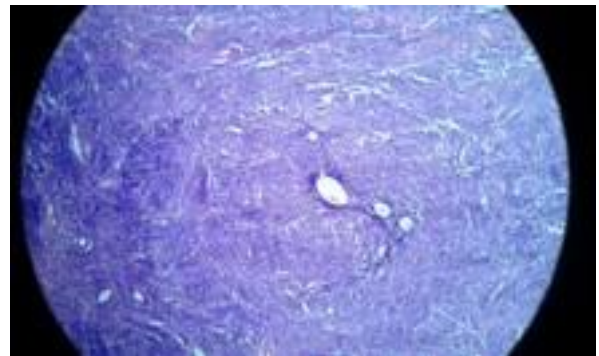


Fig A: Showing adenomyosis .

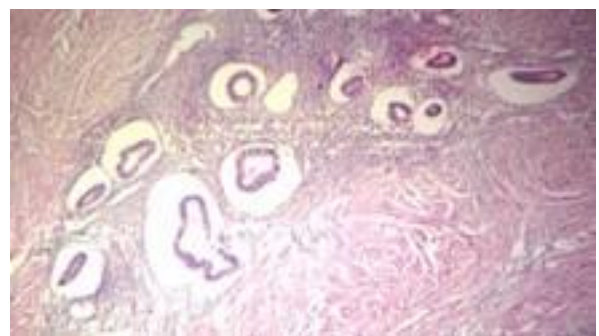


Fig B : Showing Adenomyosis

Heavy menstrual bleeding was the symptom in most of the patients as compared to irregular menstrual bleeding. In both the categories AUB , the patient showed adenomyosis as the underlying histopathological lesion as compared to number of cases of leiomyoma .

III. DISCUSSION

The etiologies of AUB is multifactorial .The Menstrual Disorders Working Group of the International Federation of Gynecology and Obstetrics proposed a classification system and standardized terminology for the etiologies of the symptoms of AUB, which has been approved by the International Federation of Gynecology and Obstetrics' executive board and supported by the American College of Obstetricians and Gynecologists [1]. With this system, the etiologies of AUB are classified as —related to uterine structural abnormalities and —unrelated to uterine structural abnormalities and categorized following the acronym PALM– COEIN: Polyp,

Adenomyosis, Leiomyoma, Malignancy and hyperplasia, Coagulopathy, Ovulatory dysfunction, Endometrial, Iatrogenic, and Not otherwise classified.

The two most common histopathological diagnoses reported for hysterectomy specimens of AUB are adenomyosis and leiomyoma. Leiomyoma are the most frequent benign uterine tumors that develop during a woman's reproductive years; occurrence tends to regress after menopause [6]. Adenomyosis is another common condition detected in hysterectomy specimens. It is characterized by the presence of endometrial glands and stroma within the myometrium. Patients are typically pre or perimenopausal women who present with abnormal bleeding [7].

In our study, ($n = 194$) of the patients with AUB belonged to the 41-50 years age group. In a cross-sectional retrospective study Kim and Strawn [8] reported that the uterine samples of 64 patients out of the 182 participants (35.2%) had adenomyosis. These patients were in the age range of 25–52 years. In our study, adenomyosis was most prevalent in the age group of 41-50 years, which was in agreement with the previous studies. The overall prevalence of adenomyosis was determined to be 46.78%, which was, however, higher than those of the previous studies [8, 9] whereas leiomyoma was found in 87 cases (39.9%). Isaoglu *et al.* [10] found that 30.23% of the hysterectomy cases were diagnosed as adenomyosis whereas leiomyoma constituted (28.19%) cases of hysterectomy in AUB.

Diagnosis of adenomyosis on clinical findings is usually different. Transabdominal ultrasonography doesn't allow reliable diagnosis of adenomyosis, even transvaginal ultrasonography has limitation in tissue characterization [11]. MRI is more helpful to diagnose adenomyosis but is expensive, whereas it is very useful diagnostic tool in cases with fibroid uterus. Out 94 cases diagnosed as leiomyoma on

USG 91 were confirmed histologically and whereas only 96 cases of 102 diagnosed on USG as adenomyosis were confirmed histologically.

Our study was done on 218 patients. Larger sample size will have a better correlation of the clinical, radiological & histopathological findings.

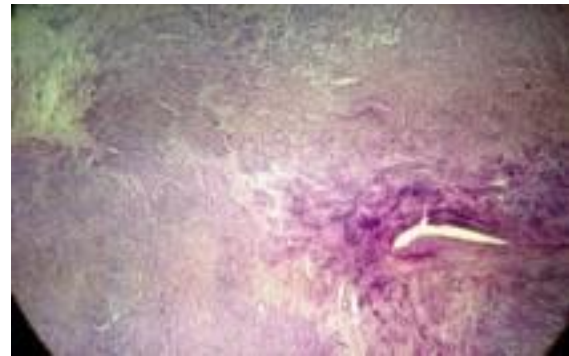

Fig C: Showing leiomyoma

IV. CONCLUSION

In our study, adenomyosis was found to be the most common histopathological finding followed by fibroid. and the cause of AUB in perimenopausal women. Clinical, radiological and histopathological findings correlated well to diagnose fibroid but was of little help in diagnosing adenomyosis. Despite this, adenomyosis still remains a clinical challenge. Nevertheless, the possibility of this lesion has to be kept in mind by both the clinician, as well as the pathologist in women with AUB. AUB in perimenopausal age is alarming and needs thorough evaluation since this could be a considerable clinical significance, because of its relationship with hyperplasias and malignancies of the endometrium.

V. REFERENCE

1. Munro MG, Critchley HO, Broder MS, Fraser IS; FIGO classification system (PALM-COEIN) for causes of abnormal uterine bleeding in nonpregnant women of reproductive age. FIGO Working Group on Menstrual Disorders. *Int J*

Gynaecol Obstet., 2011; 113: 3– 13.

2. Diagnosis of abnormal uterine bleeding in reproductive-aged women. Practice Bulletin No.128. American College of Obstetricians and Gynecologists. Obstet Gynecol., 2012; 120: 197-206D

3. Dueholm M. Transvaginal ultrasound for diagnosis of adenomyosis : A review. Best Pract Res Clin Obstet Gynaecol 2006; 20: 569-82.D

4. Day Baird D, Dunson DB, Hill MC, Cousins D, Schectman JM. High cumulative incidence of uterine leiomyoma in black and white women: Ultrasound evidence. Am J Obstet Gynecol 2003; 188: 100-7.

5. Bhosle A, Fonseca M; Evaluation and histopathological correlation of abnormal uterine bleeding in perimenopausal women. Bombay Hosp J., 2010; 52: 69–72.

6. Moutinho JAF, Barbosa LG, Torres DG, N study. Abnormal uterine bleeding as a presenting symptom is related to multiple uterine leiomyoma: an ultrasound-based study. Int J Womens Health, 2013; 5: 689–694.

7. Rizvi G, Pandey H, Pant H, Chufal SS, Pant P; Histopathological correlation of adenomyosis and leiomyoma in hysterectomy specimens as the cause of abnormal uterine bleeding in women in different age groups in the Kumaon region: A retrospective study. J Midlife Health, 2013; 4(1): 27–30

8. Kim J, Strawn EW Jr.; Adenomyosis: A frequent cause of abnormal uterine bleeding. Obstet Gynecol., 2000; 95: S23.

9. Bergeron C, Amant F, Ferenczy A; Pathology and physiopathology of adenomyosis. Best Pract

Res Clin Obstet Gynaecol., 2006; 20: 511–521.

10. Isaoğlu U; The Evaluation of histopathologic diagnosis in specimens of hysterectomy. Abant Med J. 2013; 2(2): 91-943

11. Michail G, Karahaliou A, Skiadopoulos S, Kalogeropoulou C, Terzis G, Boniatis I *et al.*; Texture analysis of perimenopausal & postmenopausal endometrial tissue in grayscale transvaginal ultrasonography. British J Radiol., 2007; 80(956): 609-616.

12. Rizvi G, Pandey H, Pant H, Chufal SS, Pant P. Histopathological correlation of adenomyosis and leiomyoma in hysterectomy specimens as the cause of abnormal uterine bleeding in women in different age groups in the Kumaon region: A retrospective study. J Mid-life Health 2013; 4: 27-30