

International Journal Of Medical Science And Clinical Inventions

Volume 3 issue 9 2016 page no. 2163-2167 e-ISSN: 2348-991X p-ISSN: 2454-9576

Available Online At: <http://valleyinternational.net/index.php/our-jou/ijmsci>

Duck egg size epidermoid cyst in the floor of mouth: A rare entity

Vaibhav Shukla¹, Anmol Agarwal², Uday Kiran Uppada³, Gaurav Mittal⁴

¹Consultant Oral & Maxillofacial Surgeon, Savitri Dental Hospital and Maxillofacial Centre, Allahabad, Uttar Pradesh, India.

²Associate Professor, Department of Oral and Maxillofacial Surgery, Institute of Dental Studies and Technologies, Modinagar, Uttar Pradesh, India

³Assistant Professor, Department of Oral and Maxillofacial Surgery, Sri Sai College of Dental Surgery, Vikarabad, Telangana, India

⁴Professor & Head, Department of Oral and Maxillofacial Surgery, Institute of Dental Studies and Technologies, Modinagar, Uttar Pradesh, India

Corresponding author : Anmol Agarwal

Associate Professor, Department of Oral & Maxillofacial Surgery, Institute of Dental Studies and Technologies, Modinagar, Uttar Pradesh, India

Abstract: Epidermoid cysts that appear in the midline of the head & neck are, usually, a result of entrapped ectodermal tissue of the first and second branchial arches, which fuse during the third and fourth weeks in utero. The incidence in the floor of the mouth of the oral cavity is very rare. We report a case of a large sublingual epidermoid cyst in a young male patient with emphasis on the management.

Introduction

Epidermoid cysts are cystic malformations encountered throughout the body, with 7% occurring in the head and neck and 1.6% within the oral cavity.^{1, 2, 3} They represent less than 0.01% of all oral cavity cysts.^{1, 2, 4} Epidermoid cyst is lined by a simple squamous epithelium. Histological variants of an epidermoid cyst include dermoid and teratoid. Dermoid cysts possess skin adnexa in their cyst wall, while teratoid exhibit other tissues such as muscle, cartilage and bone.^{5, 6, 7} All these three cysts owing to their squamous epithelium lining may enclose cheesy keratinaceous material within their lumen.⁴ Epidermoid cysts are believed to be most common variant with teratoid cysts being least common. They are generally found in sites where embryonic parts fuse together.⁸ Majority of the reported cases are in the midline of the body.

In the oral cavity, it occurs most frequently in the area of the floor of mouth and may also occur on the tongue, lips or in the jaws. We report a case in which a 25-year-old male patient developed an epidermoid cyst presenting as a large sublingual swelling causing speech and swallowing difficulties.

Case Report

A 25-year old male patient presented with a swelling below his tongue since 3 months. Medical history was noncontributory. The patient could not say precisely when the lesion initially developed, but reported speech and swallowing difficulties for the past 3 months. Extra oral examination was insignificant and lymph nodes were not palpable. Intraoral examination revealed a 5 cm × 5 cm, sessile, non-ulcerated, smooth-surfaced, normal

coloured, well-defined sublingual swelling occupying the entire floor of the mouth (Fig. 1).

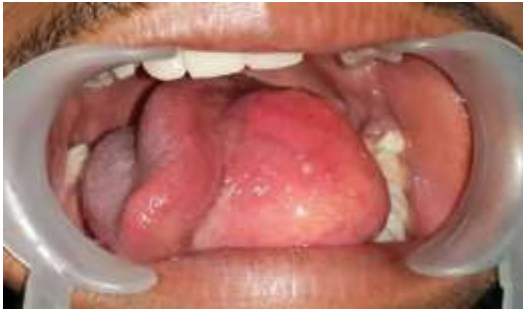

Figure 1: Preoperative view of the lesion

The lesion was slightly movable, rubbery and painless on palpation. No additional mucosal lesions were present. CT scan revealed a well-defined cystic lesion in the floor of the mouth suggestive of an epidermoid cyst or a bronchogenic cyst (Fig. 2).

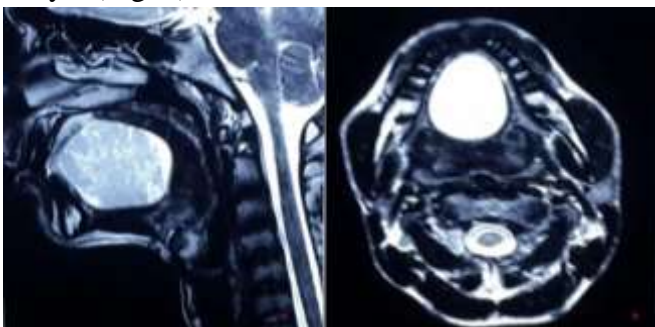


Figure 2: CT scan show the extent of the lesion

Fine needle aspiration was performed. This revealed a keratin-containing liquid. Based on the anatomical location of the lesion, its clinical and radiological presentation and in addition to the type of aspirate obtained, we arrived to a provisional diagnosis of an epidermoid cyst.

Surgical excision of the lesion was planned under general anesthesia. An intraoral midline incision from the base of the tongue to the floor of the mouth was used to access the lesion (Fig. 3).

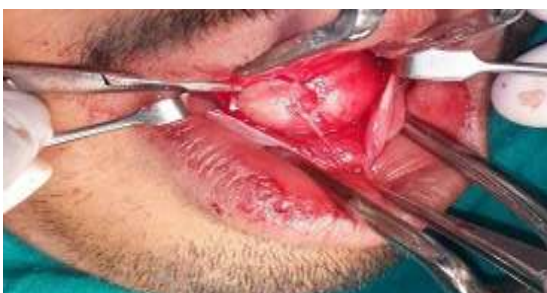

Figure 3: Intraoperative view showing exposure of the lesion

Special attention was paid to protect the Wharton's ducts bilaterally. The cyst was completely exposed and on evaluation partial caudal herniation through the mylohyoid muscle was seen. A combination of sharp and blunt dissection was used to free the cyst with traction and counter-traction. Finally the entire lesion was removed intact. Wound was closed in layers and a non-vacuum drain was kept in situ for 24 hrs.

Macroscopically, the lesion appeared encapsulated and contained a keratin like yellow material (Fig. 4).

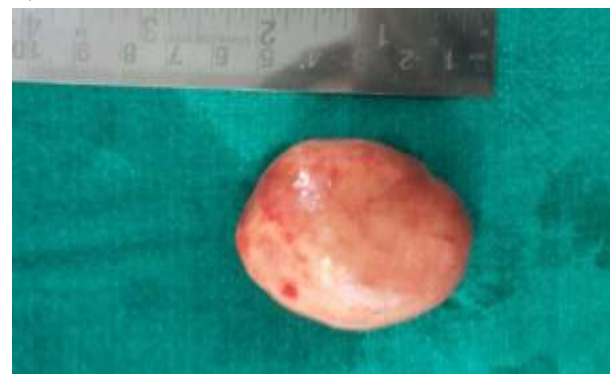

Figure 4: Excised lesion

Microscopic examination revealed a cystic cavity lined with orthokeratinized squamous epithelium, with keratin in the lumen. The cyst wall was composed of fibrous connective tissue. Skin appendages, such as sebaceous glands, hair follicles and sweat glands, were absent (Fig. 5).

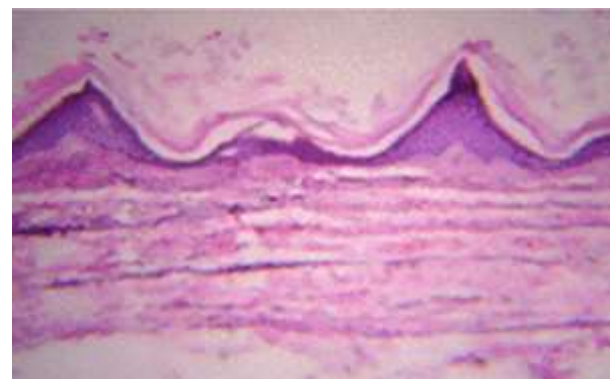


Figure 5: Histopathological view of the excised lesion

Final histologic diagnosis was dermoid cyst of the epidermoid type. The patient was followed for 1 year without any signs of recurrence.

Discussion

Numerous etiopathogenetical theories have been proposed to expound the development of epidermoid cyst. Few authors have categorized these cysts into congenital and acquired. Those which are congenitally present are presumed to be dysembryogenetic lesions that arise from ectodermic elements entrapped during the midline fusion of the first and second branchial arches between the third and fourth week of intrauterine life. Instead, they may arise from the tuberculum impar of His which, with each mandibular arch forms the floor of the mouth and the body of the tongue. Acquired cysts derive from traumatic or iatrogenic inclusion of epithelial cells or from the occlusion of a sebaceous gland duct. Some authors proposed that midline cysts may represent a variant form of thyroglossal duct cyst.⁹

Clinically, the lesion presents as a slow-growing asymptomatic mass, usually located in the midline, above or below the mylohyoid muscle. Growth of the cyst may be constrained by hormonal stimulus during puberty, producing a hypersecretion of fat, which would explain the greater incidence in the young adult stage.¹⁰ When located above the muscle, the cyst manifests itself as a sublingual swelling and when located below the muscle, it manifests as a sub mental swelling. Its size may vary from a few millimeters to even 10 centimeters. Depending on the size of the lesion, it can displace the tongue and cause dysphagia, dysphonia, and dyspnea.

In our case, the possibility of infection was discarded due to the period of evolution and the absence of pain and of intraoral infectious foci. Malignant tumour was ruled out in view of the lesion's clinical aspect and the absence of lymphadenopathy. Since the clinical aspect was compatible with ranula and because ranulas are far more common than dermoid cysts, this was our first op-

tion in the list of our differential diagnosis. Later, on collection of keratin-containing fluid through aspiratory puncture, a dermoid cyst became the more plausible choice.

Differential diagnosis of sublingual lesions includes ranula, mucocele, cystic hygroma, brachial cleft cyst, lymphangioma, lymphoepithelial cyst, infectious conditions, heterotopic gastrointestinal cyst and duplication foregut cyst and thyroglossal duct cyst.¹¹

Bimanual palpation and conventional radiography are not always adequate in arriving at proper diagnoses. It is essential to use ultrasonography, CT or MRI together with cytologic examination by FNA.¹¹ Since it is reliable, economical and eradicates x-ray exposure ultrasonography represents the first choice of imaging technique. It is specifically suitable for young patients. CT and MRI allow more precise localization of the lesion in relationship to geniohyoid & mylohyoid muscles and they also enable the surgeon to choose the most appropriate surgical approach, especially for very large lesions. MRI is superior to CT in terms of soft-tissue resolution and better ability to depict the internal structure of a mass lesion. Fine-needle aspiration is a safe, cost-effective and reliable tool for preoperative diagnosis of dermoid cysts. Nevertheless, the clinical & radiological diagnosis should be confirmed with the histological examination specifically to determine the specific histologic subtype.

Surgical enucleation is an effective treatment for these kinds of lesions. Marsupialization has also been proposed as a treatment alternative in cases of giant cysts. An untreated epidermoid cyst can achieve large proportions, causing discomfort during mastication, swallowing, and speaking. However, there is no universally accepted protocol pertaining to the timing for surgical intervention. Since these cysts are mainly congenital, they can appear at any phase of life. Hence, the time when they grow significantly large to cause functional disability like dysphagia, dysphonia, and dyspnea

is generally the right time for surgical intervention.

When the lesion is approached intraorally, a midline vertical mucosal incision is performed along the ventral surface of the tongue. However, this can be employed only for small cysts less than 6cm.^{11, 12} Lowry et al.¹³ describe a bilateral incision along the mandibular ridge crest, Brusati et al.¹⁴ propose a midline glossotomy, and Di Francesco et al.¹⁵ describe a modification of this surgical technique consisting of an extension of this incision along the ventral surface of the tongue associated with partial evacuation of the epidermoid cyst.

The extraoral approach is generally preferred in the case of median geniohyoid or very large sublingual cysts. The transcutaneous approach consists of a submental incision and a sharp, blunt dissection to reach and enucleate the lesion.¹³ McGregor describes a symphyseal mandibular osteotomy to enucleate a very large sublingual dermoid cyst.¹⁶

Hemorrhage and hematoma formation are the only complications following surgical intervention which could lead to significant swelling and edema of the floor of mouth and tongue, resulting in respiratory distress and airway obstruction from elevation of the tongue against the palatal vault. Prognosis is generally good with a very low incidence of relapse, usually related to the genial tubercles or to the hyoid bone. Malignant transformation rate of 5% is reported for oral dermoid cysts of the teratoid type.¹⁷

Conclusion

Sublingual epidermoid cysts can be managed by surgical excision through an intraoral approach to render a very good cosmetic and functional result. The extraoral incision can be employed when the cyst lies under the geniohyoid muscle. Prognosis is generally good with a very low incidence of recurrence.

References

- 1) Koca H, Seckin T, Sipahi A, Kaznac A: Epidermoid cyst in the floor of the mouth: report of a case. *Quintessence Int* 2007, 38:473-477
- 2) Ozan F, Polat HB, Ay S, Goze F: Epidermoid cyst of the buccal mucosa: A case report. *J Contemp, Dent Pract* 2007, 3:90-96.
- 3) F. S. De Ponte, A. Brunelli, E. Marchetti, and D. J. Bottini, Sublingual epidermoid cyst. *Journal of Craniofacial Surgery*. 2002;13, 308–310.
- 4) Kandogan T, Koc M, Vardar E, Selek E, Sezgin O. Sublingual Epidermoid Cyst: A Case Report. *Journal of Medical Case Reports* 2007, 87: 1-4
- 5) I. Meyer. Dermoid cysts of the floor of the mouth. *Oral Surg, Oral Med, Oral Path.* 1955; 8, 1149–1164.
- 6) H. P. Philipsen and P. A. Reichart, “Revision of the 1992-edition of the WHO histological typing of odontogenic tumours. A suggestion,” *Journal of Oral Pathology and Medicine*. 2002; 31, 253–258.
- 7) M. Milam, S. A. Hill, and J. M. Manaligod, “Lingual dermoid cysts,” *Otolaryngology: Head and Neck Surgery*, 2003; 128, 428–429.
- 8) Vieira et al. Unusual Dermoid Cyst in Oral Cavity. *Case Reports in Pathology* 2014; 1- 3
- 9) Patrick J, Louis , Hudson Clint, Reddi S: Lesion of Floor of the Mouth. *J Oral Maxillofac Surg* 2002, 60:804-807
- 10) Vargas Fernandez JL, Lorenzo Rojas J, Aneiros Fernandez J, Sainz Quevedo M: Dermoid cyst of the floor of the mouth. *Acta Otorrinolaringol Esp* 2007, 58:31-33
- 11) Ohta N et al. A Case of Sublingual Dermoid Cyst: Extending the Limits of the Oral Approach. 2012; 1 – 4

- 12) Walstad WR, Solomon JM, Schow SR, Ochs MW: Midline cystic lesion of the floor of the mouth. *J Oral Maxillofac Surg* 1998, 56:70-74
- 13) Lowry RE, Tempero RM, Davis LF: Epidermoid cyst of the floor of the mouth. *J Oral Surg* 1979, 37:271-273.
- 14) Brusati R, Galioto S, Tullio A, Moscato G: The midline sagittal glossotomy for treatment of dermoid cysts of the mouth floor. *J Oral Maxillofac Surg* 1991, 49:875-878.
- 15) Di Fransesco A, Chiapasco M, Biglioli F, Ancona D: Intraoral approach to large dermoid cysts of the floor of the mouth: A technical note. *Int J Oral Maxillofac Surg* 1995, 24:233-235.
- 16) McGregor IA: Symphyseal mandibular osteotomy in the approach to sublingual dermoid cyst. *Br J Plast Surg* 1991, 44:544-545
- 17) Zachariades N, Skoura-Kafoussia C: A life threatening epidermoid cyst of the floor of the mouth: Report of a case. *J Oral Maxillofac Surg* 1990, 48:400.
- 18) Correa MSSN, Fonoff RDN, Ruschel HC, Parizotto SP, Correa FNP. Lingual Epidermoid Cyst: Case Report in an Infant. *Pediatric Dentistry* 2003; 25:591 – 593
- 19) Jham BC, Duraes GV, Jham AC, Santos CR. Epidermoid Cyst of the Floor of the Mouth: A Case Report. *J Can Dent Assoc.* 2007;73:525-528.