

International Journal Of Medical Science And Clinical Inventions

Volume3 issue 11 2016 page no. 2389-2393 e-ISSN: 2348-991X p-ISSN: 2454-9576

AvailableOnlineAt:<http://valleyinternational.net/index.php/our-jou/ijmsci>

Acute exacerbation of thrombocytopenia by Cefotaxime in a case of pancytopenia due to Vitamin B12 deficiency

Robin George Manappallil¹, Jishnu Jayaraj²

¹Consultant – Physician, Department of Internal Medicine, Baby Memorial Hospital, Calicut, Kerala, India

²Medicine Resident, Department of Internal Medicine, Baby Memorial Hospital, Calicut, Kerala, India

Corresponding Author: Robin George Manappallil

Consultant – Physician, Department of Internal Medicine, Baby Memorial Hospital, Calicut 673004, Kerala, India

ABSTRACT: *Cefotaxime is a third generation cephalosporin with good coverage against gram negative organisms. Anaphylaxis is a commonly reported adverse effect. This is a case of a middle aged lady who presented with fatigue and was diagnosed to have pancytopenia due to vitamin B12 deficiency. She had an associated urinary tract infection. Cefotaxime was started for the infection, following which she developed severe thrombocytopenia. Drug induced thrombocytopenia is an unpublicized adverse effect of cefotaxime.*

KEYWORDS: *Cefotaxime, Drug induced thrombocytopenia*

INTRODUCTION

Cefotaxime, a third generation cephalosporin, has an increased activity against gram negative bacilli and less against gram positive cocci. The risk of anaphylaxis has been reported with cefotaxime.¹ Drug induced thrombocytopenia (DITP), to the best of our knowledge, is an unrecognized adverse effect of cefotaxime.

CASE REPORT

This is a case of a 54 year old lady, homemaker, who presented to the Medicine OPD with history of fatigue, which has been progressive for the past 1 year. She also had low grade fever for 2 days, associated with mild burning micturition. She did not have any comorbid condition and was not on any regular medications. She was not a vegetarian by diet. She had history of urinary tract infection about 2 years ago and was treated with intravenous antibiotics (details unknown).

On examination, she was conscious, oriented and afebrile; with a heart rate of 100 beats/minute, blood pressure of 110/70 mmHg (no postural drop) and respiratory rate of 20 breaths/minute.

She was moderately built and nourished; and was pale. Her systemic examinations were normal.

Her complete blood count showed pancytopenia; with haemoglobin 5.9 g%, total counts 3800/ cmm (N18 L82) and platelets 79000/cmm. Her mean corpuscular volume was 124 fL and peripheral smear showed pancytopenia with macrocytes. Her iron studies and folic acid levels were normal but Vitamin B12 levels were decreased (43 pg/mL). Bone marrow examination was suggestive of megaloblastic anaemia. Her renal and liver functions, prothromin time and activated partial thromboplastin time were normal. Viral markers for hepatitis B, hepatitis C and HIV, dengue serology, malarial smear and blood cultures were negative. Chest Xray, ECG and abdominal ultrasound were normal. Upper GI endoscopy showed mild antral gastritis and rapid urease test was negative. Her anti-parietal cell antibodies were positive.

She was started on pantoprazole and hydroxycobalamin intramuscular injections (1000 mcg every third day). She was also given two units of packed cell transfusion. By day 2 of

admission haemoglobin became 9g%, total counts 4200/ cmm and platelets 90000/cmm.

Her urine microscopy showed numerous pus cells and culture grew *Escherichia coli* (>100,000 CFU/mL). On day 4, she was started on intravenous Cefotaxime (1 gram q8h), as per culture and sensitivity report. Following the initiation of Cefotaxime, her platelet counts started showing a decline; suggestive of a drug induced thrombocytopenia. Cefotaxime was withheld and within 2 days her platelet count started rising. The pattern of her platelet count levels has been depicted in Figure 1. She was discharged on day 12 of admission with a haemoglobin of 9.5g%, total counts 5200/cmm and platelet counts of 110000/cmm. She was given tablet ciprofloxacin (as per culture and sensitivity report) for her urinary infection. She was advised weekly hydroxycobalamin intramuscular injections for 2 months, followed by once monthly injection. She was reviewed after 1 week and 1 month and had a stable complete blood count.

DISCUSSION

The haematological manifestations of vitamin B12 deficiency are macrocytic megaloblastic anaemia and, in rare cases, severe thrombocytopenia.² There have been reports of pancytopenia due to vitamin B12 deficiency.^{3,4}

Platelets play a major role in maintaining blood hemostasis. These platelets have an average life span of 7-10 days.⁵ Thrombocytopenia is defined as a platelet count below 150,000/ μ L.⁶ Drug induced thrombocytopenia (DITP) is an acute, immune-mediated thrombocytopenia which can be induced by drugs, foods, beverages and herbal products. DITP typically presents 5 to 10 days after daily administration of the culprit drug, or within hours after re-exposure to the drug that was taken previously for a period of time. Several mechanisms have been outlined in the pathogenesis of DITP. One of the commonest forms is heparin induced thrombocytopenia, which occurs due to thrombosis.⁷ In case of drugs like quinine, drug dependent antibodies are formed that react directly with the sensitizing drug to form an immune complex; which in turn reacts

with the platelets leading to its destruction.⁸ Drugs like penicillin trigger a humoral immune response when they are linked to a macromolecule like a protein, which in turn act as a hapten.⁹ GPIIb/IIIa inhibitors like tirofiban and eptifibatid can cause thrombocytopenia by formation of antibodies that recognize GPIIb/IIIa in a complex with the particular ligand-mimetic.¹⁰ Platelet-specific autoantibodies are produced by medications like L-dopa, penicillamine and sulfamethoxazole, thereby leading to a clinical picture similar to autoimmune thrombocytopenia.¹¹ Chemotherapeutic drugs cause generalized myelosuppression,¹² while non-immune platelet destruction has been observed with drugs like bleomycin.¹³ The mechanism of thrombocytopenia by thiazide diuretics is either by an immune mediated mechanism or by selective suppression of megakaryocyte production.¹⁴

DITP should be suspected in cases of unexplained and recurrent thrombocytopenia. A systematic review and list of drugs causing thrombocytopenia along with criteria for individual patient evaluation are available at www.ouhsc.edu/platelets. Our patient had fulfilled 3 out of the 4 criteria, suggestive of probable DITP.

Platelet-reactive antibodies induced by drugs can be detected by flow cytometry, platelet immunofluorescence test, enzyme-linked immunospecific assay and immunoprecipitation-Western blotting. Infectious causes like hepatitis B and C, HIV and *H. pylori* should be ruled out. SLE, multiple myeloma and Evan's syndrome should also be considered. Bone marrow examination can be reserved for those who have features not resembling DITP and those who do not respond to conventional therapy.

The management of DITP mainly involves the complete withdrawal of the culprit drug; following which the recovery of thrombocytopenia is expected within 1 to 2 days. Platelet transfusions should be given only in cases of severe thrombocytopenia where there are high chances of bleeding. The role of corticosteroids is controversial.¹⁵ There has been no proven benefits with the use of intravenous immunoglobulins and plasma exchange in cases of persistent thrombocytopenia and bleeding.^{16,17}

Cephalosporins are semisynthetic drugs, derived from the species *Cephalosporium*. Cefotaxime belongs to third generation cephalosporins, and has good gram negative coverage. Hypersensitivity reactions and disulfuram like reactions are some of the adverse effects of cephalosporins.¹ There have been reports of thrombocytopenia with cephalothin, cefuroxime and ceftriaxone therapy.¹⁸⁻²⁰ However, DITP due to cefotaxime, has not been reported yet.

CONCLUSION

Cefotaxime is a third generation cephalosporin used mainly in the treatment of gram negative infections. Hypersensitivity reaction is a common adverse effect. Our patient developed thrombocytopenia following administration of cefotaxime. She had history of urinary infection in the past, and probably cefotaxime was used that time. In that case, she developed DITP as a re-exposure phenomenon. DITP following cefotaxime use is a rare complication; and to the best of our knowledge, has not been reported yet.

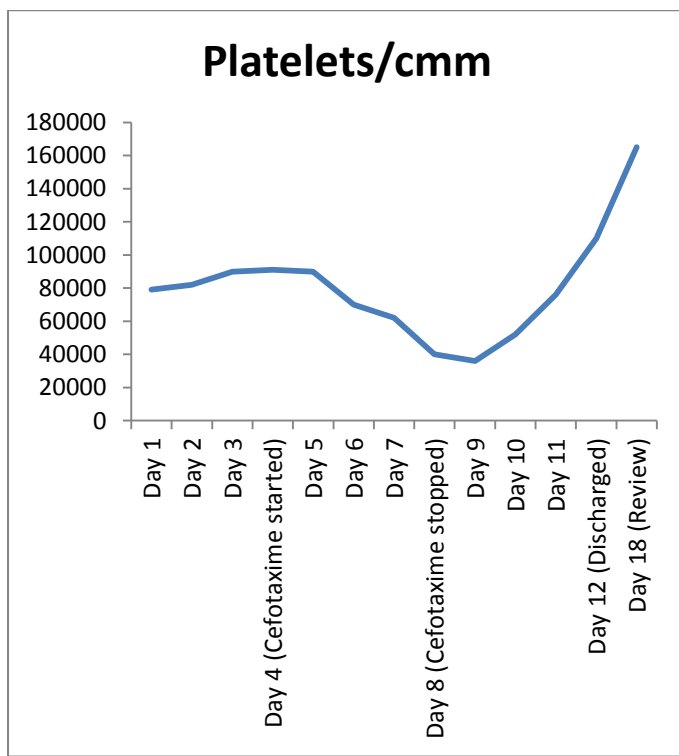


Figure 1. Course of Platelet count

REFERENCES

1. Brenner GM and Stevens CW. Pharmacology. 3rd ed. pp 431-432.
2. Renu S, Hara PP and Manoranjan M. de Gruchy’s Clinical Haematology in Medical Practice. 6th ed. pp 62-63.
3. Halfdanarson TR, Walker JA, Litzow MR, Hanson CA. Severe vitamin B12 deficiency resulting in pancytopenia, splenomegaly and leukoerythroblastosis. Eur J Haematol. 2008; 80(5):448-51.
4. Anitha P, Sasitharan R, Thambarasi T, Krithika P, Mohan M, Venkataraman P et al. Vitamin B12 deficiency presenting as pancytopenia and retinopathy in a young boy—*Helicobacter pylori*, a novel causative agent. The Australasian Medical Journal. 2014;7(3):143-148.
5. Barbara AK. Disorders of platelets and vessel wall. In: Kasper, Fauci, Hauser, Longo, Jameson, Loscalzo eds. Harrison’s principles of internal medicine. 19th ed. McGraw Hill education 2015, 725-729.
6. Renu S, Hara PP and Manoranjan M. de Gruchy’s clinical haematology in medical practice. 6th ed. 349-359.
7. Davoren A and Aster RH. Heparin-induced thrombocytopenia and thrombosis. Am J Hematol 2006; 81:36-44.
8. Shulman NR. A Mechanism of Cell Destruction in Individuals Sensitized to Foreign Antigens and Its Implications in Auto-Immunity. Combined Clinical Staff Conference at the National Institutes of Health. Ann Intern Med 1964; 60:506–521.
9. Murphy MF, Riordan T, Minchinton RM, Chapman JF, Amess JA, Shaw EJ, et al. Demonstration of an immunemediated mechanism of penicillin-induced neutropenia and thrombocytopenia. Br J Haematol 1983; 55:155-160.
10. Bougie DW, Wilker PR, Wuitschick ED, Curtis BR, Malik M, Levine S, et al. Acute thrombocytopenia after treatment with tirofiban or eptifibatide is associated with antibodies specific for ligand-occupied GPIIb/IIIa. Blood 2002; 100:2071-2076.

11. Aster RH. Can drugs cause autoimmune thrombocytopenic purpura? *Semin Hematol* 2000; 37:229-238.
12. Carey PJ. Drug-induced myelosuppression: diagnosis and management. *Drug Saf* 2003; 26:691-706.
13. Majhail NS and Lichtin AE. What is the best way to determine if thrombocytopenia in a patient on multiple medications is drug induced? *Cleve Clin J Med* 2002; 69:259-262.
14. Eisner EV and Crowell EB. Hydrochlorothiazide-dependent thrombocytopenia due to IgM antibody. *JAMA* 1971; 215:480-482.
15. George JN and Aster RH. Drug-induced thrombocytopenia: pathogenesis, evaluation, and management. *Hematology Am Soc Hematol Educ Program* 2009:153-158.
16. Ray JB, Brereton WF and Nullet FR. Intravenous immune globulin for the treatment of presumed quinidine-induced thrombocytopenia. *DICP* 1990; 24:693-695.
17. Pourrat O. Treatment of drug-related diseases by plasma exchanges. *Ann Med Interne (Paris)* 1994; 145:357-360.
18. Lown JA, Barr AL. Immune thrombocytopenia induced by cephalosporins specific for thiomethyltetrazole side chain. *Journal of Clinical Pathology*. 1987;40(6):700-701.
19. Aitken P, Zaidi SM. *Postgrad Med J*. 1996 Dec; 72(854):757-8.
20. Grossjohann B, Eichler P, Greinacher A, Santoso S, Kroll H. Ceftriaxone causes drug-induced immune thrombocytopenia and hemolytic anemia: characterization of targets on platelets and red blood cells. *Transfusion*. 2004 Jul; 44(7):1033-40.