

## **Xanthogranulomatous pyelonephritis-An unusual form of chronic pyelonephritis**

**<sup>1</sup>Dr G Sudhakar , <sup>2</sup>Dr.R.Sasank, <sup>3</sup>Dr.B.Vani, Dr Sarath Gupta**

<sup>1</sup>Assistant Professor, Department of pathology, Siddhartha Medical College,  
Vijayawada 521108, INDIA

E-mail: drgsudhakarjournals@gmail.com,

<sup>2</sup>Professor, Department of pathology, Siddhartha Medical College,  
Vijayawada-520008,India

E-mail: [drsasank@gmail.com](mailto:drsasank@gmail.com),

<sup>3</sup>Post graduate, Department of pathology, Siddhartha Medical College,  
Vijayawada504001,India

E-mail-dr.vani61@gmail.com.

<sup>4</sup>Consultant, Venkata ramana nursing home, Kurnool road, Ongole-India

E-mail:sharathsetty@gmail.com,

**Corresponding author: \*Dr G Sudhakar M. D (Pathology)**

Assistant Professor, Department of pathology, Siddhartha Medical College,Vijayawada

Address: Flat No-105, Krishna Residency,

Sri pingali Venkaiah Street, Ramavarappadu,

Vijayawada-521108, INDIA

E-mail: drgsudhakarjournals@gmail.com, Mobile no: 09440703634

### **Abstract:**

Xanthogranulomatous pyelonephritis (XGP) is a rare, severe and atypical form of chronic pyelonephritis that results in replacement of renal and/or perirenal tissue with a diffuse infiltrate of inflammatory cells referred to as xanthoma cells. We present a case of 55year old female with xanthogranulomatous pyelonephritis. The lesion is unique among the all other inflammatory conditions and closely mimics renal tumours with its tumour like clinical behaviour. It can affect either kidney with equal frequency and can spread to involve and/or destroy adjacent organs

### **Key words:**

Inflammatory lesion, Lipid laden foamy macrophages, tumour like behaviour, Xanthogranulomatous pyelonephritis.

### **Intoduction:**

Xanthogranulomatous pyelonephritis is a rare and aggressive form of chronic pyelonephritis characterised by accumulation of lipid-laden foamy macrophages and destruction of renal parenchyma resulting in a non-functioning kidney.

This entity was first described by Schlagenhauser in 1916. It has an incidence of 1.4cases/ 1,00,000 population.<sup>[1]</sup> and is believed to result from an atypical, incomplete immune response to sub-acute bacterial infection.<sup>[1,2]</sup>. Because of its tumour like clinical behaviour it stands unique

among the all other inflammatory conditions and requires histological diagnosis.

#### Case report:

A 55 years old female presented with complaints of malaise, low grade fever, weight loss, dull flank pain and haematuria since 3 weeks. Ultrasound examination has revealed enlarged left kidney with ill defined renal out line and loss of normal renal architecture with perinephric shadows. CT findings were loss of normal renal outline with few calculi. Intravenous pyelography was showing non functioning left kidney with few renal calculi. Laboratory investigations were non specific except leukocytosis and positive urinary culture for E.coli.

Left nephrectomy was done and on gross examination, nephrectomy specimen was measuring 9×5×4 cms. External surface is nodular, yellowish to dark brown with fibrous bands. Cut section, the calices are dilated with loss of papillae and the expanded calices are lined by yellowish zone that is friable on inner aspect(Figure 1).

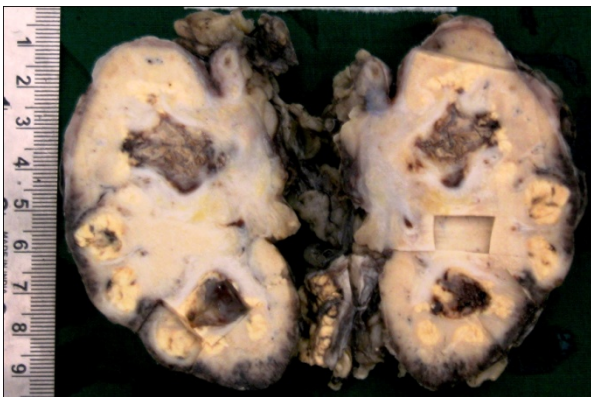


Figure 1: Cut section, the calices are dilated with loss of papillae and friable yellowish zone.

The parenchyma contains similar foci of yellowish material, while the rest of it is brownish and firm owing to fibrosis and cellular infiltration.

Microscopic examination of the yellow areas shows admixture of large, finely granular lipid containing foam cells and smaller macrophages containing coarser granules (Figure 2).

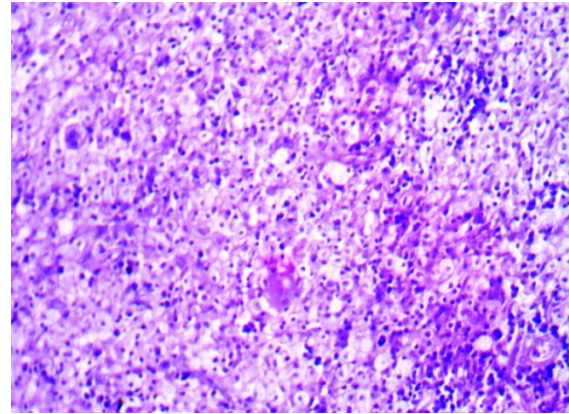


Figure 2: Large, finely granular lipid containing foam cells and smaller macrophages containing coarser granules ( H and E, ×200).

In the outer parts of yellow zone and in the adjacent parenchyma are lymphocytes, plasma cells, eosinophils along with fibroblasts. Fibrosis in the outer areas also shows multinucleated giant cells(Figure 3).

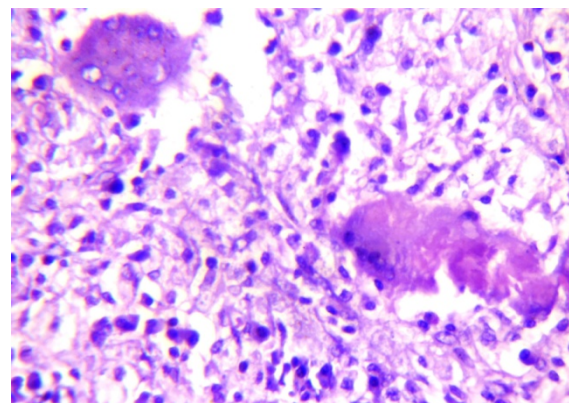


Figure 3: Foamy macrophages and multinucleated giant cells ( H and E, ×400).

The overlying cortex was showing chronic inflammation. Tubular loss is profound and glomeruli are remarkably normal at unaffected areas(Figure 4).

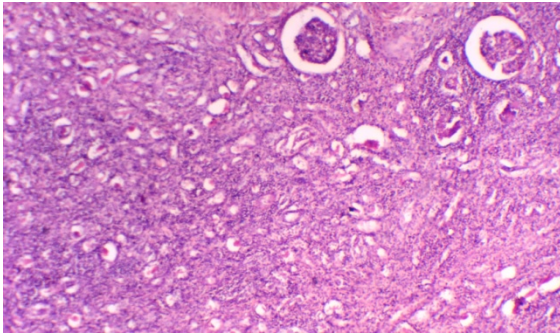


Figure 4: Tubular loss is profound and glomeruli are remarkably normal at unaffected areas( H and E,  $\times 200$ ).

### Discussion:

Xanthogranulomatous pyelonephritis is generally unilateral, and both right and left kidneys are involved with equal frequency. Occasionally it is bilateral. It is diffuse in 80-90% and focal in 10-20% of cases.<sup>[1,2]</sup> It occurs most often in adult females with ratio of 4:1 when compared with males. Patients are usually in 50's to 70's and have long history of recurrent UTI.<sup>[3]</sup> The most common organisms implicated to cause infection are *Proteus mirabilis* and *E.coli*. Some cases occur in association with renal pelvic calculus (Staghorn calculus), post-radiation strictures, congenital pelviureteric stenosis and tumours, where obstruction is a contributing factor. General symptoms include low-grade fever, malaise, chills, anorexia and weight loss. Non-specific urinary symptoms include flank pain and haematuria. Pyuria, positive urinary cultures are present in 95% to 60% of cases.<sup>[4]</sup> By the time xanthogranulomatous pyelonephritis has become established, no conservative or medical therapies exist. Surgical nephrectomy is usually curative. Reversible hepatic dysfunction has been observed in one third of patients with diffuse involvement.<sup>[4]</sup>

Malek and Elder classified XGP into three stages-Stage-1: The lesion is confined to renal parenchyma; Stage-2: Involving the peri-renal space; Stage-3: Extension to the peri-renal and para-renal spaces.<sup>[5,6,7]</sup> It has tumour-like behaviour and can spread to involve and destroy adjacent organs. Extensive renal and adjacent tissue damage may develop, such as renocolic fistula, psoas abscess, nephrocutaneous

fistula, and paranephric abscess.<sup>[8,9,10]</sup> Up to 80.5% of the affected kidneys were non-functioning.<sup>[11]</sup>

On macroscopic examination kidney is enlarged with peri renal fibrosis in severe cases. Microscopic examination shows admixture of large finely granular foam cells and smaller macrophages containing coarser granules. There are also foreign body giant cells and fibrosis seen.<sup>[1,10,11]</sup>

Liesegang Rings are rare histological finding in inflammatory diseases like Xanthogranulomatous pyelonephritis. They are concentric noncellular lamellar structures formed due to accumulation of insoluble products in colloidal matrix. Special stains like PAS, masson trichrome, von Kossa, Grocott facilitate the diagnosis. Ultra structural studies of lipid-laden foamy macrophages, which are typically PAS-negative or only weakly PAS-positive, have demonstrated intracellular bacteria.<sup>[12,13]</sup> The foam cells of monocyte/macrophage origin are positive for CD68, HAM56, CD11b and KP1 as pointed out by Nakashiro et al.<sup>[14]</sup>

Renal tuberculosis greatly mimics diffuse xanthogranulomatous pyelonephritis. Both show thickening of peripheral fasciae and spread of inflammation to adjacent organs mainly liver. Radiological and histopathological features differentiate these two. Malakoplakia also resembles xanthogranulomatous pyelonephritis but it affects both kidneys and on microscopic examination it shows Michaelis-Gutmann bodies.<sup>[11,12]</sup> In renal replacement lipomatosis atrophic renal parenchyma does not show xanthoma cells.<sup>[10,11,12]</sup>

Renal cell carcinoma may be indistinguishable from xanthogranulomatous pyelonephritis (XGP) radio graphically and clinically. The focal variant restricted to a portion of kidney may be mistaken grossly for a Clear cell renal carcinoma. Immunohistochemically clear cells of renal cell carcinoma are CD68- and keratin +.<sup>[14]</sup>

In conclusion, Xanthogranulomatous pyelonephritis is mostly of infective origin and assumes its particular appearance because of marked parenchymal damage resulting in



accumulation of foam cells. Because of its tumour like clinical behaviour the definitive diagnosis requires histological examination. Treatment usually consists of extended open nephrectomy and long term dialysis. Overall prognosis is good and mortality is rare.

#### References:

1. Parsons MA, Harris SC, Longstaff AJ, Grainger RG. Xanthogranulomatous pyelonephritis: a pathological, clinical and aetiological analysis of 87 cases. *Diagn Histopathol* 1983;6:203–19.
2. Craig WD, Wagner BJ, Travis MD. Pyelonephritis: radiologic-pathologic review. *Radiographics*. 2008 Jan-feb;28 (1): 255-77. doi:10.1148/rg.281075171.
3. Tolkoff-Rubin NE, Cotron RS, Rubin RH. Urinary tract infection, pyelonephritis, and reflux nephropathy. In: Brenner BM, ed. *Brenner and Rector's The kidney*, 8<sup>th</sup> ed. Philadelphia, Pa: Saunders Elsevier; 2007:chap34.
4. Bingol-Kologlu M, Ciftci AO, Senocak ME, et al. Xanthogranulomatous pyelonephritis in children: Diagnostic & therapeutic aspects. *Eur J Pediatr Surg* 2002; 12:42-48.
5. Malek RS, Elder JS. Xanthogranulomatous pyelonephritis: a critical analysis of 26 cases and of the literature. *J Urol* 1978 May; 119(5): 589-93.
6. Matsuoka Y, Arai G, Ishimaru H, Takagi K, Aida J, Okada Y. Xanthogranulomatous pyelonephritis with a renocolic fistula caused by a parapelvic cyst. *Int J Urol* 2006;13:433–5.
7. Alan C, Ataus S, Tunc B. Xanthogranulomatous pyelonephritis with psoas abscess: two cases and review of the literature. *Int Urol Nephrol* 2004;36:489–93.
8. Sherman SC, Limkakeng A. Xanthogranulomatous pyelonephritis with a nephrocutaneous fistula. *J Emerg Med* 2005 Oct;29(3): 337–8.
9. Devevey JM, Randrianantenaina A, Soubeyrand MS, Justrabo E, Michel F. Xanthogranulomatous pyelonephritis with nephrocutaneous fistula. *Prog Urol* 2003;13:285–9.
10. Al-Ghazo MA, Ghalayini IF, Matalaka II, Al-Kaisi NS, Khader YS. Xanthogranulomatous pyelonephritis: analysis of 18 cases. *Asian J Surg* 2006;29:257–61.
11. Grainger RG, Longstaff AJ, Parsons MA. Xanthogranulomatous pyelonephritis: a reappraisal. *Lancet* 1982;1:1398–401.
12. Kelly DR, Murad TM. Megalocytic interstitial necrosis, xanthogranulomatous pyelonephritis, and malakoplakia: An ultrastructural comparison. *Am J Clin Pathol* 1981;75:333.
13. Khayal-Mawad J, Greco MA, Schinella RA. Ultrastructural demonstration of intracellular bacteria in xanthogranulomatous pyelonephritis. *Hum Pathol* 1982;13:41.
14. Nakashiro H, Haraoka S, Fujiwara K, Harada S, Hisatsugu T, Watanabe T. Xanthogranulomatous cholecystitis. Cell composition and a possible pathogenetic role of cell-mediated immunity. *Pathol. Res. Pract* 1995;191(11):1078–86. doi:10.1016/S0344-0338(11)80651-5.