

Case Report

An Unusual Case of Recurrent Syncope in an Elderly Male

Nitin Reddy¹, Vaibhao gabhane², Sourya A.³, Samarth Shukla⁴^{1,2}Resident department of Medicine, JNMC, DMIMS Sawangi (Meghe), Wardha-442001, Maharashtra, India³Professor department of Medicine, JNMC, DMIMS Sawangi (Meghe), Wardha-442001, Maharashtra, India⁴Professor department of Pathology, JNMC, DMIMS Sawangi (Meghe), Wardha-442001, Maharashtra, India**Address for correspondence:** Dr. Nitin reddy, Room no 108, arunodhay vihari apartment, Sawangi (Meghe), Wardha-442001, Maharashtra, India.

ABSTRACT: Syncope is common in almost all the age groups and affects around 40% of people during their lifetime. There are many etiologies among which carotid hypersensitivity is a rare and important cause. Carotid sinus activity causes cardio inhibitory type of bradycardia or hypotension. We describe a case of 70 year old male who presented to us with recurrent attacks of syncope and was diagnosed as carotid sinus syncope with sick sinus syndrome.

Key words: Syncope, carotid massage, SSRI, Pacemaker implantation

Introduction:

Syncope is one of the commonly encountered symptom in medical practice. Its etiologies are heterogenous and pathologies are complex⁽¹⁾. Carotid hypersensitivity is a known factor for recurrent syncope. It was described in 1933⁽²⁾. Carotid sinus activity causes cardio inhibitory type of bradycardia or hypotension with syncope.

Case report:

A 70 year old male patient presented to us with on and off attacks of presyncope and syncope since 7 months duration. He denied any other significant past illness. There was no history of prior Stroke/TIA(Transient of Ischemia) or other Cardiovascular illness. On asking leading questions, he revealed majority of attacks occurred while shaving or suddenly turning his head to one side while doing daily chores. General physical examination and Systemic examination did not reveal any abnormality. There was no carotid bruit/murmur but a mild carotid massage triggered syncope attack with established bradycardia which was documented by ECG (in figure 1) and also there was significant fall in systolic BP of more than 20 and diastolic BP of more than 10 mm hg after carotid massage (BP before massage was 140/100 and after carotid massage was 116/84 mm of Hg respectively).

Transcranial and carotid Doppler were insignificant. CT Brain was normal. In the hospital stay, he developed 2 or 3 episodic bradycardia with syncope. 2D Echo and Coronary angiography were normal. In electrophysiological study the corrected sinus node reentry time was 1821 milliseconds and atrial to ventricular conduction time was 538 milliseconds suggestive of sinus node dysfunction.

With a diagnosis of carotid sinus hypersensitivity with sick sinus syndrome, the patient was subjected to undergo

permanent pacemaker implantation (DDDR mode) and was started on SSRI (Selective serotonin reuptake inhibitor, tab Fluoxetine 20 mg at night) after which patient came with improved symptoms in 1 month follow up.

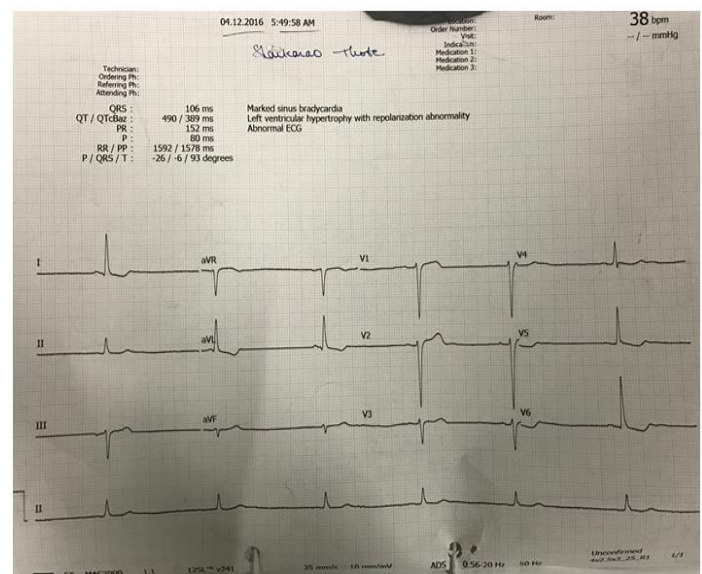


Figure 1: ECG showing marked sinus bradycardia (38 bpm) following carotid sinus massage.

Discussion:

Carotid sinus syncope is a neurally mediated syncope. The possible pathophysiology being any trigger to the neurovascular structure surrounding carotid mechanoreceptors⁽³⁾, for example carotid sinus massage, head turning, shaving, extension of neck, tight collars causes dizziness and syncope due to transient cerebral hypoperfusion. Usually elderly males are affected, the condition can be classified into:

- 1) cardio inhibitory type (most common variant)
- 2) vasodepressor type
- 3) mixed type.

The pacemaker implantation is the choice of treatment⁽⁴⁾. Beta blockers, SSRI, alpha blockers⁽⁵⁾ can also improve the symptoms. In younger individuals, fludrocortisone is the treatment of choice. In our case, the patient underwent dual chamber pacing with fluoxetine therapy.

Conclusion:

Syncope is an important clinical symptom. There are many etiologies. Carotid hypersensitivity is one of the rare conditions that can precipitate syncope attacks in special situations. Sick sinus syndrome is primarily mediated through sinus node dysfunction leading to bradyarrhythmias and syncope. Rare coexistence of both the situations in a case demands appropriate diagnostic workup and management.

References:

1. Pai CH, Hu WH, Wang KY, Ting CT. Measurements of heart rate variability in patients with unexplained syncope. *J Chin Med Assoc* 1995;56:292–7.
2. Weiss S, Baker JR. The carotid sinus reflex in health and disease. *Medicine* 1933;12:297–351.
3. Tea S, Mansourati J, L'Heveder G, Mabin D, Blanc JJ. New insights into the pathophysiology of carotid sinus syndrome. *Circulation* 1996;93:1411–6.
4. Rinfret S, Cohen DJ, Lamas GA, Fleischmann KE, Weinstein MC, Orav J, Schron E, et al. Cost-effectiveness of dual-chamber pacing compared with ventricular pacing for sinus node dysfunction. *Circulation* 2005;111:165–72.
5. Gilden JL. Midodrine in neurogenic orthostatic hypotension. A new treatment. *Int Angio* 1993;12:125–31.