

Case Report

Hemophagocytic Lymphohistiocytosis in a Young Child

*Dr. Rubiya Nadaf**, *Dr. Bela Shah***, *Dr. Dhara Gosai****

*Resident, ** Professor, ***Assistant professor, Department of paediatrics, B.J Medical College, Ahmedabad.

¹Resident, Department of Pediatrics ,Civil Hospital Ahmedabad.

Address: Room NO C507, New PG Hostel, Building No.1, Civil Hospital Asarwa ,Ahmedabad- 380016

²Professor, Department of Pediatrics, Civil Hospital Ahmedabad.

Address: 45 Arohiveela, Bopla, Sardar Patel ring road, Ahmedabad- 380058

³Assistant Professor, Department of Pediatrics ,Civil Hospital Ahmedabad.

Address: 101, Mithila-2, New mental campus, Opp. Tatanagar, Meghaninagar, Ahmedabad – 380016

ABSTRACT:

Hemophagocytic lymphohistiocytosis (HLH) is a multisystem disorder mediated by cytokine storm and is characterized by fever, pancytopenia and organomegaly with laboratory features like hyperferritinemia, hypertriglyceridemia and hypofibrinogenemia¹. Etiology can be genetic or acquired such as infections, malignancy and autoimmune disorders. Diagnosis, identification of underlying etiology and management of HLH remain tough clinical puzzles to sort out for the managing physician. The term hemophagocytosis describes the pathologic finding of activated macrophages, engulfing erythrocytes, leukocytes, platelets and their precursor cells. It is a serious and potentially life threatening histiocytic disorder in children and adults. A hallmark of HLH is impaired or absent function of natural killer (NK) cells and cytotoxic T-cells (CTL)². In its most severe form, it leads to a sepsis-like picture and multiorgan failure (MOF). We reported a case of a ten-year-old boy who had such a presentation and succumbed during the hospital stay.

Keywords: Hemophagocytes, Immunosuppression, Pancytopenia.

Introduction:

HLH is a syndrome characterized by fever, pancytopenia, splenomegaly, and hemophagocytosis in bone marrow, liver, or lymph nodes. It can be classified as familial (primary) or acquired (secondary) HLH¹. Acquired HLH is associated with several viral, bacterial, fungal and parasitic infections as also autoimmune diseases and malignancies. HLH needs to be differentiated from other conditions like Sepsis, SIRS, MODS and Macrophage activation syndrome which can mimic HLH, as the management strategies and outcome of each differ according to the etiology³.

Case Report:

History and examination: A 10-year-old boy was admitted with fever and progressive pallor of 1 month duration. Examination revealed significant pallor, ecchymotic patches on chest and abdomen with generalized anasarca. Abdominal examination showed hepatosplenomegaly with liver of 10 cm below costal margin and spleen of 6 cm below costal margin. Chest & Cardiovascular examination revealed cardiomegaly, bilateral gross pleural effusion. On investigation there was anaemia ,lymphopenia, thrombocytopenia, elevated Erythrocyte sedimentation rate (ESR), and high aspartate transaminase levels. Peripheral blood film showed microcytic hypochromic erythrocytes with hypersegmented polymorphs. Coagulation profile was deranged with prolonged PT and aPTT. Extensive infection workup was negative. Chest X-ray

showed bilateral gross pleural effusion and ultrasound abdomen showed hepatosplenomegaly with gross ascites and bilateral pleural effusion. Bone marrow biopsy showed hemophagocytes and lymphohistiocytes.

Course and management: On Day 1, considering Pancytopenia possibility of infections and malignancy was kept at admission. Patient was started on IV Ceftriaxone and amikacin with supportive management in the form of Fresh frozen plasma, packed cell transfusion and Platelet components. On Day 3, on receiving bone marrow cytology report, the diagnosis of HLH was confirmed and the patient was started on IVIg for 5 doses, Injection Dexamethasone 10mg/m²/day was also started after which slight improvement was noted for a day or two. Soon there was worsening respiratory distress. Repeat chest radiography showed patchy areas of collapse and consolidation. Antibiotics were changed to injectable Vancomycin and Ceftazidime. On Day 8 of admission patient developed blood in stool, Hematuria, worsening of respiratory distress and tachycardia. Antibiotics were changed to Inj. Meropenem and Inj.Linezolid. Inj. Fluconazole and Inj. Clindamycin were also added. He also needed multiple packed red cell and platelet transfusions. However he kept on worsening to develop an episode of pulmonary hemorrhage after which he was put on ventilator support and inotropic support. He succumbed to pulmonary

hemorrhage with refractory shock with multiorgan dysfunction on day 10 of hospital stay.

Discussion:

Diagnosis of HLH is not in doubt in the index child as he did satisfy five clinical criteria for HLH: fever, splenomegaly, cytopenia involving two cell lines, high fasting triglycerides, high serum ferritin and bone marrow showing lymphohistiocytes. Ferritin levels more than 10,000 ng/ml have been found to be 98% specific for HLH in children⁴.

It is of two types - primary HLH and secondary HLH (acquired HLH), which occurs after strong immunologic activation by systemic infection (virus, bacteria and protozoa), autoimmune disorders or underlying malignancy⁵. In a majority of cases, HLH occurs secondary to one or more acquired triggers in a setting of genetic predisposition^{6,7}. EBV is said to be the most common acquired trigger⁸. The pathological hallmark of this disease is the aggressive proliferation of activated macrophages and histiocytes, which phagocytose other cells, namely red blood corpuscles (RBCs), white blood corpuscles (WBCs) and platelets, leading to the clinical symptoms⁹.

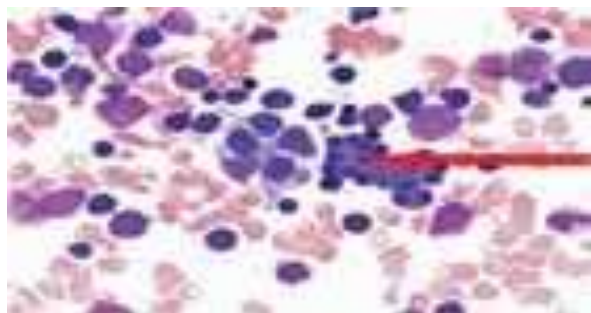


Fig-1: Bone marrow smear showing Hemophagocytosis. Arrow showing Macrophage engulfing blood cells

The diagnostic criteria⁹ is as follows:

Clinical and laboratory criteria (5/8 criteria)

- Fever
- Splenomegaly
- Cytopenia ≥ 2 cell lines
- Hypertriglyceridemia and/or hypofibrinogenemia
- Fasting triglycerides ≥ 3 mmol/l
- CD25 ≥ 2400 U/ml
- Decreased and/or absent NK-cell activity
- Hemophagocytosis in bone marrow, cerebrospinal fluid or lymph nodes

For confirmation hemophagocytosis must be demonstrated in the bone marrow, spleen or lymph nodes. The newest treatment protocol, HLH-2004, is based on the Histiocyte Society's original HLH-94 protocol, with some minor modifications¹¹. Goal being to first achieve clinical stability and then to cure with bone marrow transplantation (BMT). Antimycotic prophylaxis is used during the initial doses of dexamethasone. One group found that IVIG was effective in suppressing symptoms when administered within hours of disease onset. Etoposide, cyclosporine,

corticosteroids are the other drugs with some shown benefits. Recent case reports show promising results with an anti-TNF- α approach and plasmapheresis¹².

Acknowledgements:

Words defy me in expressing my sincere gratitude and respect for my affectionate teachers, colleagues and unit other members and also all staff members of the Department of paediatrics, Ahmedabad.

References:

1. Janka G. Hemophagocytic lymphohistiocytosis: A serious challenge for every physician. *Revista Clínica Española*. 2014;214(6):318-319.
2. Allen C, Yu X, Kozinetz C, McClain K. Highly elevated ferritin levels and the diagnosis of hemophagocytic lymphohistiocytosis. *Pediatric Blood & Cancer*. 2008;50(6):1227-1235.
3. Bode S, Lehmborg K, Maul-Pavicic A, Vraetz T, Janka G, Stadt U et al. Recent advances in the diagnosis and treatment of hemophagocytic lymphohistiocytosis. *Arthritis Research & Therapy*. 2012;14(3):213.
4. Janka G. Hemophagocytic Lymphohistiocytosis: When the Immune System Runs Amok. *Klinische Pädiatrie*. 2009;221(05):278-285.
5. Fajtelson Y, Grunebaum E. Hemophagocytic lymphohistiocytosis and primary immune deficiency disorders. *Clin Immunol*. 2014;155:118-25.
6. Liu R, Shi X, Li J, Hu T, Cao J, Sun Y, et al. [Epstein-Barr virus-associated hemophagocytic lymphohistiocytosis in Chinese children: a primary study on clinical characteristics and gene mutations]. *Zhonghua Yi Xue Za Zhi*. 2014;94:1941-6.
7. Henter JI, Arico M, Egeler RM, Elinder G, Favara BE, Filipovich AH, et al. HLH-94: a treatment protocol for hemophagocytic lymphohistiocytosis. HLH study Group of the Histiocyte Society. *Med Pediatr Oncol*. 1997;28:342-7.
8. Henter JI, Horne A, Arico M, Egeler RM, Filipovich AH, Imashuku S, et al. HLH-2004: Diagnostic and therapeutic guidelines for hemophagocytic lymphohistiocytosis. *Pediatr Blood Cancer*. 2007;48:124-31.
9. Rosado FG, Kim AS. Hemophagocytic lymphohistiocytosis: an update on diagnosis and pathogenesis. *Am J Clin Pathol*. 2013;139:713-27.
10. Janka G, zur Stadt U. Familial and acquired hemophagocytic lymphohistiocytosis. *Hematology Am Soc Hematol Educ Program*. 2005:82-8.