
Research Article

Morphometrical and histological evaluation of the effect of vitamins B1, B6 and B12 on rats sciatic nerve after crush injury

*Dr. Maan H. Al-Khalisy**, *DR. Saleh M. Ali***

University of Baghdad , college of medicine ,Department of anatomy.

ABSTRACT:

Objectives: To evaluate the effect of vitamins (B1, B6, and B12) on nerve regeneration and recovery after crush injury to sciatic nerve in experimental rats

Study Design: Prospective observational study

Setting: Department of anatomy, College of medicine, Baghdad University

Subjects and intervention: Total 60 Rats ,with ageing(8-12) weeks old of both sex, during 45 days period were included in this study

Study period: 15 October 2016 to 30 November 2016

Results: on comparison among different groups (control and experimental groups) . Best improvement in group of rats on B12(group D) than other groups on B1(group B) or B6(group C). B12 group treated with (1mg / kg / day) significantly increased in the MTC when compared to the control , B6 and B1 groups on days 15, 30 and 45 of the study at $P \leq 0.05$. Histological analysis by Van Giesons stain, A- all groups control and experimental (B1, B6, B12, A) show degeneration in different areas but less in group B12. B- sciatic nerve fascicles with Schwann cell and fibroblast better organized in group B12

Conclusion: vitamin B12, among different kind of vitamins B, considered as a best vital medication for regeneration and remyelination of damage nerve fibers.

Key words: Crush injury, Vitamin B12, Regeneration.

INTRODUCTION:

Peripheral nervous system with its spinal nerves and cranial nerves which conduct information from and to central nervous system. The nerves consist of bundles of nerve fibers (axons) (Richard , 2010). The CNS originates from the ectoderm and appears as the neural plate at the third week of development. Schwann cells originate from neural crest , migrate peripherally and wrap themselves around axon forming the neurilemma sheath (T.W.Sadler 2012). Myelin around the axons form myelin sheath or may not , depending on their diameter , unmyelinated nerve fibers usually small diameter. Axons may thick, sheathed by increasing numerous concentric wrapping of the enveloping cell , forming myelinated nerve fibers (Junqueira&Carneiro,2010). Axonotmesis is more severe stage of injury , with disruption of not only the myelin sheath , but axon as well . The epineurium and perineurium remain intact , meaning that there is still some continuity within the nerve (Browner , et al 2009) . Peripheral neuropathy is damage or disease affecting nerves which may impair sensation , movement , gland or organ function , depending on the type of nerve affected, common causes include systemic diseases (such as diabetes or leprosy), medication (chemotherapy) traumatic injury , infection excessive alcohol consumption , immune system

disease or it may be inherited (Richard, 2010) . Acute or chronic peripheral nerve disorder may be focal (affecting a single nerve : mononeuropathy) , multifocal (several nerves : mononeuropathy multiplex) or generalized (polyneuropathy) . Neurophysiological tests and some time nerve biopsy will help determine whether the pathology is primarily affecting the nerve axon (axonal neuropathy) or myelin sheath (demyelinating neuropathy) , Many systemic diseases , drugs and toxins can be associated with peripheral neuropathy and investigations required in a patient with peripheral neuropathy reflect this wide spectrum of causes (Nicholas , *et al* 2008) .

Vitamins (B1, B6 and B12) frequently used for treating peripheral neuropathy but which vitamin (B₁ , B₆ , B₁₂) is the most important factor in the treatment of neuropathy and which vitamin more efficacious than others is not clear , B vitamins have been found to be a clinically useful pharmacological tool for patients with neuropathic pain for along time ago , B vitamins have been used as analgesic drugs to treat pain disorders associated with their deficiency (Mader, *et al* 1988)(Marcus and Coulston,1996). However B vitamins have been reported to be useful in some painful disorders such as polyneuropathy, neuralgia, radiculopathy and neuritis associated with pain and

paresthesias (ECKert and Schejbal 1992) and diabetic peripheral neuropathy (Kuwabara *et al* 1999).

There are sporadic report that assorted combinations of B vitamins can alleviate pain in diabetic patients, We therefore investigated the efficacy of a cocktail of the vitamins B1,B6 and B12 in alleviating behavioral indices of sensory dysfunction such as allodynia and hyperalgesia in diabetic rats and also the relative contribution of individual components of the cocktail(Corinne *et al* 2009). Local application of vitamin B12 to treat the peripheral nerve has shown efficacy in animals with peripheral neuropathy(Sun *et al* 2012).

METHODOLOGY:

This study had been conducted in the department of anatomy college of medicine /university of Baghdad .

Animals used in this study:-

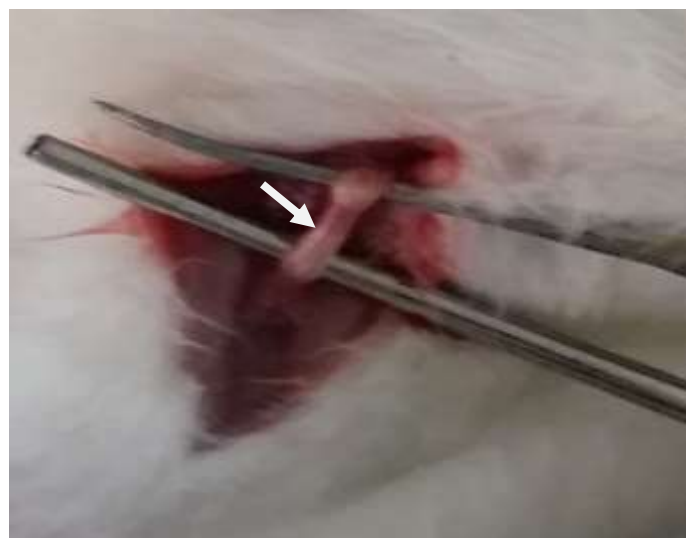In the current study 60 Swiss albino rats of both sexes , weighing (140 – 200) g , with averagely (8-12) weeks old, were selected .

The animals were kept in cages in room condition and fed with standard rats diet and access tap water .Through out the study ,the animal received accepted standard care.

Experimental Protocol The rats were divided randomly into four groups and each group consisted of 15 animals .Group A(which considered as control group), received normal saline (for 45 days) . Experimental animals included 3 groups, group B received B1 for 45 days , While group C received vitamin B6 for 45 days. The experimental animals in group D received vitamin B12 for 45 days . The vitamins was injected intramuscularly.

Surgical technique All surgical procedures were carried out while the animals were anesthetized using ketamine hydrochloride (75 mg / kg) and xylazine hydrochloride (5 mg / kg), anesthetic solution intramuscularly . The posterior area of the right thigh was operated after shaving and sterilization of the skin with 10 % povidone iodine . The sciatic nerve of all the rats was exposed at mid thigh level and crushed for 20 second with haemostatic forceps (5 – 8mm size).Complete crush of sciatic nerve is confirmed by presence of translucent band Figure(1) .The site of crush injury was marked by labelling the adjacent area of muscle with silk stitch. The skin sutured by 3/0 silk thread and allowed to breathe room air until recovery .

Figure(1):- Sciatic nerve after crushing procedure (white arrow) indicats crushed area.



Grouping of animals,the treatment received , day and type of surgical procedure that had been done for each subgroups could be summarized in table (1) .

Grouping of animals	Control group	Experimental groups		
	A	B	C	D
Number of animals	15	15	15	15
Treatment received by animals	1ml of normal saline intramucularly	i.m. injection of 180 mg / kg body weight of vitamin B1	i.m. injection of 180 mg / kg bodyweight of vitamin B6	i.m. injection of 1 mg / kg bodyweight of vitamin B12
Duration of treatment	45 days	45 days	45 days	45 days
Date , type of surgical procedure and number of animals exposed to surgery for each group of (A , B , C and D) .				
Date	No.of animals	Type of surgical procedure .		
Day 0	15	Crushing of sciatic nerve .		
Days 15 th	5	Biopsy from sciatic nerve from post crushed site and from calf muscle.		
Days 30 th	5	Same surgical procedures had been done as in day 15 th		
Days 45 th	5	Same surgical procedures that had been done as in day 15 th .		

Examination

Gross morphology and morphometry examination

The skin of the right and left lower limbs were removed from the gluteal regions to the feet .Then observation of the difference between right and left limbs for the colour and bulk of the muscles had been done. The bulk of muscles had been tested by measuring the mid thigh(MTC) and leg(MLC) circumference .

Samples collection for microscopic examination :

In both group (control and experimental groups) .A piece of (5 mm – 10 mm) had been obtained from right side sciatic nerve including the crush area and area distal to the injured part then fixed in 4% formaldehyde (10% neutral buffered formalin) for about 24-48hrs at room temperature (20-25 C °). (Zanini C., *et al*, 2012).

Special stain (van Gieson staining protocol) (Bancroft,1984).

Novaultra special stain Kits

A- Reagent formulae (prepared by Royellis) IMVS Division of pathology (Australia) **Novaultra special stain Kits.**

1- Celestin Blue

5 % Ammonium ferric sulphate (ironalum) 100 ml

Celestin Blue(151050) 0.5 g

Add the Celestin blue to the ammonium ferric sulphate and boil for 3 minutes . Filtered when become at room temperature then stored in refrigerator .

2- Curtis stain

Saturated aqueous picric acid 90.0 ml

1 % ponceaus 10.0 ml

Glacial acetic acid 10.0 ml

3- 1% Ponceaus

Ponceaus (C127195) 1.0 gm

distilled water 100 ml

B- Procedure :

- 1- Hydrated sections by using distilled water .
- 2- Then Stained nuclei with Celestin blue for 5 minutes .
- 3- Washed in distilled water .
- 4- Staining with haematoxylin for 5 minutes .
- 5- Washed well in running tap water for 5 minutes .
- 6- Placed in curtis stain for 5 minutes .
- 7- Dehydrate rapidly through 95 % alcohol , 2 changes of 100% alcohol, 1minut for each .
- 8- Clear in 2 changes of xylene for 3 minutes each.

9- Mounting using DPX.

Photography:

Photograph was taken to the sciatic nerve after crushing injury and translucent area on sciatic nerve indicated crushing site. Using a digital camera(canon).The slides were examined by using light microscope(LEICA) and after examination of all region of the slides by different magnifications(100x, 400x,1000x with oil immersion technique) tissue sections were photographed by(LEICA DM(2900)(C-Mount 0.55X).

Statistical analysis: Statistical analysis was using SPSS (statistical package for the social science version-20).One-way analysis of variance (ANOVA) was performed on the morphometric parameters(MTC)and(MLC) data for examination of differences among four groups B1(group B),B6(group C),B12(group D) and control group(group A) . P.value <0.05 was considered statistically significance but When P.value < 0.01 was considered highly statistically significance .

RESULTS

GROSS OBSERVATIONS

The animals from both experimental and control groups showed weakness in right hind limbs , altered gait, dragged the dorsum of their feet and reducing in response to pinch test . all animals remained healthy through out the study period . With the passage of time , they showed gradual improvement in their gait as compared to one observed on the first day after crush injury to the sciatic nerve . Which is more clear in group of rats received vitamin B12 (1mg / kg / day) and less in other groups of control and groups of rats received vitamins B1 and B6 (180mg / kg / day) .When rats were scarified on days(15,30 and45). After removal of the skin of both lower limbs from gluteal regions to the feet . Difference in color and bulk of muscle were observed between both limbs (right crush injury hind limb and left normal hind limb) . In right crush limb, the muscles pale atrophic while other limb with no crush injury the muscle pink good bulk . However , by comparison among different groups . Best improvement in group of rats on B12(group D) than other groups on B1(groupB) or B6(group C) .

Quantitative analysis :

Measurement :

Mid thigh and leg level circumference of right lower limb and left normal hind limb were measured and results were plotted in Tables (2,3,4,5,6,7) Figures(2,3,4,5,6,7,.) .For evaluation of sciatic nerve regeneration and function . B12 group treated with (1mg / kg / day) significantly increased in the MTC when compared to the control,B1 and B6 groups on days 15, 30 and 45 of the study .Although there is an increased in mean MLC in group B12 treated with (1mg / kg / day) than the means of control,B1 and B6 but there is no statistical difference at $p \leq 0.05$.

Table (2) Right and left mid thigh circumference (MTC) of four groups described in mean \pm SD at 15th day post crush injury.

B1		B6		B12		Normal (crush no treatment) (N)	
Right MTC	left MTC	Right MTC	Left MTC	Right MTC	Left MTC	Right MTC	Left MTC
4.60 \pm 0.50	5.34 \pm 0.27	4.00 \pm 0.00	5.20 \pm 0.24	4.80 \pm 0.42	5.30 \pm 0.24	4.00 \pm 0.00	5.20 \pm 0.71

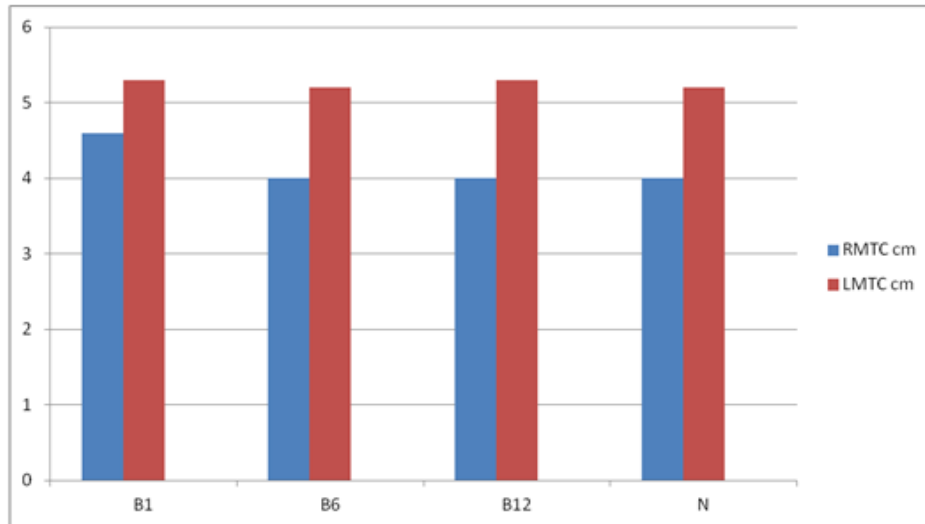


Fig. 2: Comparison for right and left mid thigh circumference (MTC) of B1, B6 ,B12 and normal groups on day 15.

Table (3) Right and left mid thigh circumference (MTC) of four groups described in mean \pm SD at 30th day post crush injury.

B1		B6		B12		Normal(crush no treatment) (N)	
Right MTC	Left MTC	Right MTC	Left MTC	Right MTC	Left MTC	Right MTC	Left MTC
4.80 \pm 0.28	5.30 \pm 0.24	4.30 \pm 0.50	5.20 \pm 0.56	5.00 \pm 0.60	5.32 \pm 0.26	4.30 \pm 0.23	5.31 \pm 0.25

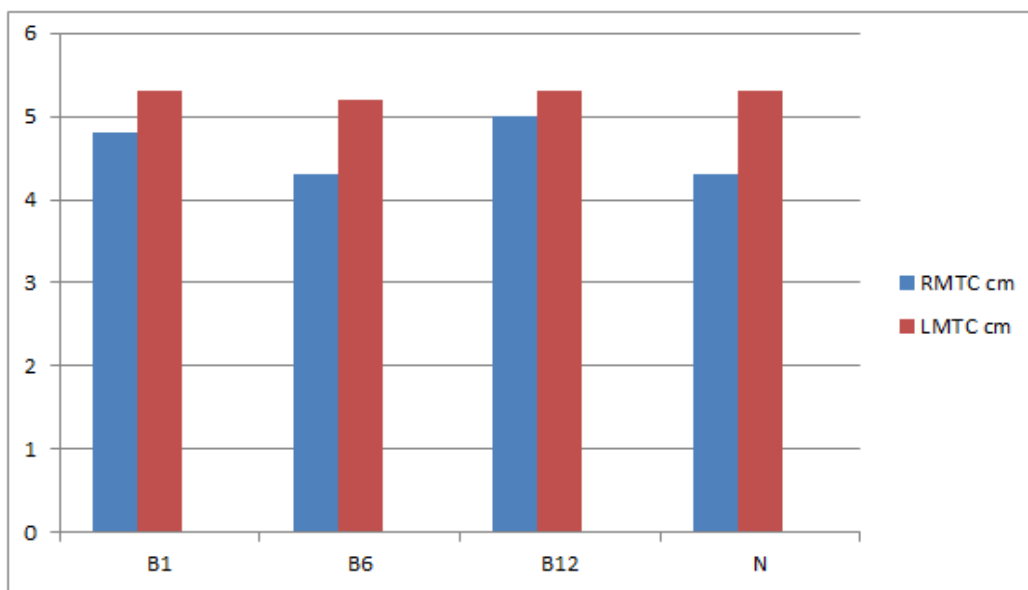


Fig. 3: Comparison for right and left mid thigh circumference (MTC) of B1,B6 ,B12 and normal groups on day 30.

Table (4) Right and left mid thigh circumference (MTC) of four groups described in mean + SD at 45th day post crush injury.

B1		B6		B12		Normal(crush no treatment) (N)	
Right MTC	left MTC	Right MTC	Left MTC	Right MTC	Left MTC	Right MTC	Left MTC
5.10± 0.20	5.40 ± 0.46	4.50 ± 0.53	5.20 ±0.31	5.20 ±0.31	5.30 ±0.40	4.40 ± 0.50	5.20 ±0.34

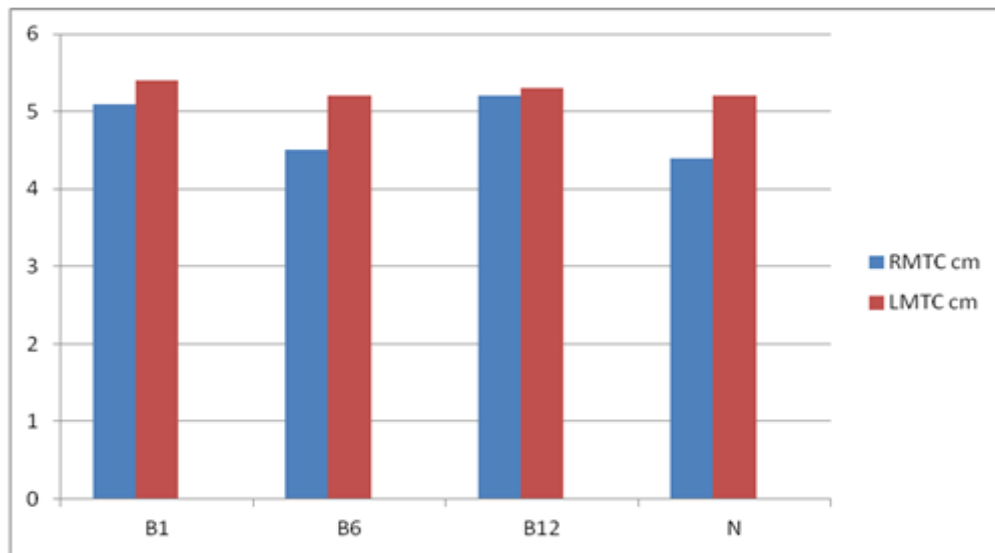


Fig. 4 Comparison for right and left mid thigh circumference (MTC) of B1,B6 ,B12 and normal groups on day 45.

Table (5) Right and left mid leg circumference (MLC) of four groups described in mean + SD at 15th day post crush injury.

B1		B6		B12		Normal (crush no treatment) (N)	
Right MLC	Left MLC	Right MLC	Left MLC	Right MLC	Left MLC	Right MLC	Left MLC
3.20 ± 0.23	3.93±0.64	3.00 ±0.51	3.88 ± 0.68	3.40 ± 0.49	3.90 ± 0.65	3.00 ±0.00	3.97 ± 0.60

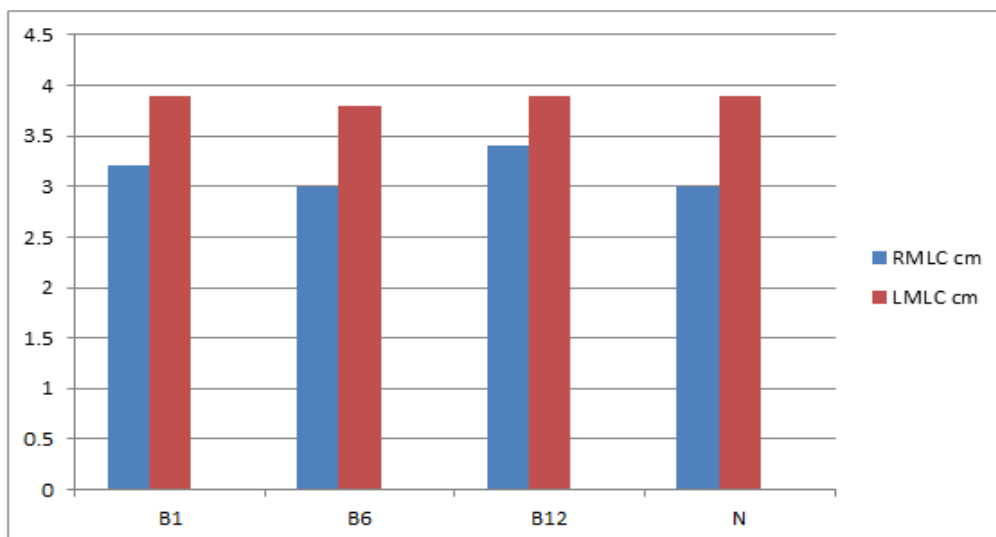


Fig. (5) Comparison for right and left mid leg circumference (MLC) of B1,B6 ,B12 and normal groups on day 15.

Table (6) Right and left mid leg circumference (MLC) of four groups described in mean + SD at 30th day post crush injury.

B1		B6		B12		Normal(crush no treatment) (N)	
Right MLC	left MLC	Right MLC	Left MLC	Right MLC	Left MLC	Right MLC	Left MLC
3.40 ± 0.84	3.90 ± 0.64	3.26±0.23	3.80 ±0.75	3.60 ±0.40	4.00 ±0.69	3.20 ± 0.44	3.80 ± 0.51

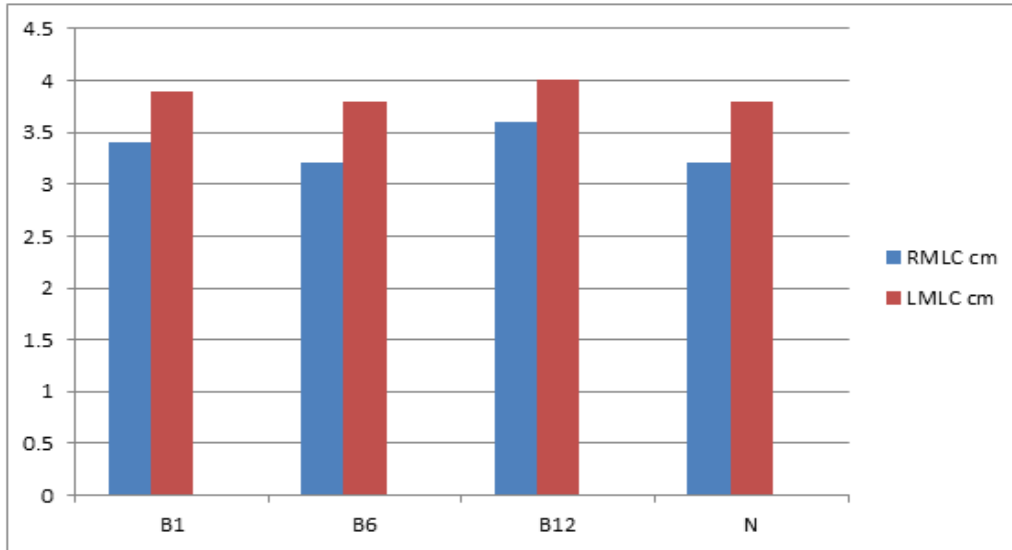


Fig.6 :Comparison for right and left mid leg circumference (MLC) of B1,B6 ,B12 and normal groups on day 30.

Table (7) Right and left mid leg circumference (MLC) of four groups described in mean + SD at 45th day post crush injury .

B1		B6		B12		Normal (crush no treatment) (N)	
Right MLC	Left MLC	Right MLC	Left MLC	Right MLC	Left MLC	Right MLC	Left MLC
3.60 ± 0.41	4.08±0.69	3.50 ±0.47	3.80 ±0.91	4.00 ± 0.70	4.20 ± 0.62	3.50 ±0.35	3.80 ± 0.80

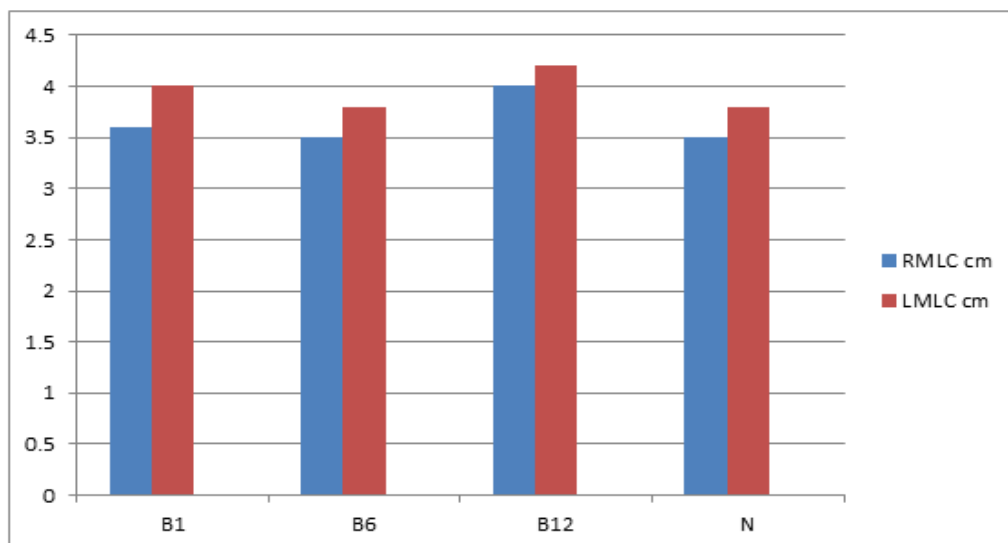
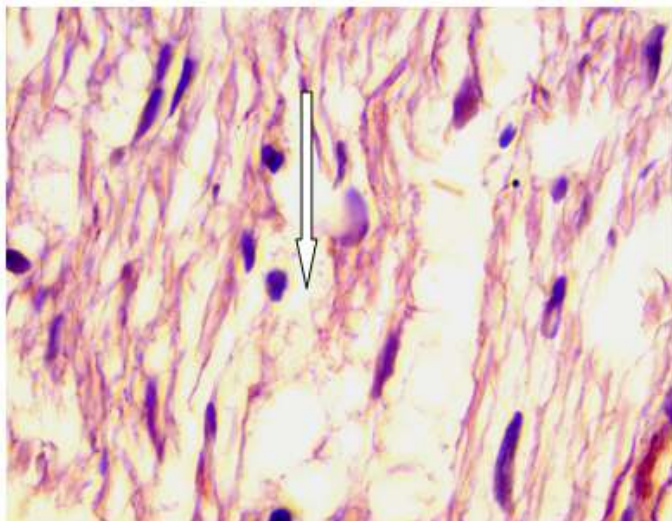


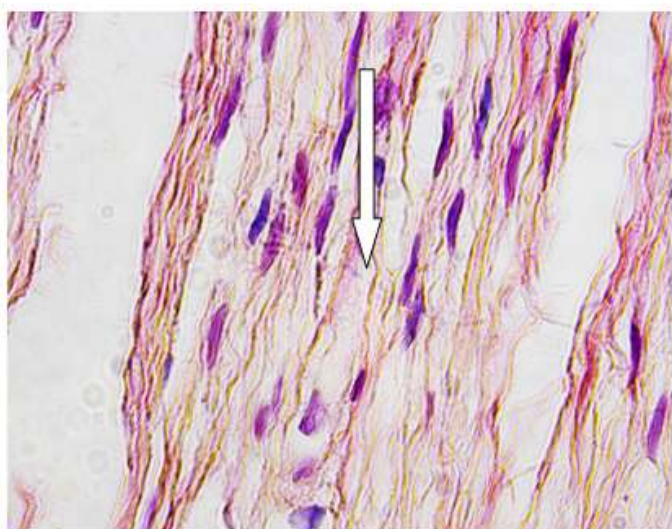
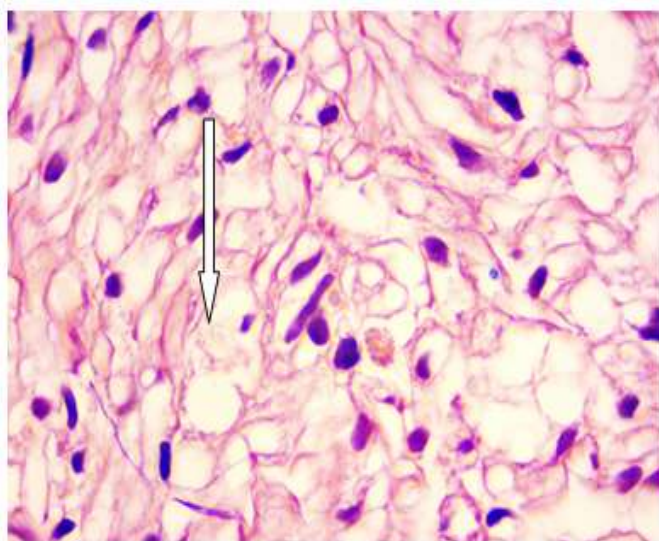
Fig. 7 :Comparison for right and left mid leg circumference (MLC) of B1,B6 ,B12 and normal groups on day 45.

Qualitative (Morphological) analysis :Special stain (van Giesons stain) .

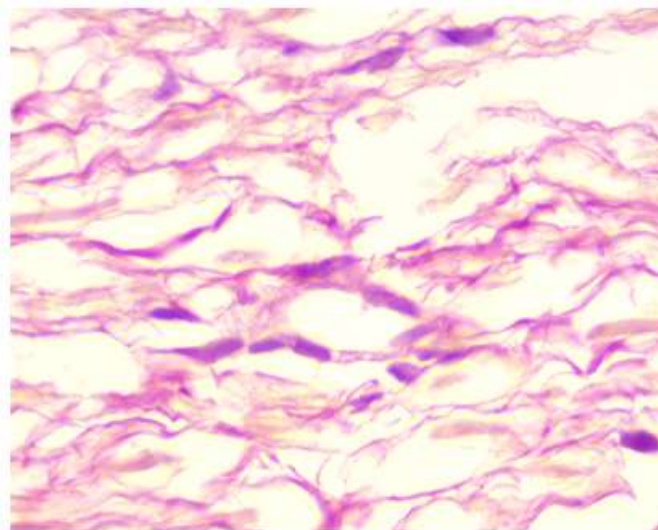
Rat sciatic nerves sections on day 45 after crush injury showing degeneration of nerve fibers in different areas of sections of experimental and control groups (N1(group A), B1(group B),B6(group C) and B12(group D).Sciatic nerve fascicles better organized in group B12(group D) .The degeneration in different areas but more in groups B6(group C) and B1(group B) .Figure (8).



A



B6



B12

Figure(8):Histological analysis by Van Giesons staining of rat sciatic nerves on day 45 after crush injury.A- In all groups experimental and control (B1,B6,B12,A) show degeneration(white arrows) in different areas but less in group B12 with Fibroblast and Schwann cells .B- sciatic nerve fascicles(black arrow) better organized in group B12.Magnification,X1000 .

Discussion

Peripheral neuropathy is one of the common pathological problem of various causes such as diabetes mellitus, alcohol consumption, tumor , many systemic diseases and vitamins deficiency (Dagum 1998).

The peripheral deficit caused by peripheral neuropathy could be either motor , sensory or both. This depends upon type of nerve fibers transmitted by the affected peripheral nerve (Sinnatamby 2011). Therefore , peripheral neuropathy could be illustrated as sensory deficit with or without motor involvement which could illustrated as muscles wasting (Lee Goldman Andrew 2015).

In the current study , the sciatic nerve had been exposed to crush injury. Since, Sciatic nerve carries both sensory and motor fibers (Sinnatamby 2011).Therefore motor deficit could illustrated by wasting of the muscles of thigh and leg (Vinay *et al* 2013). This is clear through reduction of the circumference of both leg and thigh as in tables (2,3,4,5,6,7)and figures (2,3,4,5,6,7).

Variable degrees of changes on histological examination.

Following crush injury of sciatic nerve , Andreea Raducan *et al* 2013, Hobbenaghi *et al* 2013, Kurtoglu 2004 and Roytta and Salonen 1988 , recorded the following histological changes which could observed four days following trauma. These changes included degeneration of axon which started as swelling of nerve axon , then disintegration of cytoskeleton architecture of axons . This processes followed by myelin sheath destruction. Following these processes, macrophages began to play their vital role in elimination of the residues of the disintegrated nerve fibers and their myelin sheath away

from the injured area . This process kept the injured area clean , healthy and suitable for nerve regeneration .

At the end of these processes, many events would occurred including redistribution of circulatory macrophage, disorganization of blood-nerve barrier , increase of cytokine production, Schwann cells proliferation and extra-cellular component production. This would lead to peripheral nerve regeneration which occurred four weeks following nerve injury.

To accelerate the process of regeneration and recovery of damage nerve, many medication have been used . These medication could be helpful in nerve regeneration or relief the pain caused by nerve damage. These medications include systemic steroid or topical one (Khanetal 2014 , Sulu *et al* 2013 , Sozcukler *et al* 2013 and Galloway *et al* 2005) and gabapentin or carbamazepine could be also used (Mixcoatizecuati *et al* 2008 , Cheshire 2002). Other drugs that used to facilitate the nerve recovery is vitamins , such as vitamin C (Aijaz Khan 2015), Vitamin D (Khalid *et al* 2012) and vitamins B (Stratos *et al* 2013 , Sun *et al* 2012 , Kopruszinski *et al* 2012 , Muthal *et al* 2008). According to results obtained by Yuksel *et al* 2014, Ang *et al* 2008, Milly Ryan-Harshman 2007, Geuna *et al* 2007 , Lundborg 2005 ,Reyes-Gracia 2004, Goadyear-Smith and Arroll 2004 and Stracke *et al* 1996 , vitamins B was considered as the best medication could be used in regeneration of damaged nerve.

In the current research the aim of the study is to compare between beneficial effect of various vitamins B on regeneration of sciatic nerve.

Therefore these two parameters (examin motor and sensory functions ,both Grossly and microscopically) represented a satisfactory factors to compare between vitamins B repair capability.

In all the groups, involved in this study ,both measures of bulk of muscles and sensory response improvement of motor and sensory nerve fibers component of sciatic nerve.

However ,vitamin B12 treated group demonstrated significant recovery of injured sciatic nerve which was reflected as better increasement in the bulk of muscle supplied by sciatic nerve, better sensory regeneration. While vitamin B1 treated group illustrated improvement in regenerative process of muscles and sensory innervations (according to previous two parameters). Yet, this improvement is less than that of vitamins B12.

Vitamin B6 treated animals showed less improvement in motor and sensory innervation comparing with that of vitamin B12 and vitamin B1 treated groups results. Their results was approximately equal to the control group (which receive normal saline only).

These different in the macroscopical results, when different kinds of vitamins B had been used highlight the various regenerative effects of different types of vitamins B.

Those various response of nerve damage to the recovery and

regenerative role of vitamins B could also be illustrated in microscopical results.

The different constructive effects of vitamins B in treatment of neuropathy could be attributed to the mode of action of vitamins B in regeneration of injured nerve and relief of neuropathic pain (Kopruszinski *et al* 2012, Jolivalt *et al* 2009,Mixcoati-Zecuatic *et al* 2008 and Strache *et al* 1996).

Till now up to our Knowledge, all the researches that had been established previously concentrated about the role of each individual vitamins B on nerve regeneration. However no one of them compared between the regenerative effect of each type of vitamin B on neuropathical changes of nerves(whatever the cause is). In the current study, the animals used had been exposed to crush injury of sciatic nerve. Each group of those animals had been treated by one type of vitamins B, Then each one had been studied macroscopically, histological by Van Gisons stain.

Vitamin B1 regenerative effect has been reflected to its role in supplying the tissue with energy which is essential for neuronal conduction (Denis Ferrier 2014, Lee and Andrew 2012) and to lesser extent , it shares in production of neurotransmitter and myelin sheath.

Vitamin B6 shows its recovery effect on injured nerve through its action as a co-enzyme in various metabolic process ,besides its role in de carboxylation and transmission process. These processes share in the synthesis of neurotransmitters(Kennelly *et al* 2015).

However the mechanism of action of vitamin B12 in nervous tissue repair still obscured and not very understood. Yet, some scientist reached to a hypothesis regarding the action of vitamin B12. This theory includes :-

1-Vitamin B12 plays an essential role in the process of neuronal regeneration through myelination of the nervous system (Kennelly *et al* 2015). This mechanism of action leads to strong communication between different parts of nervous tissues . The transmethylation converts homocysteine to methienine which revealed a power affinity in transmission of nervous tissue (Scalabine and Peracchi 2006). Methylcobalamin enhances myelination of peripheral nerve through promotion of lecithin production which is an inactive ingredient of myelin sheath lipid component, which turn accelerates regeneration of peripheral nerve (Okada *et al* 2010 ,Reyes-Grecia 2004).

2- Vitamin B12 is an important factor in production of neurotransmitters. It acts together with a compound called SAME (S -Adenosyl methionine) in manufacturing these neurotransmitters (Kennelly *et al* 2015,Denise and Ferrier 2014).

The result obtained from this study demonstrated degeneration of axons and their myelin sheath following crush injury of sciatic nerve. These findings agree with the previous studies (Xinhog Feng and Wei Yuan,2015, T. H. Kim *et al* 2011,

According to the results obtained from this research, regenerative mechanism was obvious regarding injured sciatic nerve, following treatment with various types of vitamins (Vitamin B1,B6,B12). Yet the degree of regeneration of axons and their myelin sheaths was vary among the groups of rats ,involved in this study according to which type of vitamins B had been received.

Regeneration of axons and their myelin sheath appeared clearly and faster in group D, in which their rats received Vitamin B12. Regarding the degree of regeneration, rats of group B ,which treated with B1, illustrated regeneration of nerve fibers with their myelin sheath. However the degree of regeneration was slower and less effective than these processed with vitamin B12.

Regenerative and recovery processes had been demonstrated the least effect and the more lower degree of effectiveness on the injured sciatic nerves of rats treated with vitamin B6 (i.e. group C animals).

As mentioned previously, no previous comparative studies had been done. However, Milly Ryan 2007,devied any response of crushed neuropathy of the treatment vitamin B6 .

While Good year and Arroll 2004 elicited some improvement of neuropathy due to carpal tunnel syndrome, when treated with vitamin B6. They attributed this improvement to the analgesic effect of vitamin B6 .

Dror and Allen 2008, had been demonstrated an axonal regeneration and Re-growth of the nervous system by administration of B12 through promotion of nerve process myelination and maintenance of nerve cytoskeleton . Other researchers recorded that 500 µg/kg body weight of vitamin B12 was sufficient for nerve fibers regeneration and re-establishment of action potential of the muscles supplied by the injured nerve (Liao *et al* 2013 ,Okada *et al* 2010). Sun *et al* 2012 had been assumed that vitamin B12 had neuro-regenerative activity through acting as a scavenger of reactive oxygen radicals and so functioning as anti-apoptotic and anti-necrotic role on the neurons.

Omer Besalti *et al* (2007) recorded clinical improvement in experimentally injured sciatic nerve on treated with vitamin B12. However they denied any beneficial role of this vitamin regarding electrophysiological studies.

Many scientists used a combination of vitamins B (vitamins B1, B6, B12,) for treating the neuropathy for any reasons (Kopruszinski *et al* 2012 , Ang *et al* 2008, Reyes-Gracia *et al* 2004.

All those scientists, with others had been recorded the neuroprotective and neuro-regenerative effects of vitamin B complex, yet, no one research which of vitamins B is superior to other .

Regarding administration of different types of vitamins B in the rats complaining of neuropathy due to experimental crush injury, the results obtained showed wide variety of response of damaged sciatic nerve to the vitamins B.

Vitamin B12 treated group (group D) illustrated significant regenerative process through earlier myelination of nerve fibers with abundant distribution of Schwann cells.

While vitamin B1 treated rats had shown regeneration, myelination of damaged nerve fibers and proliferation of Schwann cells , Yet this process is less significant than that revealed in vitamin B12. Beside the process of myelination of nerve fibers recognized late (in about 45 days of experiment).

Vitamin B6 treated rats of group B reflected the least reaction and myelination of damaged nerve fibers. This was so obvious when compared with the degree of repair process of nerve fibers when treated with vitamin B12 and vitamin B1.

The degree of regeneration and myelination in rats treated with vitamin B6, was more or less similar or little pet more than group A rats which underwent crush injury and received no treatment . These finding agree with the reported researches of (Shunsuke Nishimoto *et al* 2015, Hongzhi Sun *et al* 2012 , Dror and Allen 2008.

These Scientists found that vitamin B12 play vital role in the recovery of neuropathy through induction of Schwann cell proliferation and remyelination of injured nerves .Besides improving conduction of impulse through repaired nerve fibers.

Conclusion:-

1-Vitamins B is one of important medications for regeneration and remyelination of injured nerve fibers. 2-vitamin B12, among different kind of vitamins B, considered as a best vital medication for regeneration and remyelination of damage nerve fibers.

3-The variety in actions of the different types of vitamins B in their effect on injured nerves may be related to their mode of action regarding repair of injured nerve fibers. However all these types of vitamins B have an important effects on regeneration and remyelination of nerve fibers, Besides improving conduction of impulse through repaired nerve fibers.

4-Although these are differences in the degree of regeneration and myelination of injured nerve after treatment with different kinds of vitamins B, it is better to give all types of vitamins B together (vitamin B complex) to get optimal results.

References

1-Richard S. Snell , 2010 . central and peripheral nervous systems . In : [clinical neuroanatomy] 7th ed ., wolters kluwer Lippincott Williams & Wilkins , pp : 2 – 5 .

2-T.W. Sadler , 2012 . development of central nervous system . In : [Langman's medical embryology] . 12th ed ., wolters kluwer Lippincott , Williams & Wilkins , pp : 287 – 294.

3-Junqueira luiz c. & carneiro Joes , 2010 . Nerve tissue & the nervous system . In: [Basic Histology : text & atlas] . 12th ed ., The Mc Graw – Hill companies , New York , pp : 230 –

- 277 .
- 4-Browner BD , Jupiter JB , Levine AM , et al . skeletal trauma : Basic science , Management , and Reconstruction . 4th ed Philadelphia , PA : Saunders; 2009 .
- 5-Nicholas A . Boon , Nicki R. colledge , Brian R . walker , John A.A. Hunter , 2008 . The peripheral nervous system . In : [Davidson's principles & practice of medicine] . 20th ed ., Churchill Livingstone Elsevier , New York , pp : 123 , 1152 – 1155 ,1246 .
- 6-Mader R , Deutsch H , Siebert GK , Gerbershagen HU : Gruhn E , Behl M , Kubler W : Vitamin staus of inpatients with chronic cephalgia and dysfunction pain syndrome and effects of a vitamin supplementation. *Int J Vitam Nutr Res* 1988 ; 58 : 436 – 441 .
- 7-Marcus R , Coulston AM : Water – soluble vitamins : the vitamin B complex and ascorbic acid ; in Hardman JG , Limbird LE , Molinoff PB , Ruddon RW , Gilman AG (eds) : Goodman & Gilman's the Pharmacological Basis of Therapeutics . New York , McGraw – Hill , 1996 , pp 1555 – 1572 .
- 8-Eckert M , Schejbal P : Therapy of neuropathies with a vitamin B combination : symptomatic treatment of painful diseases of the peripgeral nervous system with a combination preparation of thiamine , pyridoxine and cyanocobalamin . *Fortschr Med* 1992 ; 110 : 544 – 548 .
- 9-Corinne G . Jolival , Leah M . Mizisin , Austin Nelson , Joice M . Cunha , Khora M . Ramos , (2009) . Bvitamins alleviate indices of neuropathic pain in diabetic rats .
- 10-Sun , H ., Yang , T ., Li , Q . etal . Dexamethasone and vitamin B₁₂ synergistically promote peripheral nerve regeneration in rat by upregulating the expression of brain derived neurotrophic factor . *Arch Medsci* . 2012 ; 8 : 924 – 930 .
- 11-Kuwabara S . Nakazawa R , Azuma N , Suzuki M , Miyojima K . Fukutake Y , Hattori T : Intravenous methylcobalamin treatment for uremic and diabetic neuropathy in chronic hemodialysis patients . *Intern Med* 1999 ; 38 : 472 – 475 .
- 12-Caroline M. Kopruszinski, Renata C. Reis, Juliana G. Chichorro.B vitamins relieve neuropathic pain behaviors induced by infraorbital nerve constriction in rats. *Life Sciences* 91(2012)1187-1195 .
- 13-Rahim H0bbenaghi,Javad Javanbakht, Ehan Hosseini,Shahin Mohammadi,Mojtaba Rajabian,Pedram Moayeri and Mehdi Aghamohammad Hassan.Neuropathological neuroprotective feactures of vitamin B12 on the dorsal spinal ganglion of rats after the experimental crush of sciatic nerve.*Diagnostic pathology* 2013 8:123.
- 14-Zanini C., Gerbaudo E., Ercole E., Vendramin A. and Forni M., Evaluation of two commercial and three home-made fixatives for the substitution of formalin: a formaldehyde-free laboratory is possible, *Environmental Health*, 11:59, 2012.
- 15-Luna G.L., Manual of histological staining of armed forces institute of pathology, 3rd ed., McGraw-Hill, USA, pp-18, 1968.
- 16-Bancroft , J . D .and cook , H . C . 1984 , Manual of Histological Techniques . Churchill Living stone . Curtis F . Methode de coloration elective du tissue conjonctif . *C R soc Biol* 1905 ; 58 : 1038 – 40 .
- 17- Sarikcioglu L, Yaba A, Tanriover G, Demirtop A, Demir N, Ozkan O, Effect of severe crush injury on axonal regeneration: a functional and ultrastructural study, *J Reconstr Microsurg*, 2007, 23(3):143–149.
- 18- Luís AL, Rodrigues JM, Geuna S, Amado S, Simões MJ,Fregnan F, Ferreira AJ, Veloso AP, Armada-da-Silva PA,Varejão AS, Maurício AC, Neural cell transplantation effects on sciatic nerve regeneration after a standardized crush injury in the rat, *Microsurgery*, 2008, 28(6):458–470.
- 19- Baptista AF, Gomes JR, Oliveira JT, Santos SM, Vannier-Santos MA, Martinez AM, High- and low-frequency transcutaneous electrical nerve stimulation delay sciatic nerve regeneration after crush lesion in the mouse, *J PeripherNerv Syst*, 2008, 13(1):71–80.
- 20- Kashani IR, Golipoor Z, Akbari M, et al. Schwann-like cell differentiation from rat bone marrow stem cells. *Arch Med Sci*. 2011;7:45–52.
- 21- Liao D, Gong P, Li X, et al. Co-culture with Schwann cells is an effective way for adipose-derived stem cells neural transdifferentiation. *Arch Med Sci*. 2010;6:145–51.
- 22- Lopatina T, Kalinina N, Karagyaur M, et al. Adipose-derived stem cells stimulate regeneration of peripheral nerves: BDNF secreted by these cells promotes nerve healing and axon growth de novo. *PLoS One*. 2011;6:e17899.
- 23-Kah-Hui Wong, Murali Naidu, Pamela David, Mahmood Ameen Abdulla, Noorlidah Abdullah, Umah Rani Kuppusamy, and Vikineswary Sabaratnam. Peripheral Nerve Regeneration Following Crush Injury to Rat Peroneal Nerve by Aqueous Extract of Medicinal Mushroom *Hericium erinaceus* (Bull.: Fr) Pers. (Aphylllophoromycetidae). Evidence-Based Complementary and Alternative Medicine. Volume 2011 (2011), Article ID 580752, 10 pages
24. Sozcukler A, Deksametazon, Hasarı S, and Sinir S. Comparison of the Effects of Local and Systemic Dexamethasone on the Rat Traumatic Sciatic Nerve Model. *Turkish Neurosurg*. 2013; 23: 623-629.
25. Sulu H, Altun M, Edriva B, Tura H and Sulu N. Comparison of the Effects of Local and Systemic Dexamethasone

on the Rat Traumatic Sciatic Nerve Model.

Turkish Neurosurg. 2013; 23: 623-629.

26-Aijaz A Khan, Nafis A Faruqi and Mohd Salahuddin Ansari. Effects of hydrocortisone on the sciatic nerve crush injury in adult rat

light microscopic study. *Current Neurobiology* 2014; 5 (1 & 2): 11-16 ISSN 0975-9042

27-Xinhong Feng and Wei Yuan. Dexamethasone Enhanced Functional Recovery after Sciatic Nerve Crush Injury in Rats. *BioMed Research International*. Volume 2015 (2015), Article ID 627923, 9 pages.

28-Hongzhi Sun, Tao Yang, Qing Li, Zhitu Zhu, Lei Wang, Guang Bai, Dongsheng Li, Qiang Li, and Wei Wang. Dexamethasone and vitamin B12 synergistically promote peripheral nerve regeneration in rats by upregulating the expression of brain-derived neurotrophic factor. *Arch Med Sci*. 2012 Nov 9; 8(5): 924–930.

29-Shunsuke Nishimoto, Hiroyuki Tanaka, Michio Okamoto, Kiyoshi Okada, Tsuyoshi Murase, and Hideki Yoshikawa. Methylcobalamin promotes the differentiation of Schwann cells and remyelination in lysophosphatidylcholine-induced demyelination of the rat sciatic nerve. *Front Cell Neurosci*. 2015; 9: 298.

30- David JB, Litchfield CR, Jeffrey MV: Spatiotemporal expression profiling of proteins in rat sciatic nerve regeneration using reverse phase protein arrays. *Proteome Sci*. 2012, 10: 9-10.1186/1477-5956-10-9.

31- Carr DF, Whiteley G, Alfirevic A: Investigation of inter-individual variability of the one-carbon folate pathway: a bioinformatic and genetic review. *Pharmacogenomics J*. 2009, 9: 291-305. 10.1038/tpj.2009.29.

32- Karem A, Omar K, Noor H: Evaluation of vitamin B12 effects on DNA damage induced by pioglitazone Mutation Research/Genetic. *Toxicol Environ Mutagen*. 2012, 748 (2): 48-51.

33- Rahim Hobbenaghi, Javad Javanbakht, Ehan Hosseini, Shahin Mohammadi, Pedram Moayeri, Mojtaba Rajabian, and Mehdi Aghamohammad Hassan. Neuropathological and neuroprotective features of vitamin B12 on the dorsal spinal ganglion of rats after the experimental crush of sciatic nerve: an experimental study. *Diagnostic Pathology* 2013:123. *BioMed Central Ltd*. 2013.

34- Okada K, Tanaka H: Methylcobalamin increases Erk1/2 and Akt activities through the methylation cycle and promotes nerve regeneration in a rat sciatic nerve injury model. *Exp Neurol*. 2010, 222 (2): 191-203.

35- Sun, H., Yang, T., Li, Q. et al. Dexamethasone and vitamin B(12) synergistically promote peripheral nerve regeneration in rats by upregulating the expression of brain-derived neurotrophic factor. *Arch Med Sci*. 2012; 8: 924–930.

36- Xu, G., Lv, Z.W., Feng, Y. et al. A single-center randomized controlled trial of local methylcobalamin injection

for subacute herpetic neuralgia. *Pain Med*. 2013; 14: 884–894.

37- Liao, W.C., Wang, Y.J., Huang, M.C. et al. Methylcobalamin facilitates collateral sprouting of donor axons and innervation of 2013; 8: e76302.

38- Andreea, R., Silvia, Oana, D., S. Raducan, Danina, M., O. Fira-Mladinescu, Rodica, L., Morphological and functional aspects of sciatic nerve regeneration after crush injury. *Morphol Embryol* 2013, 54: 735-739.

39- Chien-Hua Chen, Yin-Kai Huang, Fu-Shan Jaw. Ultrasound-guided Perineural Vitamin B12 Injection for Peripheral Neuropathy. June 2015 Volume 23, Issue 2, Pages 104–106.

40- Zeliha, Kurtoglu., Ahmet, H., Celal, B. Aysegul, T., Handan, C., Deniz, U., Mustafa, A. Effect of trapidil on the sciatic nerve with crush injury: a light microscopical study. *Neuroanatomy* 2004, 3: 54-58.

41- Watanabe T, Kaji R, Oka N, Bara W, Kimura J. Ultra high dose methylcobalamin promotes nerve regeneration in experimental acrylamide neuropathy. *Journal of neurological sciences*. 1994; 12: 140-143.

42- Dagum A. B. ,1998. Peripheral nerve regeneration, repair and grafting. *J Hand Ther* : 11 :11-117

43- Lee Goldman and Andrew I. Schafer , (Eds) , 2015. Neurological disease. Chapter 26 In: *Goldman-Cecil Medicine Textbook*. (25th)ed. EL. SEVIER.

44- Sinnatamby C.(Ed.) 2011. Introduction In : *Lasts Anatomy, Regional and Applied*. 12th ed. Churchill Livingstone.

45- Vinay Kumar, Abul K. Abbs and Jon C. Aster(Eds) 2013. Peripheral nerve and muscles In: *ROBBNS Basic Pathology*, 9th ed , ELSEVIER SAUNDERS. Chapter 21:797-801

46- Mixcoati-Zecuati, Quinonez-Bastidas G.N., Garam-Salas N.L., Ambriz-Tututi M., Araiza-Saldana C.I., Rocha-Gonzalez H.I. et al 2008. Synergistic anti-allodymic interaction between gabapentin or carbamazepine and either benfotiamine or cyanocobalamin in neuropathic rats. *Methods Find Exp Clin Pharmacol* ;30:431-441.

47- Galloway E.B., Jensen R.L., Dailcy A.T. Thompson B.G., Shelton C., 2005. Role of topical steroids in reducing dysfunction after nerve injury. *Microsurg*;16:8542-8546.

48- Cheshire J. , W. P. ,2002. Defining the role for gabapentin in treatment of trigeminal neuralgia: a retrospective study. *J pain* : 3 : 137-142.

49- Kopruszinski C. M. , Reis R. C. , Chichorro J.G. , 2012. B vitamins relieve neuropathic pain behaviors induced by infraorbital nerve constriction in rats. *Life Sci* : 10, 91 (23-34): 1187-1195.

50- Muthal A.P., Morani A.S., Bodhankar S.L., 2008. Neuroprotective Effect of Ultra-High Dose of Methylcobalamin in Models of Mononeuropathy in rats. *Pharmacology on line*;2:282-295.

- 51- Stratos I. , Li z. , Herlyn P. , Rotter R. , Behrendl A. K. , Mittlmeier T. and Vollmar B., 2013. Vitamin D increases Cellular Turn over and Functionally Restores the Skeletal Muscle after Crush Injury in Rats. *Am. J Pathol* : 182 :896-904.
- 52-Kalid M. Alkharfy , Nasser M. Al-Daghri , Muktar and Sobhy M. Yakout ,2012. Effects of vitamin D treatment on skeletal muscle histology and Ultrastructural changes in Rodent Model. *Molecules* : 17 :9081-9089.
- 53- Milly Ryan – Harshman , 2007. Carpal tunnel syndrome and vitamin B6. *Can Fam Physician* : 53 (7):1161-1162.
- 54- Reyes-Garcia G.,Caram-Salas N.L.,Medina-Santillan R. and Granados-Soto V. ,2004. Oral administration of B vitamins increase the antiallodynic effect of galapentin in the rat. *Proc West pharmacol Soc* ; 47:76-79.
- 55-Stracke H., Lindemann A. and Federlin k.,1996. A Benfotiamine-vitamin B Combination in treatment of diabetic Polyneuropathy. *EXP Clin Endocrinol Diabetes*;104(4):311-316.
- 56- Lunborg G. (Ed). 2005. Nerve injury repair : regeneration, reconstruction and cortical remodeling , 2nd (ed.). Churchill Livingstone , Edinburg :27-32.
- 57-Geuna S. , Nicolinos S. , Raimondo S. , Gambarotta G. , Battisten B. ,Tos P., Perroteau I., 2007. Nerve regeneration along bioengineered Scaffolds. *Micro surgery* : 27(5) :429-438.
- 58-Goodyear-Smith F. and Arroll B. ,2004. What can family physicians offer patients with carpal tunnel syndrome other than surgery ? A systemic review of non surgical management. *Ann Fann Med* : 2:267-273.
- 59-Ang C. D. ,Alvair M. J. , Dans A. L. , Bautisula-Velez G. G. , Villaruz-Sulit M. J. , Co H. V. ,Bantista M. R. and R. and Roxas A. A. ,2008. Vitamin B for treating peripheral neuropathy. *Cochrane-Data base sys Rev* :16 (3).
- 60- Yuksel T. N. , Halici Z. , Demir R. , Cakir M. , Calikoglu C. ,Ozdemir G and Unal D. ,2014. Investigation of the effect of telmisartan on experimentally induced peripheral nerve injury in rats. *Int J neuro sci* : 28 (1):1-32.
- 61- Jolivalt C.G.,Mizisin I.M.,Nelson A.,Cunha J.M.,Ramos K.M. and Bonke D. *et al*,2009. B vitamins alleviate indices of neuropathic pain in diabetic rats. *Eur J Pharmacol*;612:41-47.
- 62- Denise R. Ferrier (Ed.) , 2014. Vitamins In : Lippincotts illustrated Reviews Biochemistry. 16th ed Lippincott Williams and WilKins. Chapter 28:378.
- 63-Lee Goldman and Andrew I. Schafer , (Eds) , 2015. Neurological disease. Chapter 26 In: Goldmen-Cecil Medicine Textbook. (25th)ed. EL. SEVIER.
- 64-Kennelly Peter J. , Bo than Kathleen , Bender David , Weil P. Anthony and Rod well Victor (Eds), 2015. Micronutrients: vitamins and minerals In: Harpers illustrated Biochemistry.30th ed. Mc Graw Hill Education. Chapter 44.
- 65-Scalabrino G. and Peracchi ,2006. New insights into the pathophysiology of cobalamin deficiency.*Trends Mol. Med* :12 :247-254.
- 66-Xinhong Feng and Wei Yuan, 2015. Dexamethasone enhanced functional recovery after sciatic nerve crush injury in rats. *Bio Med Research International*. 2015. Article ID 627923 : 9pages
- 67- Dror D. K. and Allen , 2008. Effect of vitamin B12 deficiency on neurodevelopment in infants : Currant Knowledge and possible mechanism. *Nutr Rev* :66 :250-255.