

Case Report

A variation in the high division of the sciatic nerve and its relation with piriformis muscle-case report

K V Amrutha #, Abraham J, Kamil Jemal Lale***

Department of Anatomy, school of Medicine, Yirgalem medical college and Hospital, Ethiopia#

Academic Vice Dean, Yirgalem Medical College and Hospital, Ethiopia**

Address for correspondence-Dr. Joseph Abraham, Department of Anatomy, school of medicine, Wollega university, Ethiopia*

ABSTRACT: Sciatic nerve is a broad, thickest and the largest nerve of body, arising from sacral plexus. In our case, sciatic nerve already divided in pelvis, and common peroneal nerve came out above an undivided piriformis, tibial nerve below Piriformis. According to different study, it shows that there are many variations in sciatic nerve division especially in higher divisions. This knowledge is also very important for nurses and junior doctor to prevent deep intramuscular injection hazards in gluteal region.

Key Words: Sciatic Nerve (SN), common fibular nerve (CFN), Piriformis, variation, gluteal region, pelvis.

Introduction

Sciatic is Greek word derived from "Ischiadicus". The sciatic nerve is also known as the ischiadic nerve or ischiatic nerve¹. Sciatic nerve is a broad, thickest and the largest nerve of body, arising from sacral plexus. The sciatic nerve is formed in the pelvis by joining anterior divisions of L4-S3 spinal nerve roots. It is almost 2 cm wide at its origin near the sacral plexus. Normally it emerges through the greater sciatic foramen, leaves pelvis and enters into gluteal region by passing below piriformis as a single nerve encompassed by a single epineural sheath. It divides subsequently into two terminal nerves i.e., tibial nerve and common peroneal nerve (common fibular nerve), usually at superior angle of popliteal fossa. There are both motor and sensory fibers in it.

The motor branches of the nerve supply the posterior group of thigh muscles as well as two joints of the lower limb: femoral and knee joint. Its sensory branches supply the whole tibial and foot areas with the exception of the anteromedial tibial region and the medial margin of the foot². Pain caused by a compression or irritation of the sciatic nerve is called sciatica. The sciatica symptoms include nerve pain, numbness, tingling, and weakness. It may include inability to walk depending upon where the pressure of the sciatic nerve occurs. Investigations are CT-scan, MRI, EMG (electrical activity of the muscle) and Nerve conduction test and Blood tests are routinely done to identify nerve pathology.

The knowledge of the variation in the level of bifurcation of the sciatic nerve should be kept in consideration while performing surgical exploration. Clinical significance and some relevant previous studies will be presented in this work. A frequent variation in this regard calls for surgeon's attention to avoid error in treatment¹

Case report

Here we came across a case of high division of sciatic nerve with in pelvis and variations in its outcome from greater sciatic foramen in relation to piriformis muscle in male

cadaver on right side during routine dissection for undergraduate students in department of anatomy, Amala Institute of Medical Sciences, Thrissur, India. On left side, division was normal. In order to reveal the high division of the main trunk of the sciatic nerve into terminal branches we carefully identified every branch originating from the main trunk. For this first the gluteus maximus was elevated to explore the piriformis, the superior gemellus, the obturator internus, the inferior gemellus and the quadratus femoris. Following proper exposure of the pelvis, the evidence of variation in the Sciatic Nerve was recorded. The location where the SN exits the pelvis and the level of the Sciatic Nerve division were all recorded. Additional calculation was performed to compare left and right extremities.

Observations

Sciatic nerve already divided in pelvis and its two divisions came out differently from pelvis, one (Common Peroneal) came out above an undivided piriformis & other (Tibial) came out below Piriformis. (Fig. No 1). Later on both nerves supplied muscles of their destination.

Fig no 1

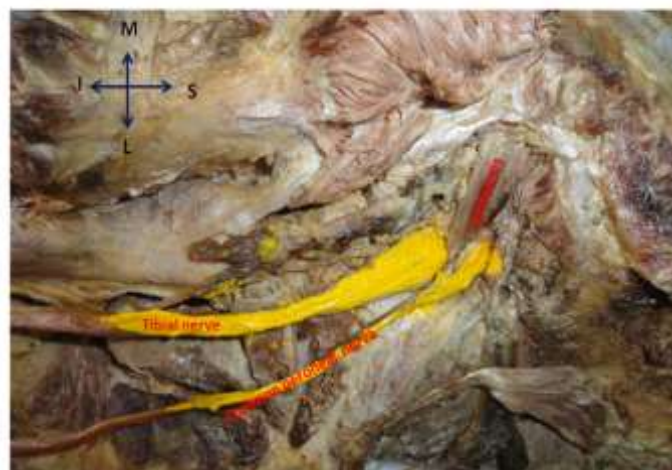


Fig no 1-showing common peroneal nerve passing above piriformis

Discussion

Anatomical variations of sciatic nerve can contribute to Piriformis syndrome and sciatica. According to different study, it shows that there are many variations in sciatic nerve division especially in higher divisions. There are different types of high divisions of sciatic nerve within pelvis, usually bilateral and if it is unilateral then other side will mostly remain normal. Many authors have attempted classification of high divisions of sciatic nerve.

Beaton & Anson classified variations of the piriformis and SN in 120 specimens in 1937, and in 240 specimens in 1938. Their classification, known as the Beaton & Anson classification, is as follows:

- Type 1: Undivided nerve below undivided muscle
- Type 2: Divisions of nerve between and below undivided muscle
- Type 3: Divisions above and below undivided muscle
- Type 4: Undivided nerve between heads
- Type 5: Divisions between and above heads
- Type 6: Undivided nerve above undivided muscle³

Babinski and Mas et al describe a new anatomical variation in which the common fibular nerve passed superior, and the tibial nerve inferior, to the superior gemellus muscle. This variation may be nominated as Beaton & Anson type 7^{4,5}. Below there

are six different types of higher divisions which was observed in previous studies of different researchers. These classifications are especially necessary as they help surgeons in assessing cause and site of compression of SN and accordingly treatment differs. It is usually seen that when SN shows high branching pattern, that one of the branch pierces piriformis. But divided piriformis is not usually seen. Divided piriformis is said to be a very important cause of piriformis syndrome (when present), as CFN passing between two divisions is usually compressed and irritated resulting in the symptoms⁶. Papadopoulos et al. mention that incidence of piriformis syndrome is six times more frequent in females⁷. Jawish et al. found only one case of divided piriformis among 26 cases selected from 3550 cases complaining of sciatica⁸. Mas et al. have also reported a case of bilateral high division of SN but with tibial nerve passing under gemellus superior, unlike our case where CFN is passing between two heads of piriformis as in our case⁵. Chiba reported that CFN passed through the piriformis in 34% of the cases in another study using 514 extremities (table 1)⁹. Machado et al performed a gluteus dissection in 100 fetuses and reported three types of variation, including type 1 where the CFN penetrated the piriformis and the TN passed under the piriformis (16%), type 2 where the CFN passed above the piriformis and the TN passed under the piriformis and type 3 where the SN penetrated the piriformis¹⁰. Ugrenovic et al. found high division of the SN in 27.5% of the specimens in a cadaveric study performed in 100 fetuses¹¹.

Table 1

Name of Investigators	Type 1	Type 2	Type 3	Type 4	Type 5	Type 6
Beaton & Anson. 120 cadavers	84.2%	11.7%	3.3%	0.8%		
Pecina .130cadavers		6.15%				
Beaton. 240 cadavers	90%	7.1%	2.1%	0.8%		
Chiba.14xtremities		34%				
Uluutku&Kurtoğlu. 25 fetuses	74%	16%	10%			
Ugrenovic et al.100 fetuses	96%	2.5%	1.5%			
Moore&Dalley .650extremities		12.2%	0.5%			
Pokorny et al. 91 cadavers	79.1%	14.3%	4.4%	2.2%		
Sayson et al						Single case
Shailesh patel et al.86 extremities	91.8%					

Our case was of type 3 on right side and type 1 on left side.

It has been observed that SN usually shows a lot of variations in its division, especially its high division. Small pooled results of 18 previous studies and 6,062 cadavers and found that prevalence of this variant in cadavers was 16.9% and in surgical case series was 16.2% . The piriformis and SN anomalies have ranged from 1.5-35.8% in dissected human specimens as published in literature¹² . Previous anatomical studies demonstrated 15–30% variation in the relationship between the piriformis and the SN. Topographic variations of the relationship of the sciatic nerve and piriformis muscle and

its relationship was studied by Pokorny et al (table 1). The authors studied 91 cadavers and found an atypical relationship in 19 cadavers (20%). In their study, individual variations were found. According to them SN exist below the piriformis muscle in 79.1% cases, SN separates into divisions, one branch passing through the muscle and other below it (14.3%).

An unsplit nerve passes through piriformis muscle (2.2%). The incidence of anatomical variation of both SN and piriformis is 15-30%¹³. Sharma et al. observed in routine dissection of 60 years male cadaver that two divisions of SN were separate in the gluteal region on both the sides with TN

passing below the piriformis and CPN piercing the piriformis muscle. The high division may account for failures in the popliteal block¹⁴. Saleh et al. mentioned in their studies that SN division occurs at a variable level about the 50-180 mm above the knee and may account for frequent failures with popliteal blocks. According to the classical teaching the popliteal block is done by insertion of the needle at 100 mm above the popliteal crease¹⁵. Variations in the high division of the SN and relationship between the SN and the Piriformis were studied by Guvencer et al. Their study included 25 male cadavers. Their results were that in 52% of cases the SN exited as whole nerve without any division, whereas in 48% a high division was observed. According to them, 24% of cases CPN left the pelvis above and TN below the piriformis and 24% of cases followed different route. The differences in their exit routes of these two nerves are important clinical etiology of sciatica and require reviewing the Piriformis syndrome¹⁶. Arifoglu et al. [type 2 of Beaton] reported a case with double superior gemellus and double piriformis muscles associated with the SN dividing high and passing between two Piriformis. It has not previously been described in the literature. Supernumerary superior gemellus and piriformis muscles may exert pressure on the SN and should be taken into account by the clinicians¹⁷. The type 6 variation, a variation defined hypothetically by Beaton & Anson, was reported in one case by Ozaki et al.¹⁸ and Sayson et al¹⁹

Conclusion

Anatomical variations in gluteal region such as above are very important for surgeons, as this is the area of frequent surgical manipulation. The sciatic nerve is frequently involved in daily medical practice of neurology, orthopedics, rehabilitation and anesthesia. Its long course makes it vulnerable to nerve injury. The principal author was confronted with SN and its bifurcation variations in the routine cadaveric dissections while teaching the undergraduate students. This knowledge is also very important for nurses and junior doctor to prevent deep intramuscular injection hazards in gluteal region. This case discussion emphasizes proper clinical implications, for the surgeons to practice efficient surgical recombination and avoid errors. Further radiological studies addressing the aforementioned variations should be carried out in cases with atypical sciatica.

Acknowledgement

No thanks are complete unless it is first to Almighty God who has given us the ability to think and do some work which benefits humankind. Sincerely acknowledge my undergraduate students and also dissection hall technicians for their help during dissections of the cadavers.

References

1. Saritha S*, Praveen Kumar M and Supriya G. Anatomical Variations in the Bifurcation of the Sciatic Nerve, A Cadaveric Study and its Clinical Implications. *Anat Physiol* 2012, 2:5
2. Shailesh Patel, Mitesh Shah, Rakesh Vora, Ankur Zalawadia, S P Rathod. A variation in the high division of the sciatic nerve and its relation with piriformis muscle national

journal of medical research vol 1 issue 2 oct – dec 2011 : issn 2249 4995 page

3. Beaton LE, Anson BJ: The relation of the sciatic nerve and its subdivisions to the piriformis muscle. *Anat Rec* 1937; 70: 1–5
4. Babinski MA, Machado FA, Costa WS: A rare variation in the high division of the sciatic nerve surrounding the superior gemellus muscle. *Eur J of Morphol* 41(1): 41–42, 2003
5. Mas N, Ozekşi P, Ozdemir B, Kapakin S, Sargon MF, Celik HH, Yener N: A case of bilateral high division of the sciatic nerves, together with a unilateral unusual course of the tibial nerve. *Neuroanatomy* 2: 13–15, 2003
6. Demiryurek D, Bayramoglu A, Erbil M, Aldur MM, Sargon MF. Bilateral divided piriformis muscle together with the high division of the sciatic nerve. *Gazi Med J*. 2002; 13: 41–44.
7. Papadopoulos SM, McGillicuddy JE, Albers JW. Unusual cause of 'piriformis muscle syndrome'. *Arch Neurol*. 1990; 47: 1144–1146.
8. Jawish RM, Assoum HA, Khamis CF. Anatomical, clinical and electrical observations in piriformis syndrome. *J Orthop Surg Res*. 2010; 5: 3.
9. Chiba S: Multiple positional relationships of nerves arising from the sacral plexus to the piriformis muscle in humans. *Kaibogaku Zasshi* 67(6): 691–724, 1992
10. Machado FA, Babinski MA, Brasil FB, Favorito LA, Abidu- Figureiedo M, Costa MG: Anatomical variations between sciatic nerve and piriform muscle during fetal period in human. *Int J Morphol* 21(1): 29–35, 2003
11. Ugrenovic S, Jovanovic I, Krstic V, Stojanovic V, Vasovic L, Antic S, Pavlovic S: The level of the sciatic nerve division and its relations to the piriform muscle. *Vojnosanit Pregl*. 62(1): 45–49, 2005
12. Smoll NR. Variations of the piriformis and sciatic nerve with clinical consequence: a review. *Clin Anat*. 2010; 23: 8–17.
13. Pokorny D, Jahoda D, Veigl D, Pinskerova V, Sonsa A: Topographic variations of the relationship of the sciatic nerve and the piriformis muscle and its relevance to palsy after total hip arthroplasty. *Surg Radiol Anat* 28: 88–91, 2006
14. Sharma T, Singla RK, Lalit M (2010) Bilateral eventration of sciatic nerve. *JNMA J Nepal Med Assoc* 50: 309-312.
15. Saleh HA, El-Fark MM, Abdel-Hamid GA (2009) Anatomical variation of sciatic nerve division in the popliteal fossa and its implication in popliteal nerve blockade. *Folia Morphol (Warsz)* 68: 256-259
16. Guvencer M, Iyem C, Akyer P, Tetik S, Naderi S (2009) Variations in the high division of the sciatic nerve and relationship between the sciatic nerve and the piriformis. *Turk Neurosurg* 19: 139-144.
17. Arifoglu Y, Sürücü HS, Sargon MF, Tanyeli E, Yazar F (1997) Double superior gemellus together with double

piriformis and high division of the sciatic nerve. *Surg Radiol Anat* 19: 407-408.

18.Ozaki S, Hamabe T, Muro T: Piriformis syndrome resulting from an anomalous relationship between the sciatic nerve and piriformis muscle. *Orthopedics* 22(8): 771–772, 1999

19.Sayson SC, Ducey JP, Maybrey JB, Wesley RL, Vermilion D: Sciatic entrapment neuropathy associated with an anomalous piriformis muscle. *Pain* 59: 149–152, 1994