

---

**Research Article**

## **Surgical treatment of complicated hepatic hydatid cyst**

*M. J. Fassi Fihri<sup>1</sup>, M. Lahkim<sup>1</sup>*

**Postal address of the authors:**

<sup>1</sup>Service de chirurgie générale, Hôpital Militaire Avicenne de Marrakech, Maroc

**&: Mailing address and e-mail of the corresponding author:**

Service de chirurgie générale, Hôpital Militaire Avicenne de Marrakech, Maroc  
dr.fassifihri@gmail.com

---

**ABSTRACT:**

Hydatidosis is a parasitic disease considered benign but can become dangerous because of its complications. It is a real public health problem in the world by its frequency, morbidity, and its potential mortality. This work is a retrospective study, which was carried out on 15 patients with hydatid cyst of the liver complicated, admitted between 2012 and 2015 at the department of general surgery of the military Hospital Avicenne. The aim of this study is to report the epidemiological, diagnostic features and therapeutic management. The results of the epidemiological study showed that the hydatid cyst of the liver affects young adults with an average age of 38,5 years and a clear male predominance. The complicated form represents 15% of cases. The clinical expression was dominated by the right upper quadrant pain (80%) and fever (70 %). The most common complication was represented by fistula in the bile ducts found in 60% of cases. Ultrasound is the main paraclinical examination that allows the diagnosis. Cysts were type III in 70 % of cases, localized in the right lobe in 80 % of cases. Surgical treatment is performed in all cases. Medical therapy was used in 2 cases in association with surgery. Laparotomy was performed for all patients. Conservative procedure, which is the resection of the bulging dome, was used in all cases excepted for one patient who had a liver hydatid cyst in central location, who was treated by a trans-fistulo-oddian internal drainage. The average length of hospitalization was 17 days. Our results were satisfying with weak rate of morbidity (30%) and no recurrence. Prophylaxis is the best treatment in endemic areas.

---

**KEYWORDS:** Hydatidosis, complicated, fistula, rupture, infection

---

### **Introduction**

The hepatic hydatidosis is a real problem of public health in the world, especially in countries with a high hydatid endemicity. Its annual incidence in Morocco is 12/100 000 inhabitants [1]. By its clinical latency, the diagnosis is made more often at the stage of complications. The severity of this condition is evidenced by its morbidity and its mortality that could reach 14% in some series [2]. The purpose of this work is to study the epidemiological, clinical, para clinical characteristics and therapeutic management of the complicated hepatic hydatid cyst in our structure, and compare our results to a literature review.

### **Patients and methods**

This retrospective study focused on 10 cases, spread over 4 years (from January 2012 to December 2015), was conducted at the service of General Surgery of the military hospital Avicenne in Marrakech.

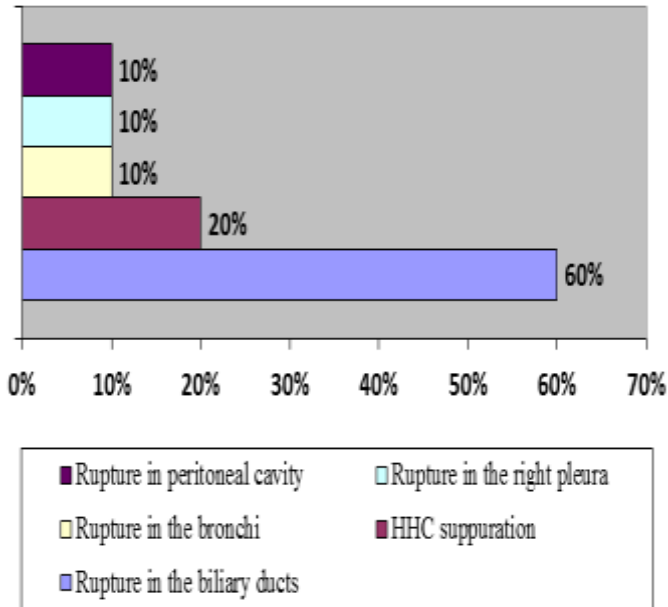
Medical records of patients with complicated hepatic hydatid cyst (HHC) who were managed between January 2012 and December 2015 were retrospectively reviewed. Variables were

extracted on a structured questionnaire and data were analyzed for age, sex, presenting symptoms and symptom duration, clinical signs, paraclinical investigations, modalities of treatment and length of hospital stay.

Small cysto-biliary fistula discovered in per-operative without passage of hydatid material in the biliary ducts were excluded.

### **Results**

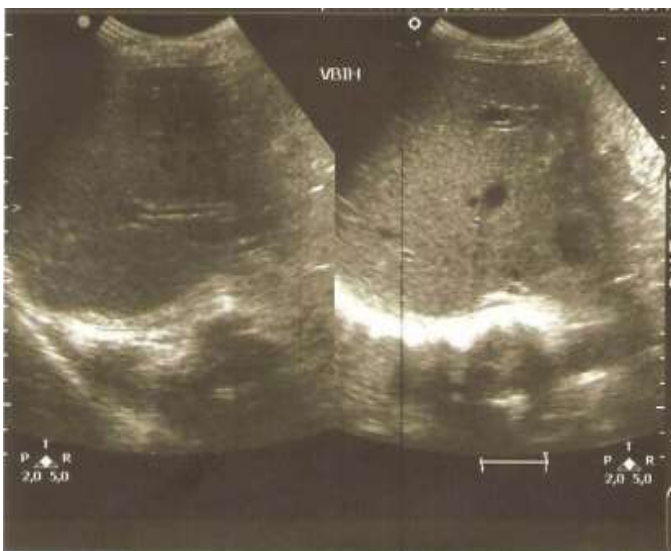
During the period of the study, ten cases of complicated HHC were diagnosed. In our series, the age of patients ranged between 23 and 54 with an average of 38.5 years old. Our series included 60% of males and 40% female. Seventy-percent of patients were from urban origin against 30% from rural origin. Fistulisation in the biliary ducts was the most common complication (Figure 1), having been found in six patients (60%): three cases (30%) has been discovered on the occasion of an angiocholitis and 3 others (30%) at a jaundice.



**Figure 1:** Distribution of the complications of the hepatic hydatid cyst in our series

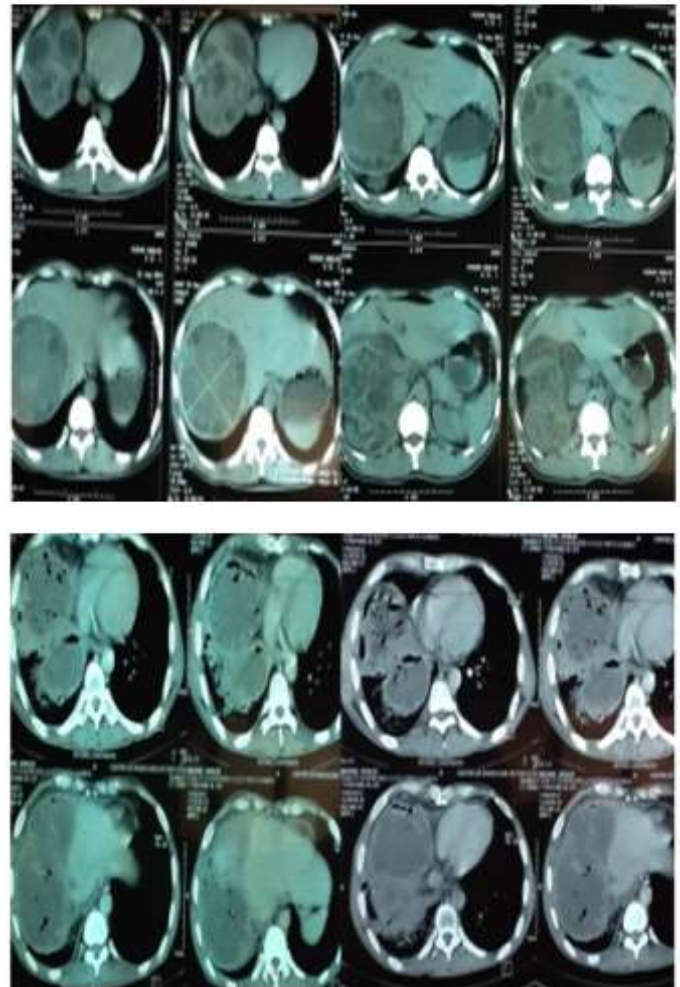
The suppuration of the cyst was found in two cases (20%) of which one case (10%) presented an infectious syndrome and another case (10%) presented a cystic content infection associated with a cyst fistulisation in the pleura and submitting right pleurisy. The cystic rupture in the bronchi was diagnosed in a single patient (10%) who's presenting a hydatid vomiting. The cystic rupture in the peritoneal cavity has been diagnosed in a single case (10%) with an acute peritoneal syndrome without allergic reaction.

The ultrasound was the first imaging exam to ask. It was sufficient to make the diagnosis in the majority of cases (Figure 2).



**Figure 2:** Echographic image of a type IV HHC with intrahepatic biliary ducts dilatation

The hydatid cysts were type III of Gharbi's classification in 70% of cases and type IV in 30%, and localized in the right hemi-liver in 80%. A CT scan was the second imaging modality, with a higher sensitivity, performed in eight patients (80%) (Figure 3).



**Figure 3:** Scannographic images of HHC fistulized in bronchi (air in the cysts).

The use of hydatid serology was done in case of doubt. The preparation by a triple antibiotic therapy was required in seven cases (70%).

The treatment was based exclusively on conventional surgery by a right subcostal incision. The hydatid cyst was treated by a conservative surgical procedure by resection of the protruding dome in all cases, except in one case where the location of the cyst was centro-hepatic. Fistulisation in the biliary ducts was treated by trans-fistulo-oddian drainage in one case (10%), a bipolar drainage in 2 cases (or 20%), and a kysto-biliary disconnection in 3 cases (30%). The rupture in the bronchi was treated by a suture of the diaphragmatic breach. The HHC superinfected and fistulized in the right pleural cavity was treated by a suture of the diaphragmatic breach and a right pleural drainage. The suppuration of the cyst was treated by a surgical drainage, a blindness of kysto-biliary fistula and antibiotherapy adapted to the antibiogram. The rupture in the abdominal cavity has been processed by a peritoneal toilet.

The drainage of the residual cavity was secured by a sonde with double current (Salem sonde) or by a Redon drain. Anti-helminthic treatment has been prescribed in two cases (20%) in association with surgical treatment. The duration of stay post-procedure was 17 days with extremes ranging from 5 to 43 days. The follow was simple to seven cases (70%), while three cases (30%) presented complications: a case of post-operative peritonitis, a case of extended biliary fistula and a

case of pneumonia. Evolution has been clinically and biologically, judged well.

### Discussion

The discovery of HHC is in the majority of cases at the stage of complications. On a series of 125 HHC, FOURATI and coll. [3] found 120 cases of complicated HHC (96%). However, in our series, the HHC complications rate was 15%, this rate is comparable to a multicentric study reported by the Tunisian society (18% of cases) [4]. Our patients were primarily male (60%), unlike the literature that showed a predominance of female gender (68%) [5]. Our study found often young adults with an average age of 38.5 years that was affected, also found in another Moroccan study [6]. The majority of our patients comes from urban areas, unlike literature that reports the prevalence of the rural area. The complications was dominated by the fistulisations of the HHC, especially in the biliary ducts.

According to the ERGUNEY study, these fistulas are found in 75% of cases [7]. They were diagnosed in 60% in our series. The ultrasound remains key for diagnostic examination, but CT has high sensitivity and specificity for hepatic hydatid disease [8]. On the treatment plan, the complicated HHC is a surgical indication of need [9]. Pre-operative preparation by a triple antibiotic first probabilistic planning is imperative for some patients [9]. The right subcostal incision has been predominant, in accordance with literature [10]: it allows access to all liver segments and can be expanded to the left to treat a left liver HC or a splenic HC associated. The median incision is indicated especially for the left liver HC [10].

The sterilization of the operative field was made by hypertonic saline (3%), joining the recommendations of literature, view its usability, its excellent tolerability, its experimental and clinical efficiency and its reduced risk of sclerosing cholangitis [11]. After evacuation of the cyst, a systematic research of biliary fistula starts with the review of hydatid liquid, whose bilious aspect signs kysto-biliary communication. Smoothing of the crevices of the pericyst then a per-operative cholangiogram allows to specify the seat and the importance of the fistula. This review has been practiced in our series in six patients. The most used method in the treatment of the HHC is the conservative method: it is dominated by resection of the protruding dome, or Lagrot's procedure, whose principle is to resect the pericyst cap which is protruding on the surface of the liver. This is a simple, fast, little bleeding method but source of significant morbidity [12, 13]. This method was practiced in all our patients, except one case where the cyst was in a centro-hepatic localization. The radical methods are the total pericystectomy and the hepatic resection that appear disproportionate for a minor ailment and especially rampant in endemic countries [14]. The residual cavity was drained by a Redon drain. Kysto-biliary fistula can be treated in several ways: A simple cracking in a bile duct is blocked by a blindness with the realization of a bipolar drainage; it has been practiced in two patients in our study. When kysto-biliary fistulas are wide and focus on major ducts, the suture becomes dangerous with a risk of vascular injury

and secondary stenosis of the duct. The method of choice is kysto-biliary disconnecting type Perdomo, due to its simplicity and its immediate and long-term results, which are very satisfactory [15]. We has resorted to this technique in our study in three patients. When the biliary fistula is large (diameter at least 5 mm), regardless of the location of the cyst and regardless the type lateral or terminal of the fistula, the trans-fistulo-oddian internal drainage is then indicated [9]. This technique has been used in one case in our study with a centro-hepatic cyst. The breaking of the hydatid cyst in the bronchi is handled by a closure of the breach after release of the diaphragm and complete hepato-diaphragmatic disconnect [16, 17], practiced in one case in our study. Pleuro-pulmonary lesions, sometimes macroscopically impressive, may be reversible after abdominal time. The patient is then monitored and controlled by postoperative CT. Most often, a laparotomy permits manage the disease. A thoracotomy becomes essential to achieve limited pulmonary resection in case of irreversible lesions with a hepatized and necrotic pulmonary parenchyma with a hydatid cave [10, 18, 19]. In case of acute opening of the cyst in the pleura, a first thoracotomy is performed allowing the evacuation and the sterilization of pleural contents and even of the cyst, through a phrenotomy insuring the protruding dome resection with a drainage of the residual cavity. An endoscopic sphincterotomy may be offered in the postoperative period in the event of concurrent opening of the HHC in the biliary [10]. In our study, a drainage associated with a suture of the diaphragmatic breach and a pleural drainage were performed in a single case. The suppuration of the HHC is treated by surgical drainage [9], and antibiotherapy adapted to the antibiogram results. The cystic rupture in the peritoneal cavity is treated by peritoneal toilet after resuscitation of a possible anaphylactic shock, followed by anti-helminthic treatment during 3 months [9]. Performed in a single case, anti-helminthic treatment taken orally has a direct action on the scolex and also on the membrane whose permeability is reduced. Albendazole (ABZ) is the most used. The ABZ-praziquantel association would be more effective than the ABZ alone. The ABZ is prescribed at a dose of 10 to 15 mg/kg/d in two takes orally. Currently, this treatment is continuous over three to six months [20]. The ABZ is prescribed in combination with surgery, and is given four days to one month before surgery, then three months after [21]. In our series, the medical treatment has been prescribed in two cases in association with surgery. HHC surgery remains encumbered by complications, responsible for an extended hospital stay and a high mortality. Morbidity is dominated by external biliary fistula, which concerns especially the wide-open cysts in the biliary. Its rate was 6% in a Tunisian series [22]. In our study, postoperative morbidity rate was 30% and is represented by an extended fistula, post-operative peritonitis and pneumopathy.

The postoperative stays depend on the post-operative evolution of the cyst. This stay was in the average of 21 days in the single suites and 57 days in complicated suites in the CHIPPONI series [23]. In our study, the stay post procedure was 17 days. Mortality from this disease was 4.5%. Since

then, it has declined significantly and does not exceed 2% [24, 25]. We did not record any mortality in our study.

### Conclusion

The complications of the HHC are still frequent in our endemic environment. Only surgical treatment is effective, but remains encumbered by a significant morbidity, hence the interest of campaigns of awareness and prevention. The early diagnosis of hydatid disease remains the key to a simple and effective conservative treatment.

### Conflict of interests

The authors state no conflict of interest.

### Contributions of the Authors

All authors have contributed to the editing of this manuscript and read and approved the final version.

### References

- 1- Carmoi T, Farhouat P, Nicolas X, Debonne JM, Klotz F. Kyste hydatique du foie. EMC (Elsevier Masson SAS, Paris), Hépatologie 7-023-A-10, 2008.
- 2- Ennabli K., Gharbi S. Les kystes hydatiques du foie ouverts dans les voies biliaires. A propos de 78 cas opérés au CHU de SOUSE. Maghreb. Inf. Med. 1981, 8,44-48.
- 3- Fourati M., Benyouness M. A., Benyouness A., Mamoun A., Aiouaz A., Akrouit J. Bilan de 5 ans de chirurgie du kyste hydatique du foie à l'hôpital HABIB Thameur de Tunis. Tunis. Med. 1977,55,157-166.
- 4- Zaouche A. La chirurgie des kystes hydatiques du foie. Étude multicentrique tunisienne à propos de 2 013 cas. Tunis: STC; 1994.
- 5- Mountassir Moujahid, Mohamed Tarik Tajdine. Les kystes hydatiques rompus dans les voies biliaires : à propos de 120 cas. Pan African Medical Journal. 2011;10:43.
- 6- Settaf A., Bargach S., Aghzadi R., Lahlou MK., Oudghiri M. Traitement de la fistule kysto-biliaire du kyste hydatique du foie : à propos de 33 cas. J Chir (paris) 1991,128:133-8.
- 7- Ergüney S., Tortum O., Haydar Paspinar A., Ertem M.,Gazioglu. Les kystes hydatiques compliqués du foie. Ann Chirg. 1991,45,7,584-589.
- 8- Polat P, Kantarci M, Alper F, Suma S, Koruyucu MB, Okur A. Hydatid disease from head to toe. Radiographics 2003 ; 23: 475-494; quiz 536-537
- 9- F. Noomen, A. Mahmoudi , Md. Fodha, M. Boudoukhane, A. Hamdi, M. Fodha traitement chirurgicale des kystes hydatiques du foie EMC-Techniques chirurgicales-Appareil digestif 40-775,2013.
- 10- A. Zaouche, K. Haouet traitement chirurgicale des kystes hydatiques du foie EMC (Elsevier Masson SAS, Paris), Techniques chirurgicales-Appareil digestif, 40-775,2006:17p.
- 11- Mahdi Bouassida, Mohamed Mongi Mighri, Mechaal Benali, Fathi Chebbi, Hassen Touinsi, Sadok Sassi Réaction à Moujahid et al. : Les kystes hydatiques du foie rompus dans les voies biliaires : à propos de 120 cas. Pan Afr Med J. 2012;11:35.
- 12- Daali M, Fakir Y, Hssaida R, Ameer M, Abbar M. Les kystes hydatiques du foie rompus dans les voies biliaires-à propos de 64 cas. Ann Chir. 2001;126:242-245
- 13- Bedrili A, Sakrak O, Sozuer EM, Kerek M, Ince O. Surgical management of spontaneous intrabiliary rupture of hydatid liver cysts. Surg Today. 2002;32 (7):594-597.
- 14- Vladoov NN. Intraoperative choledochoscopy for the management of liver hydatid opened to the biliary tract. J Gastroenterol Hepatol. 2004;19(7):836-837.
- 15- Perdomo R, Morelli R, Carriquiry L, Chifflet J, Bergalli L. Cholédocostomie trans-hépatico-kystique en cas de kyste hydatique ouvert dans les voies biliaires. Nouv Presse Med. 1977 Mar 5;6(9):747-9.
- 16- Demirleau J. Traitement des kystes hydatiques du foie ouverts dans les bronches ou la plèvre. Mem Acad Chir 1956;82:470-479.
- 17- Galindo R., Laraki A., Bartal M. À propos du traitement chirurgical des fistules bilio-bronchiques et bilio-pleuro-bronchiques d'origine hydatique. Ann Chir Thorac Cardiovasc 1975;29:147-149
- 18- Kabiri FH, Traibi A, Arsalane A. Fistule bilio-bronchique d'origine hydatique : à propos d'un cas et revue de la littérature. Rev Pneumol Clin 2011;67:380-3.
- 19- Sakhri J, Ben Ali A, Letaief R, Derbal F, Dahmen Y, Ben Hadj Hmida R. Les kystes hydatiques du foie rompus dans le thora. J Chir 1996 ;133 :437-41.
- 20- Morris DL, Chinnery JB, Georgiou G, Stamanakis G, Golemaitis B. Penetration of albendazole sulphoxide into hydatid cysts. Gut 1987;28:75-80.
- 21- WHO Informal Working Group on Echinococcosis. Guideline for treatment of cystic and alveolar echinococcosis in humans. BullWorld Health Organ 1996;74:231-42.
- 22- Zaouche A, Haouet K, Jouini M. Manangement of liver hydatid cyst with large bilio cyst fistula : multicenter retrospective study. World J Surg 2001;25:28-39.
- 23- Chipponi., Huglier M. Les kystes hydatiques du foie opérés en France. Epidémiologie, attitudes diagnostiques et thérapeutiques sur 1306 cas. Gastro-entéro-clin. Biol. 1986,10,419-423.
- 24- Malik AA, Bari SU, Amin R, Jan M. Surgical management of complicated hydatid cyst of the liver. World J Gastrointest Surg 2010;2;78-84.
- 25- El Malki HO, El Mejdoubi Y, Souadka A, Mohsine R, Ifrine L, Abouqal R, et al. Predictive factors of deep abdominal complications after operation for hydatid cyst of the liver: 15 years of experience with 672 patients. J Am Coll Surg 2008;206:629-37.