

A Rare Case of Extrapulmonary Bilateral Testicular Tuberculosis

Mahmood A¹, Dr Abdul Hakeem Attar²

Department: Department Of Surgery & Pathology

Institute: Khaja Bandanawaz Institute Of Medical Sciences & Esicmc Gulbarga.

Abstract : *A 60 year old male presented with features of early septicemia. He was admitted in medical intensive care unit, routine surgical opinion taken for scrotal swelling. Ultrasonography of scrotum showed bilateral hydrocoel with bilateral? Testicular abscess. With broad spectrum antibiotics he recovered from septicemia, routine surgery done for bilateral hydrocoel, testicular abscess drained biopsy taken which showed tuberculous orchitis. Patient was started on ATT and he clinically improved.*

Key words: Extrapulmonary, Tuberculosis, Bilateral, Orchitis

Introduction : Most people think of tuberculosis as affecting only lungs, but in reality it affects every part of the body. Pulmonary tuberculosis is common type, accounting for 70% of cases. Sometimes, pulmonary TB will spread through this usually happens only in immune suppress patients and young children's. Genitourinary tuberculosis (GUTB) is the second most common form of extra pulmonary tuberculosis after lymph node involvement [1]. It is estimated that GUTB comprises 30% of non pulmonary TB [2]. In approximately 28% of patients with GUTB, the involvement is solely genital [3]. This report aims

to present a case of isolated tuberculous epididymo-orchitis with no other tuberculous foci elsewhere in the body.

Case report

A 60 year old male patient presented with complaint of scrotal swelling since 8-10 years, pain in scrotum since 5-6 month. He gives history of fever of moderate degree, nausea, vomiting since 4-5 days. He was admitted in MICU with provisional diagnosis of early septicemia. Surgical reference was taken for scrotal swelling. Local examination revealed bilateral scrotal swelling which had all the features of hydrocoel, routine

Hematological parameter was showing features of acute inflammation with WBC count 25,400.

RADIOLOGICAL FINDINGS:

USG of abdomen showed minimal ascites with hepatomegaly with pericholecystic edema. Scrotal USG showed bilateral hydrocoel with hypoechoic areas in testis suggestive of? Testicular abscess. X-ray chest showed left basal pneumonitis.

Patient diagnosed to be having early septicemia, treated with broad spectrum antibiotics, he recovered. After stabilizing the patient he was posted for surgery, peroperatively size of both testis was larger than normal on both testis incision taken and around 15-20 ml frank pus removed testicular biopsy taken, routine Jaboulay's repair done for hydrocoel.

GROSS/HISTOPATHOLOGICAL

FINDINGS:

Biopsy showed many well defined granulomas comprised of aggregated epitheloid cells, lymphocytes and fibroblasts with central caseous necrosis. Large area of fibrosis is evedent

with diffuse mixed inflammatory cell infiltration by neutrophils, plasma cells, and lymphocytes suggestive of tuberculous orchitis. Post operative recovery uneventful, started on ATT responded well.

Discussion: GUTB is still a major health problem in many developing countries including India. In India, the incidence of genital TB is nearly about 18% [4]. . Our patient was a 60-year-old male. Tuberculous foci in the epididymis are caused by metastatic spread of organisms through the bloodstream. . Testicular involvement usually is the result of direct extension from the epididymis, and scrotal involvement suggests local extratesticular extension of the disease process [4]. Bilateral epididymal involvement and concomitant testicular lesion strongly suggest tubercular etiology, especially in patients with tubercular foci elsewhere in the body and failure to respond to conventional antibiotic therapy [4]. Male genital tuberculosis usually is associated with renal tuberculosis in 60% to 65% of cases or with pulmonary tuberculosis in approximately 34% of cases [5]. However, the diagnosis of

extrapulmonary tuberculosis is challenging for a number of reasons: the lack of adequate sample amounts or volumes; the apportioning of the sample for various diagnostic tests (histology/cytology, biochemical analysis, microbiology, and PCR), resulting in non uniform distribution of microorganisms; the paucibacillary nature of the specimens; and the presence of inhibitors that undermine the performance of nucleic acid amplification-based techniques [6]. In diagnosing extrapulmonary tuberculosis, it is necessary to perform comprehensive evaluations, including histology, cytology and microbiological investigations (culture and PCR) and further clinical follow-up. A strong clinical suspicion of tuberculous etiology is required for diagnosis of extrapulmonary TB.

Conclusion:

Tuberculous epididymo-orchitis must be considered in differential diagnosis of scrotal swelling apart from testicular tumor, acute infection, and inflammatory orchitis. All attempts must be made for early diagnosis and treatment of

this condition to avoid unnecessary surgery and effect on motility.

ACKNOWLEDGEMENT: The work was indeed a mammoth task to accomplish and would not have been possible without active co-operation, constant strategic support and encouragement by our beloved – PRESIDENT- (Khaja Bandanawaz Institute of Medical Sciences)—DR.SYED SHAH KHUSRO HUSSAINI.

Reference

1. Kapoor R, Ansari MS, Mandhani A, Gulia A (2008) Clinical presentation and diagnostic approach in cases of genitor urinary tuberculosis. *Indian J Urol* 24: 401-405.
2. Wise GJ and Marella VK (2003). Genitourinary manifestations of tuberculosis *Urol Clin N Am* 30: 111–121.
3. Shah H, Shah K, Dixit R, Shah KV (2004) Isolated Tuberculous epididymo-orchitis. *Indian J Tuberc* 51: 159-162.
4. Das P, Ahuja A, Datta Gupta S (2008) Incidence, etiopathogenesis and pathological aspects of genitourinary tuberculosis in India: A journey revisited. *Indian J Urol* 24: 356-361.
5. Figueiredo AA, Lucon AM, Gomes CM, Srougi M (2008) Urogenital Tuberculosis: Patient classification in seven different groups according to clinical and radiological presentation. *International Braz J Urol* 34: 422-432.
6. Cek M, Lenk S, Naber KG, Bishop MC, Bjerklund Johansen TE, Botto H, Grabe M, Lobel B, Redorta JP, Tenke P; Members of the Urinary

Tract Infection (UTI) Working Group of the European Association of Urology (EAU) Guidelines Office (2005) EAU Guidelines for the

Management of Genitourinary Tuberculosis. European Urology 48: 353-362.

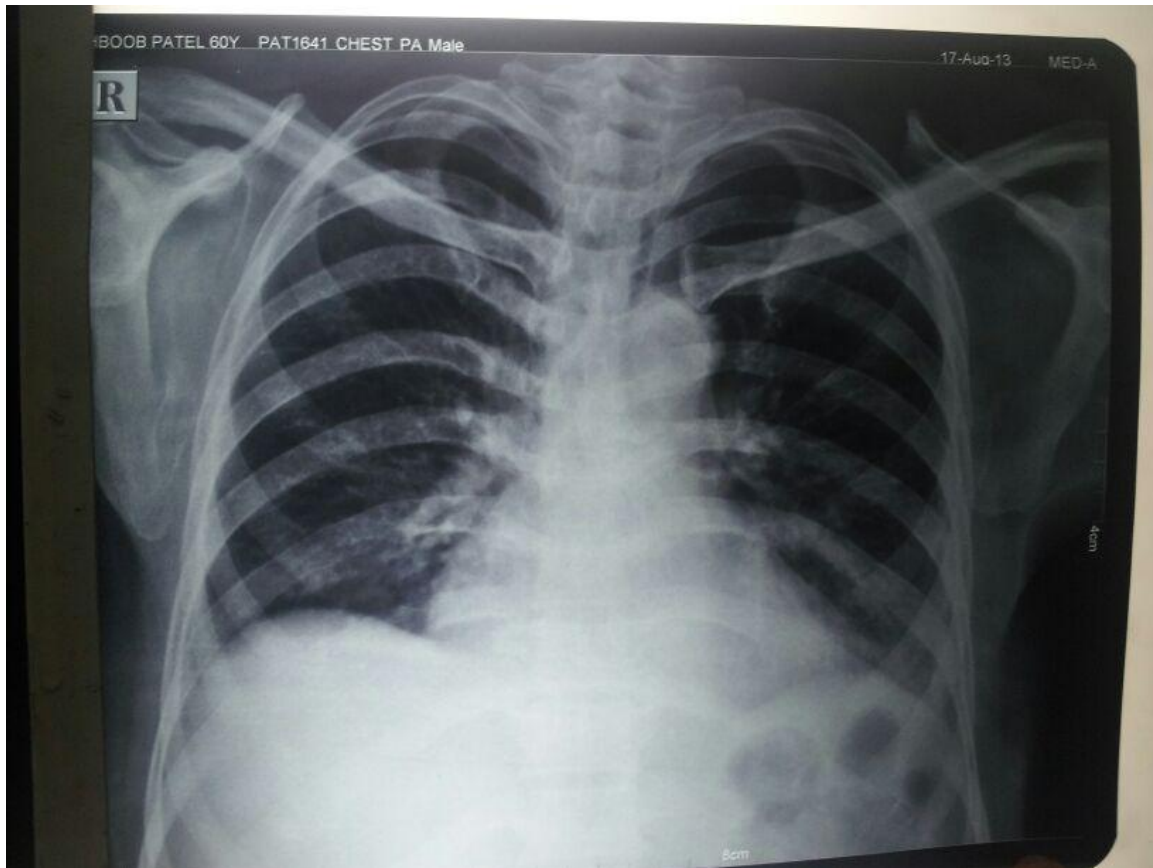


Fig.1. Photograph of X-ray chest PA view showed left basal pneumonitis. No evidence of tuberculous foci.

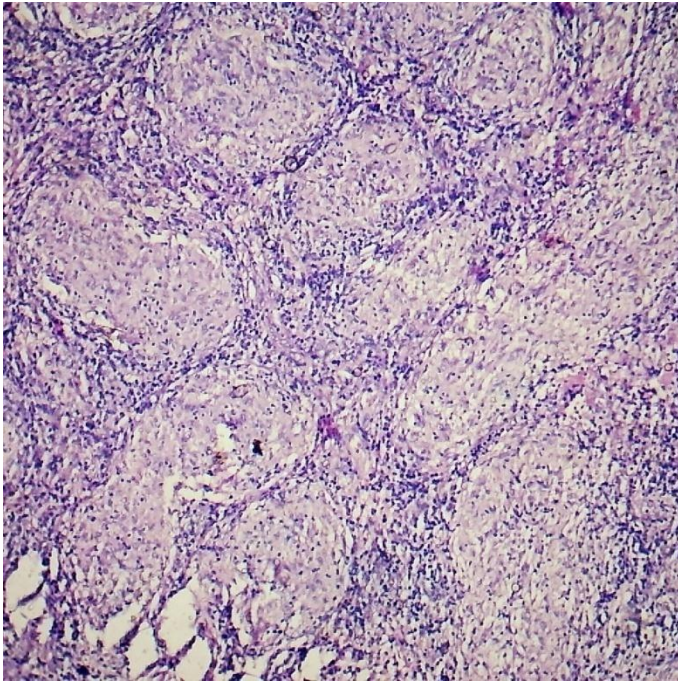


Fig.2. Photomicrograph showing many well defined granulomas. (H&E, 100X)

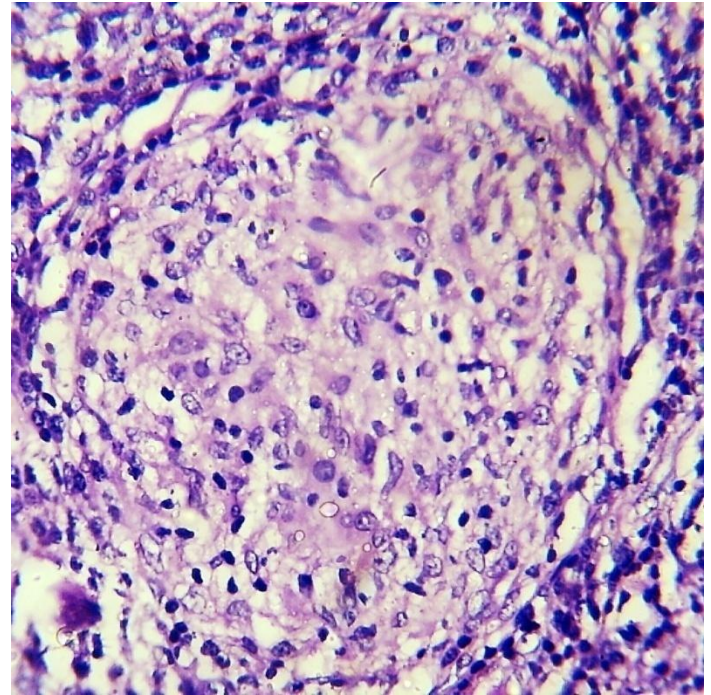


Fig.3 . Photomicrograph of granuloma showing aggregated epitheloid cells, lymphocytes and fibroblasts with central caseous necrosis. (H&E, 400X)