
Research Article

Mucocutaneous Manifestations among Vitamin B12 Deficiency Patients Attending A Tertiary Care Hospital

Dr.BheemaSena Chari M¹, Dr.Mohan Rao K²

^{1,2} Associate Professor, Department of General Medicine, Government Medical College, Ananthapuram, Andhra Pradesh.

Abstract: Vitamin B12 deficiency widespread in developing countries especially in Africa, India and South and Central America, more common in elderly people. Skin manifestations correlation with vitamin B12 deficiency is poorly considered by physicians, as cobalamin deficiency is not alone presenting with dermatologic manifestations. Here in this study we have tried to show the various types of mucocutaneous manifestations among vitamin B12 deficiency patients and its significance. Systemic examination was done and Mucocutaneous findings were noted among 116 selected population of both sexes, aged >10 years presenting with vitamin B12 symptoms. Serum levels of vitamin B12 were determined using chemiluminescence immunoassays (CLIA) from Elecsys/Roche Diagnostics, Mannheim, Germany. Majority of the cases presented with hyperpigmentation changes (53.4%), hair changes(47.4%) followed by angular cheilitis (37.9%), angular stomatitis (35.3%), nail changes (32.7%), cracks on skin (32.7%), atrophic glossitis (31.8%), vitiligo (31%), slatey pigmentation on face (27.5%). It was observed that as vitamin B12 levels in serum decreases, patients with mucocutaneous manifestations were increased. It was statistically significant (p<0.05). An expertise physician cautious look into manifestations and its correlation with laboratory investigations helps us to take clinical condition in a better way by proper diagnosis and accurate treatment.

Key words: Mucocutaneous manifestations, Vitamin B12 deficiency.

I. INTRODUCTION

Vitamin B 12 deficiency well known as Cobalamin deficiency, a medical condition of low levels of vitamin B 12 in blood[1], which is a common cause of megaloblastic anemia and pancytopenia.

Vitamin B12 plays an important role in normal functioning of brain, nervous system and the formation of red blood cells, especially involving DNA synthesis[2].Current Dietary Reference intakes of vitamin B12 are for women and men ages 14 and up RDA (Recommended dietary allowance) is 2.4µg/day, for pregnancy it is 2.6µg/day[3].

Vitamin B12 deficiency widespread in developing countries especially in Africa, India and South and Central America, more common in elderly people[4]. Vitamin B12 deficiency may result due to various causes such as poor dietary intake of vitamin B12 rich foods (Meat, poultry, eggs, dairy products)[5], various reasons related to impaired absorption of vitamin B12 including atrophic gastritis, pernicious anemia (intrinsic factor deficiency), resection of intestines or stomach for any problem, crohn's disease, celiac disease, over usage of proton pump inhibitors, histamine 2 receptor antagonists[6,7], chronic alcoholism. Infection with *Diphyllobothrium latum* which is commonly known as fish tapeworm also causes pernicious anemia.

Vitamin B12 deficiency is associated with hematologic, neurologic, psychiatric, gastrointestinal, dermatologic, and

cardiovascular manifestations. Various dermatologic manifestations are skin hyper pigmentation, vitiligo, angular stomatitis, nail and hair changes etc.,

Skin manifestations correlation with vitamin B12 deficiency is poorly considered by physicians, as cobalamin deficiency is not alone presenting with dermatologic manifestations. Here in this study we have tried to show the various types of mucocutaneous manifestations among vitamin B12 deficiency patients and its significance.

II. MATERIALS AND METHODS

An Prospective, observational cross sectional study was carried out for one year (Mar 2015 to Feb 2016) among patients attending General Medicine OPD at Government General Hospital/ Medical College, Ananthapuram at Andhra Pradesh. Informed consent has taken from selected population and ethical committee approved it before conducting this study.

A total of 116 subjects of both sexes aged >10 years were selected for this study. Study subjects presenting with complaints more towards vitamin B12 deficiency and those with investigations confirmed vitamin B12 deficiency were selected.

Patients details pertaining to presenting complaints, age, sex, socioeconomic status, dietary habits, marital history, physical

activity, personal habits like smoking, alcohol consumption, relevant past history were collected and advised for blood investigations including hemogram, peripheral blood smear, serum vitamin B12 assay. Systemic examination was done and Mucocutaneous findings were noted.

For estimation of vitamin B12, fasting blood samples were collected in a plain tubes without anticoagulant and sent for analysis. Serum samples were immediately processed within one hour, if there is any delay in processing samples were stored at -80°C.

Serum levels of vitamin B12 were determined using chemiluminescence immunoassays (CLIA) from Elecsys/Roche Diagnostics, Mannheim, Germany. Serum Vitamin B12 values >400pg/mL were considered as normal, 180pg/mL to 400 pg/mL were borderline.

All the data were entered into pre structured proforma and was analyzed with statistical analysis using numbers, percentages and p value calculated using graph pad software. The p value <0.05 was considered as cutoff value or significant statistically.

III. RESULTS

Out of 116 study subjects, 95 were confirmed vitamin B12 deficiency with serum levels below 180pg/mL and remaining 21 had borderline vitamin B12 serum values between 180pg/mL to 400pg/mL. 84 out of 116 were females and remaining 32 were males. Female preponderance was observed. Most of the vitamin B12 deficiency patients were in the age group of 31-50 years, 82 out of 116 patients (Table.1).

Table.1 Age and Sex distribution among Vitamin B12 deficiency patients

Age in years	Male	Percentage	Female	Percentage	Total	Percentage
10-20 years	2	1.7%	4	3.4%	6	5.1%
21-30 years	4	3.4%	12	10.3%	16	13.7%
31-40 years	12	10.3 %	32	27.5%	44	37.9%
41-50 years	12	10.3 %	26	22.4%	38	32.7%
>50 years	2	1.7%	10	8.6%	12	10.3%
Total	32	27.5 %	84	72.4%	116	100%

Socioeconomic status of study subjects were analyzed by modified kuppuswamy's classification. Out of 116 selected

population majority were lower middle class, was 43 (37%) followed by 41 (35.3%) patients of upper lower class, 15 (12.9%) were upper middle class, 12 (10.3%) lower class and 5 upper class patients. More of the Non vegetarians were presented with cobalamin deficiency when compared to vegetarians (Fig .1).

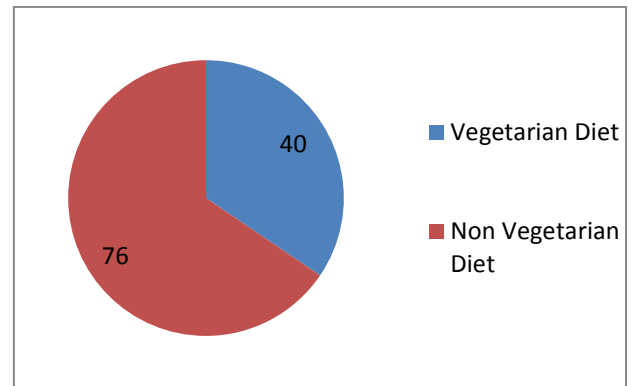


Fig.1 Dietary habits among vitamin B12 deficiency patients

Vitamin B12 deficiency patients were presented with various mucocutaneous manifestations such as hyper pigmentation changes, angular cheilitis, angular stomatitis, atrophic glossitis, vitiligo, hair changes, nail changes, cracks on skin, slatey grey pigmentation over face (Table.2). Majority of the cases presented with hyper pigmentation changes (53.4%)(Fig.2), hair changes(47.4%).

Table.2 Various types of Mucocutaneous manifestations

Mucocutaneous manifestations	No. of Patients	Percentage
Hyper pigmentation	62	53.4%
Angular cheilitis	44	37.9%
Angular stomatitis	41	35.3%
Atrophic glossitis	37	31.8%
Vitiligo	36	31.0%
Hair changes	55	47.4%
Nail changes	38	32.7%
Cracks on skin	38	32.7%
Grey pigmentation on face	32	27.5%

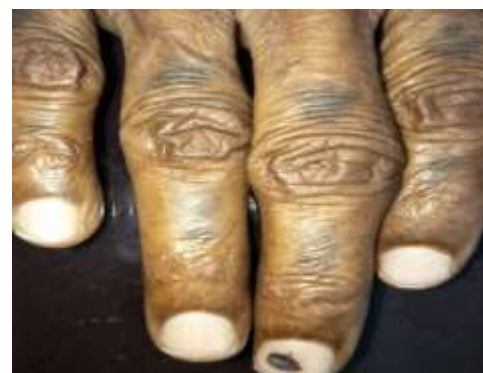

Fig.2 Hyperpigmentation over phalangeal regions and nails.

Mucocutaneous manifestations when related to serum vitamin B12 levels. It was observed that as vitamin B12 levels in serum decreases, patients with mucocutaneous manifestations were increased (Table.3). It was statistically significant ($p<0.05$).

Table.3 Mucocutaneous manifestations in relation to severity of vitamin B12 deficiency

Serum Vitamin B12 levels	No. of cases
180-400 pg/mL	21
100-179 pg/mL	66
<100 pg/mL	87

IV DISCUSSION

Vitamin B₁₂ deficiency can potentially cause severe and irreversible damage, especially to the brain and nervous system. Vitamin B₁₂ deficiency is most commonly caused by low intakes, but can also result from malabsorption, certain intestinal disorders, low presence of binding proteins, and use of certain medications. Vitamin B12 is available in various animal products (shellfish, meat, eggs), fortified food products and dietary supplements [8,9].

Out of 116 study subjects, 95 were confirmed vitamin B12 deficiency with serum levels below 180pg/mL and remaining 21 had borderline vitamin B12 serum values between 180pg/mL to 400pg/mL. 84 out of 116 were females and remaining 32 were males. Most of the vitamin B12 deficiency patients were in the age group of 31-50 years, 82 out of 116 patients as per this study. In similar to our study Richa Arora et al [10] observed that mucocutaneous manifestations most commonly noted in the age group of 31-40 years followed by 41-50 years and female preponderance (83.3%) was noted.

Majority of the cases presented with hyperpigmentation changes (53.4%), hair changes(47.4%) followed by angular chelitis (37.9%), angular stomatitis (35.3%), nail changes (32.7%), cracks on skin (32.7%), atrophic glossitis (31.8%) (Fig.3), vitiligo (31%), slatey pigmentation on face (27.5%) (Fig.4) in this study.

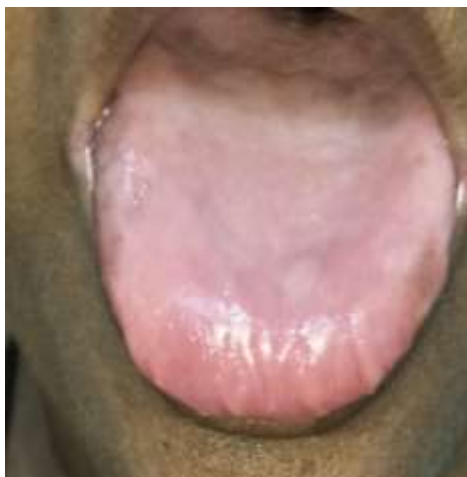

Fig.3 Showing Bald tongue representing atrophic glossitis

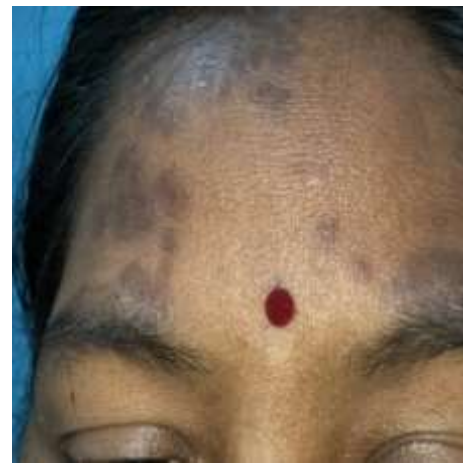

Fig.4 Slatey pigmentation over forehead

Hyperpigmentation pattern is generalized with accentuation in palms, soles, flexural areas, on phalanges, knuckles, knees, elbows. This manifestation may be the first one that appears in vitamin B12 deficiency [11]. Hyperpigmentation appears in regions where there is increase in cell turnover of tissue. Hair changes presented as brittle, luster less, early graying of hair [12]. Nail changes like longitudinal brown or black streaks appear on nail plates. Aaron *et al* [13] reported that 12 out of 63 (19%) patients had glossitis (31%), which was the most common mucocutaneous manifestation, followed by skin hyper pigmentation (19%), hair changes (9%), angular stomatitis (8%), and vitiligo (3%).

It was observed that as vitamin B12 levels in serum decreases, patients with mucocutaneous manifestations were increased. It was statistically significant ($p<0.05$). A patient presenting with these mucocutaneous manifestations should alert as vitamin B12 deficiency may be one of the cause. In a patient presenting with multisystem involvement, the mucocutaneous lesions can be the clue for the early diagnosis of vitamin B12 deficiency[14]. Unexplained and non resolving skin lesions can be a red flag for vitamin B12 deficiency [15]. Rajendra Kanna et al [16] documented that cutaneous lesions not responding to conventional therapy could be an indication of vitamin B12 deficiency.

Vitamin B12 causes decrease in intracellular reduction potential that leads to oxidation of the reduced glutathione and decrease in GSH/GSSG ratio, involved in synthesis of glutathione an antioxidant that prevents abnormal activities of the enzyme tyrosinase, which stimulates melanin production[17]. Depletion of glutathione because of vitamin B12 deficiency increases tyrosinase activity, which cause abnormal increase in melanin production.

V CONCLUSION

As skin manifestations are not specific to cobalamin deficiency alone, there are chances of misdiagnosing, inappropriate treatment which may result in poor outcome. Whereas, another side overlooked towards skin manifestations relating to cobalamin deficiency and treating it as vitamin B12 deficiency leads to wrong diagnosis and treatment, which may again turn to poor clinical improvement. An expertise

physician cautious look into manifestations and its correlation with laboratory investigations helps us to take clinical condition in a better way by proper diagnosis and accurate treatment.

VI REFERENCES

- 1.Herrmann, Wolfgang 2011. Vitamins in the prevention of human diseases. Berlin: Walter de Gruyter. p. 245.
- 2.Amada, Kazuhiro. 2013. "Chapter 9. Cobalt: Its Role in Health and Disease". In Astrid Sigel, Helmut Sigel and Roland K. O. Sigel. *Interrelations between Essential Metal Ions and Human Diseases. Metal Ions in Life Sciences*. 13. Springer. pp. 295–320. doi:10.1007/978-94-007-7500-8_9.
- 3.Institute of Medicine. 1998. "Vitamin B12". Dietary Reference Intakes for Thiamin, Riboflavin, Niacin, Vitamin B6, Folate, Vitamin B12, Pantothenic Acid, Biotin, and Choline. Washington, DC: The National Academies Press. pp. 340–342. ISBN 0-309-06554-2. Retrieved 2012-02-07.
- 4.Baik HW, Russell. RM 1999. "Vitamin B12 deficiency in the elderly". Annual Review of Nutrition. 19: 357–77.
- 5.McBride, Judy. August 2000. "B12 Deficiency May Be More Widespread Than Thought". Agricultural Research Service. United States Department of Agriculture. Retrieved 2 July 2012.
- 6.Lam JR, Schneider JL, Zhao W, Corley DA. Dec 2013. "Proton pump inhibitor and histamine 2 receptor antagonist use and vitamin B12 deficiency". JAMA. 310 (22): 2435–2442. doi:10.1001/jama.2013.280490, PMID 24327038.
- 7.Yeomans ND, Hanson RG, Smallwood RA, Mihaly GW, Louis WJ. 1982. "Effect of chronic ranitidine treatment on secretion of intrinsic factor". Br Med J (Clin Res Ed). 285 (6337): 264.
- 8."Vitamin B₁₂". Micronutrient Information Center, Linus Pauling Institute, Oregon State University, Corvallis, OR. 2014. Retrieved 16 February 2017.
- 9."Foods highest in Vitamin B₁₂ (based on levels per 100-gram serving)". Nutrition Data, Conde Nast, USDA National Nutrient Database, release SR-21. 2014. Retrieved 16 February 2017.
- 10.Richa Arora, Avinash Dalal. 2016 Mar. Cutaneous manifestations of vitamin B12 deficiency. IJRSET. 5(3), 3780-3786.
- 11.Srivastava N, Chand S, Bansal M, Srivastava K, Singh S. 2006. Reversible hyperpigmentation as the first manifestation of dietary vitamin B12 deficiency. Indian J DermatolVenereolLeprol. 72:389–90.
- 12.Niiyama S, Mukai H. 2007. Reversible cutaneous hyperpigmentation and nails with white hair due to vitamin B12 deficiency. Eur J Dermatol. 17(6):551–2.
- 13.Aaron S, Kumar S, Vijayan J, Jacob J, Alexzander M, Gnanamuthu C. 2005. Clinical and laboratory features and response to treatment in patients presenting with vitamin B12 deficiency-related neurological syndromes. Neurol India. 53:55–8.
- 14.Oh R, Brown DL. 2003. Vitamin B12 deficiency. Am Fam Physician. 67(5):979–86.
- 15.Baker SJ, Ignatius M, Johnson S, Vaish SK. 1963. Hyperpigmentation of skin. A sign of vitamin-B12 deficiency. Br Med J. 1(5347):1713–5.
- 16.Rajendran Kannan, Matthew Joo. 2008 Apr. Cutaneous lesions and vitamin B12 deficiency. Can Fam Physician. 54(4): 529–532.
17. Gilliam JN, Cox AJ. 1973. Epidermal changes in vitamin B12 deficiency. Arch Dermatol. 107:231–6.