
Research Article

Chest X ray Imaging Patterns of Infectious Pneumonia among Immunocompetent Patients

Dr.Bakka Sarada¹, Dr.Nagireddy Vasundhara²

¹Assistant Professor, Department of Radiology, Government Medical College & General Hospital, Ananthapuram, Andhra Pradesh.

²Assistant Professor, Department of Radiology, Government Medical College & General Hospital, Ananthapuram, Andhra Pradesh.

Corresponding Author: Dr.Nagireddy Vasundhara,

Abstract: Infectious Pneumonia is a worldwide public health problem. It is a single largest infectious cause of death in children worldwide. Chest X ray is a non invasive, economical medical test that helps physicians to diagnose and treat medical conditions including infectious pneumonia. The aim of this study is to know the prevalence of infectious pneumonia among immunocompetent individuals and the various patterns of pneumonia on chest X-ray. Patients attending General Medicine OPD with persisting symptoms of pneumonia were selected to do this study. Chest x-ray taken and findings were correlated with clinical features, blood and sputum investigations for accurate diagnosis. Cough and fever were the most common presenting features seen in 86.4% and 70.2% of the patients respectively. Lobar consolidation was predominant pattern seen in 46 (62.1%) patients, followed by diffuse consolidation among 10 (13.5%) patients. Out of 74 patients 47 (63.1%) were confirmed by bacterial culture. Sputum samples reported with Streptococcus pneumoniae, Klebsiella pneumoniae, Tuberculosis were identified mostly from lobar pneumonia cases. Staphylococcus aureus, Klebsiella pneumoniae, Pseudomonas, Enterobacter, Acinetobacter were isolated from bronchopneumonia cases. Diagnosing of Infectious pneumonia by various imaging patterns of chest x ray needs expertise. Studying Chest x-ray imaging patterns and their correlation with microbiological investigations helps us to diagnose accurately and start appropriate treatment.

Key Words: Chest X-ray, Imaging patterns, Infectious Pneumonia.

I INTRODUCTION

Pneumonia is an inflammatory condition of the lung which primarily affects alveoli to fill up with fluid or pus [1]. It can affect one or both the lungs, commonly known as Walking Pneumonia. Pneumonia is caused by variety conditions such as infections, autoimmune diseases etc., [2].

Infectious pneumonia usually caused by bacteria or viruses and less commonly by other microorganisms. Any age group persons can be affected by infectious pneumonia but the children <2 years and older age people >65 years have the highest odds, this is because their immune system is not fit enough to fight against it. Predisposing factors include lung diseases like COPD, asthma, cystic fibrosis, immunosuppressive conditions like diabetes, cancer, HIV, over usage of steroids and other conditions such as heart failure, stroke etc [3].

Infectious Pneumonia is a worldwide public health problem. It can be community acquired pneumonia (CAP) or health care associated pneumonia (HCAP). Most commonly referenced guidelines for pneumonia is Infectious Disease Society of America (IDSA) and American Thoracic Society (ATS)

guidelines. It is a single largest infectious cause of death in children worldwide [4]. Approximately 450 million people (7% of the population) affected by pneumonia and results in about 4 million deaths per year worldwide [5,6].

Diagnosis of Infectious pneumonia is not much difficult now a days because of rapid invention of newer technologies for identification of microorganisms. Chest X-ray, sputum culture, blood tests aid to confirm the diagnosis.

Radio diagnosis plays a vital role to arrive at accurate diagnosis at the earliest and also helps to rule out other diseases. Pneumonia is typically diagnosed upon a combination of physical signs and chest X-ray [7]. Chest X ray is a non invasive, economical medical test that helps physicians to diagnose and treat medical conditions. Most commonly performed test, as it is cheap, fast and easy, moreover helps to diagnose.

The aim of this study is to know the prevalence of infectious pneumonia among immunocompetent individuals and the various patterns of pneumonia on chest X-ray.

II MATERIALS AND METHODS

A Prospective observational study was done for year from February 2016 to January 2017 among pneumonia patients at Radiology Department, Government general hospital, Ananthapuram. Patients attending General Medicine OPD with persisting symptoms of pneumonia were selected to do this study. Informed consent has taken from selected population and institutional ethical committee has approved this study. 74 immunocompetent patients of both sexes suspected infectious pneumonia were considered based on the following criteria.

Inclusion Criteria:

- 1.Both sexes (males and females)
- 2.Persisting symptoms of pneumonia
- 3.No improvement with treatment
- 4.Uncertain cause

Exclusion criteria:

- 1.Immunosuppressive patients
- 2.Diabetic patients
- 3.Patients on steroids

Patients details pertaining to symptoms, clinical signs were noted and systemic examination done. On local examination of chest features suggestive of pneumonia were noted.

Patients were explained about their condition and advised to undergo blood tests, sputum culture and chest X-ray. At radiology department, procedure was explained to patients and chest x-ray on posteroanterior and lateral views were taken. Digital image files were stored electronically to interpret and analyze the pattern. Chest x-ray findings were correlated with clinical features, blood and sputum investigations for accurate diagnosis.

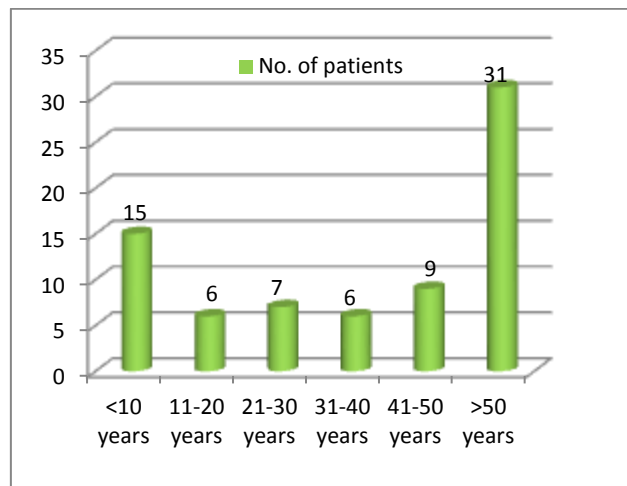
All the results related to infectious pneumonia were entered into excel sheet and analyzed using statistical methods includes numbers, percentages, histogram.

III RESULTS

A total of 74 suspected purely suggestive of infectious pneumonia immunocompetent patients based on clinical symptoms and signs were considered to do this study. Among 74 patients 46 (62.1%) were males, remaining 28(37.8%) were females. Out of 74 patients most of them were in the age group of >50 years followed by <10 years age group(Fig No.1).

Out of 74 patients, pneumonia was observed in 15 (20.2%) members in the age group of <10 years, 6 (8.1%) were in the age group of 11-20 years and 31-40 years each, 7 (9.4%) were in the age group of 21-30 years, 9 (12.1%) were 41-50 years and 31 (41.8%) were >50 years.

Fig No.1 Age wise distribution of patients with infectious pneumonia



Cough and fever were the most common presenting features seen in 86.4% and 70.2% of the patients respectively. Other symptoms noted were Expectoration(62.1%), chest pain (47.2%), breathlessness (58.1%) (Table No.1).

Table No.1 Various clinical features noted in pneumonic patients

Clinical features	Number of Patients (n=74)	Percentage
Fever	52	70.2%
Cough	64	86.4%
Expectoration	46	62.1%
Chest Pain	35	47.2%
Breathlessness	43	58.1%
Hemoptysis	18	24.3%
Gastrointestinal symptoms	25	33.7%
Tachycardia	52	70.2%
Tachypnoea	55	74.3%
Changes in Blood pressure	21	28.3%
Others	24	32.4%

On assessment of chest x-ray of infectious pneumonia among immunocompetent patients, various patterns were observed. Consolidation was more often observed followed by Interstitial opacities and Nodule or Mass. Lobar consolidation was predominant pattern seen in 46 (62.1%) patients, followed by diffuse consolidation among 10 (13.5%) patients, Fine Nodular Opacities in 12.1% patients, 5.4% multifocal ill defined consolidations (Fig No.2 &3).

Table No.2 Chest x-ray imaging patterns among selected patients

Patterns	No. of Patients	Percentage (%)
Consolidation		
Lobar consolidation	46	62.1%
Diffuse consolidation	10	13.5%

Multifocal ill defined consolidations	4	5.4%
Interstitial		
Reticular interstitial opacities	2	2.7%
Fine nodular interstitial opacities	9	12.1%
Nodule or Mass		
Solitary pulmonary nodule	1	1.3%
Multiple masses	2	2.7%
Total	74	100%

Fig No.1 Showing Middle and Lower lobe consolidation in right lung

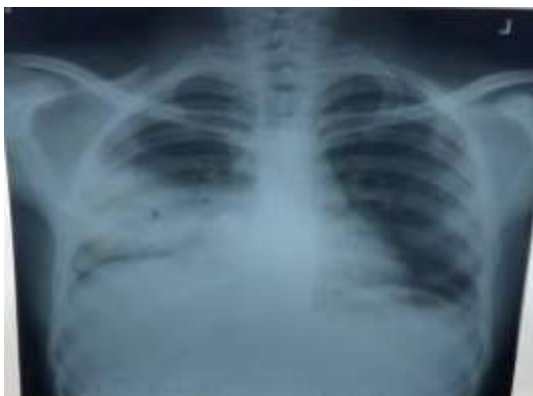
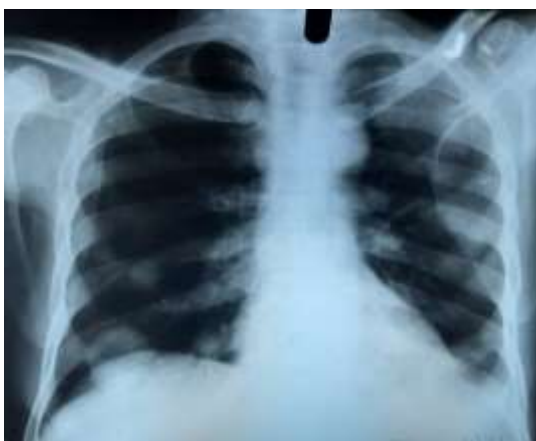
Fig No.2 Showing Pulmonary Nodule in right lung



Out of 74 patients 47 (63.1%) were confirmed by bacterial culture. Sputum samples reported with Streptococcus pneumoniae, Klebsiella pneumoniae, Tuberculosis were identified mostly from lobar pneumonia cases. Staphylococcus aureus, Klebsiella pneumoniae, Pseudomonas, Enterobacter, Acinetobacter were isolated from bronchopneumonia cases. Interstitial and few consolidation pneumonia patients which were culture negative diagnosed as atypical pneumonia like Mycoplasma, legionella, viral and fungal pneumonia based on

clinical findings and laboratory investigations.

9(12.1%) patients died out of 74 who were diagnosed with infectious pneumonia. Out of 9 died patients, 2 were < 10 years and remaining 7 were in the age group of >50 years.

IV DISCUSSION

Infectious pneumonia is an acute respiratory infection that affects the lungs. When an individual has pneumonia, the alveoli are filled with pus and fluid, which makes breathing painful and limits oxygen intake. Nevertheless, in developing countries, and among the very old, the very young, and the chronically ill, pneumonia remains a leading cause of death [8]. Chest X-ray is needed to those with potential complications, not improving with treatment, with uncertain cause, sick people [9,10]. In this study we have tried to highlight the importance of chest X-ray in the diagnosis of infectious pneumonia.

Infectious pneumonia has become major concern globally due to many problems. Vaccine is available for against few bacteria only such as streptococcus pneumoniae, hemophilus influenzae type b, yet to discover vaccines against many more viruses or bacteria to combat this problem permanently. Another problem is as the use of antibiotics became more widespread due to lack awareness about antibiotics in community, misuse of antibiotics. The prevalence of antibiotic resistant bacteria also increased. Antibiotic resistance is a major concern to treat infectious pneumonia cases. But with introduction of vaccines and antibiotics in the 20th century, survival rate improved [11].

Among 74 patients 46 (62.1%) were males, remaining 28(37.8%) were females. Out of 74 patients most of them were in the age group of >50 years followed by <10 years age group as per this study. Similar to this study Shaikh Mohammed aslam et al [12] and Xiao K et al [13] reported male predominance with 64% and 59.6% respectively. In the present study Cough and fever were the most common presenting features seen in 86.4% and 70.2% of the patients respectively. Torres et al [14] documented that 81% of the patients with cough and 76% patients with fever.

In this study consolidation was more often observed followed by Interstitial opacities. Lobar consolidation was predominant pattern seen in 46 (62.1%) patients, followed by diffuse consolidation among 10 (13.5%) patients, Fine Nodular Opacities in 12.1% patients, 5.4% multifocal ill defined consolidations. Many other studies mentioned that Lobar pneumonia is the most common radiological feature, Torres et al [14], Bin Abdullah B [15] reported 82% and 72% of lobar pneumonia. Rohini G Ghasi et al [16] documented that typical imaging features serve as "red flag signs" in reaching a diagnosis or altering the management.

Chest x-ray is a widely used very useful examination even though it has few limitations such as some diseases cannot be detected, cannot detect smaller lesions clearly for example small cancers. Chest x-ray uses a small radiation for diagnosis,

is a rapid effective, non invasive test that has been useful for decades to help doctors at arriving diagnosis.

V CONCLUSION

Infectious Pneumonia is a major health problem, leading cause of death globally especially in chronic ill patients. Lobar consolidation is the most common radiological feature observed which can be detected by chest x-ray. Diagnosing of Infectious pneumonia by various imaging patterns of chest x ray needs expertise. Studying Chest x-ray imaging patterns and their correlation with microbiological investigations helps us to diagnose accurately and start appropriate treatment.

VI REFERENCES

1. Leach, Richard E. 2009 *Acute and Critical Care Medicine at a Glance (2nd ed.)*. Wiley-Blackwell.

2. McLuckie, A. ed. 2009. Respiratory disease and its management. New York: Springer. p. 51.

3. "Who Is at Risk for Pneumonia?". NHLBI. March 1, 2011. Retrieved 3 March 2016.

4. <http://www.who.int/mediacentre/factsheets/fs331/en/>

5. Ruuskanen, O; Lahti, E; Jennings, LC; Murdoch, DR. 2011 Apr "Viral pneumonia". *Lancet*. 377 (9773):1264–75. doi:10.1016/S0140-6736(10)61459-6.

6. Lodha, R. Kabra, SK. Pandey, RM. 2013 June "Antibiotics for community-acquired pneumonia in children". *The Cochrane database of systematic reviews*. 6: CD004874.

7. Lynch, T; Bialy, L; Kellner, JD; Osmond, MH; Klassen, TP; Durec, T; Leicht, R; Johnson, DW. 2010 Aug Huicho, Luis, ed. "A systematic review on the diagnosis of pediatric bacterial pneumonia: when gold is bronze". PLoS ONE. 5 (8): e11989.

8. George, Ronald B. 2005 Chest medicine : essentials of pulmonary and critical care medicine (5th ed.). Philadelphia, PA: Lippincott Williams & Wilkins. p. 353.

9. Singh, V. Aneja, S. March 2011 "Pneumonia – management in the developing world". Paediatric respiratory reviews. 12 (1):52-9. doi:10.1016/j.prrv.2010.09.011.

10. Lim, WS. Baudouin, SV. George, RC. Hill, AT. Jamieson, C. Le Jeune, I. Macfarlane, JT. Read, RC. Roberts, HJ. Levy, ML. Wani, M. Woodhead, MA. 2009 Oct. Pneumonia Guidelines Committee of the BTS Standards of Care Committee. "BTS guidelines for the management of community acquired pneumonia in adults: update 2009". Thorax. 64 (Suppl 3): iii1–55. doi:10.1136/thx.2009.121434.

11. Ruuskanen, O. Lahti, E. Jennings, LC. Murdoch, DR. 2011 Apr "Viral pneumonia". *Lancet*. 377 (9773): 1264–75. doi:10.1016/S0140-6736(10)61459-6.

12. Shaikh Mohammed Aslam S, Bushra Abdul Aleem. 2015 Nov Study of clinical and etiological profile of community acquired pneumonia in elderly patients. 14(11):31-34. DOI:

10.9790/0853-141153134

13. Xiao K, Su LX, Han BC, Yan P, Yuan N, Deng J et al. 2013 Analysis of the severity and prognosis assessment of aged patients with community-acquired pneumonia: a retrospective study. *J Thorac Dis* 5(5):626-33.

14. Torres A, Dorca J, Zalacaín R, Bello S, El-Ebiary M, Molinos L et al. 1996 Nov Community-acquired pneumonia in chronic obstructive pulmonary disease: a Spanish multicenter study. *Am J Respir Crit Care Med*. 154(5):1456-61.

15. Bin Abdullah B, Zoheb M, Ashraf SM, Ali S, Nausheen N. 2012 A Study of Community-Acquired Pneumonias in Elderly Individuals in Bijapur. *ISRN Pulmonology*. Article ID 936790, 10 pages doi:10.5402/2012/936790.

16. Rohini, G Ghasi and Sunil, K Bajaj. 2017 Jan-Mar Infectious pneumonia in the immunocompetent host: What the radiologist should know. *Indian J Radiol Imaging*. 27(1):23–32.