

## Darier's Disease: A Series of Three Cases

Dr. Atul Jain<sup>1</sup>, Dr. Harsh kumar<sup>2</sup>, Dr.Chandanwale S.S.<sup>3</sup>, Dr.Panicker N.K.<sup>4</sup>

<sup>1</sup>Professor<sup>1</sup> Department of pathology, Dr. D.Y Patil Medical College and Hospital, Pimpri, Pune, India

<sup>2,3,4</sup> Professor<sup>1</sup> Department of pathology, Dr. D.Y Patil Medical College and Hospital, Pimpri, Pune, India

Email id: [jainkatul23@gmail.com](mailto:jainkatul23@gmail.com)

**ABSTRACT:** *Darier's disease (DD) or Keratosis follicularis is a rare cutaneous disease with an autosomal dominant mode of inheritance. It was first described by Darier and White in 1989. It manifests as hyperkeratotic papules, primarily affecting seborrheic areas on the head, neck, and thorax. Histologically, the lesions present as suprabasal clefts in the epidermis with acantholytic and dyskeratotic cells which are represented by corps ronds and grains. Oral retinoid is the treatment of choice for severe disease. Herein we present a series of three cases of Darier's disease with clinical and histopathological correlation.*

**KEY WORDS:** *Darier's disease, Keratosis follicularis.*

### INTRODUCTION:

Darier's disease (DD) or Darier-White disease, also known as keratosis follicularis, is an autosomal dominantly inherited genodermatosis. <sup>(1, 2)</sup> The disease was first reported independently by Darier and White in 1889. White was first to recognize the genetic nature of Darier disease by noticing that a mother and her daughter were affected. <sup>(3)</sup>

Darier's disease characterized by greasy, crusted, keratotic, yellow brown warty papules and plaques particularly over seborrheic areas. Although, this is a genetically transmitted disease, according to data

published in a large series, about 47% of patients had no clear family history of the disease, presumably because of incomplete gene penetrance. <sup>(4)</sup> The disease is caused by mutations in the ATP 2A gene, which encodes the sarcoendoplasmic reticulum Ca<sup>2+</sup> ATPase. <sup>(4)</sup> Recent studies have shown that the underlying defect is a result of mutations in the ATP2A2 gene on chromosome 12q23-243 that encodes for a sarco/endoplasmic reticulum calcium ATPase pump (SERCA 2) expressed on human skin and mucosa. <sup>(5, 6)</sup> The onset of disease is in childhood and adolescence. <sup>(7)</sup> The clinical features include

hyperkeratotic, waxy papules, skin coloured plaques or minute acanthomas on front of chest, retroauricular areas and central T zone of face. The affected nails are short and wide, with white and red longitudinal bands, V-shaped notch and scalloping of distal nail plate and subungual hyperkeratosis.<sup>(7)</sup>

The disease persists throughout life, runs a chronic relapsing course, without affecting the general health.<sup>(7)</sup> Exacerbations have been reported by heat, sunlight, ultra violet rays, lithium, oral corticosteroids,<sup>(7)</sup> mechanical trauma and menstruation.<sup>(8)</sup>

Histology shows Hyperkeratosis, <sup>(7, 8)</sup> suprabasal acantholysis and clefts, corps ronds and corps grains., The underlying dermal papillae, are covered by a single layer of epithelium (stratum basale). These papille project into the clefts and form villus like structures. A large keratin plug, often showing focal parakeratosis, overlies each lesion. <sup>(7, 8)</sup> Herein, we present a series of three cases of Darier's disease with clinical and histopathological correlation.

Case no1-A 51 year old male, presented with multiple itchy, blackish, raised lesions over back, scalp of 4-5 years duration. H/o exacerbation of symptoms on exposure to heat and sweating was also recorded. On examination there were yellowish brown crusted

greasy papules over the nape of neck, back and scalp. hyperpigmentation of oral mucosa was seen. The pathognomonic nail triad of alternating red and white streaks was also detected thereby giving a clinical impression of Darier's disease

Case no 2-A 59 year old female presented with itchy, red plaques over back and neck of 6 month duration. Patient also had nail fragility. H/o exacerbation of symptoms on exposure to heat and sweating was present. On examination the lesions were reddish brown scaly with areas of cracking and weeping. The clinical diagnosis was eczema

Case no 3-A 42 year old female presented with brownish scaly areas over scalp, behind the ears and middle of the chest of 2 years duration. On examination the lesions were greasy, brownish papules, along with longitudinal red and white line on the nail pad the case was clinically interpreted as case of seborrheic dermatitis.

Routine haematological and biochemical investigation were normal in all the three cases. A punch biopsy of skin lesions was performed in all the patients and the tissue subjected for histopathological examination.

## HISTOPATHOLOGY

Case 1-epidermis showed acanthosis and hyperkeratosis, suprabasal acantholysis with suprabasal clefts and lacunae, dyskeratosis with formation of papillae in the clefts. These clefts are lined by a single layer of basal cells. The dermis showed infiltration by chronic inflammatory cells, predominantly lymphocytes.

Case2, case3-acantholysis and mild hyperkeratosis along with suprabasal clefting was observed in both cases. A careful examination further revealed focal areas of epidermis showing acantholysis along with mononuclear inflammatory cells around blood vessels

All three cases were diagnosed as Darier's disease. (Fig 1, Fig 2, Fig 3, Fig 4.)

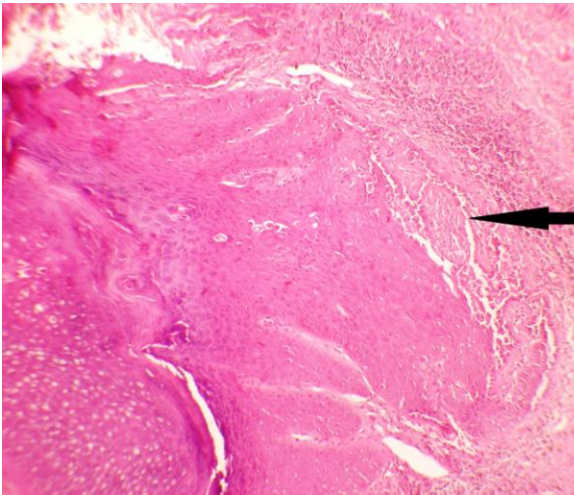


Fig-1 Microphotograph Low Power View Showing Hyperkeratosis, There Is A Supra Basal Cleft (arrow) With Papilla Formation And Dyskeratotic Acantholytic Cell. (H&E Stain X100).

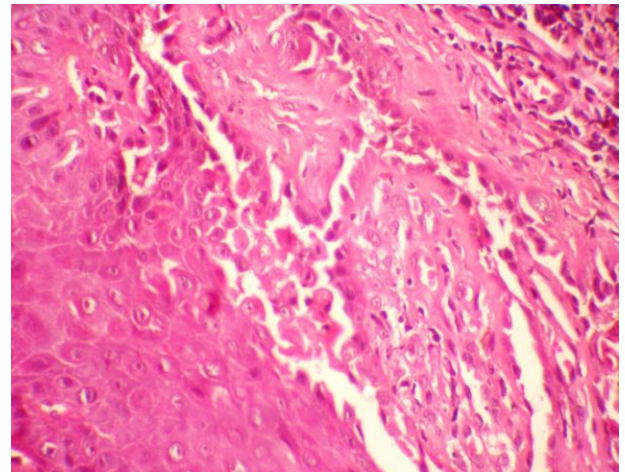


Fig-2 Microphotograph High Power View Showing Cleft With Papilla Formation with Acantholytic Cells (H&E Stain X 200)

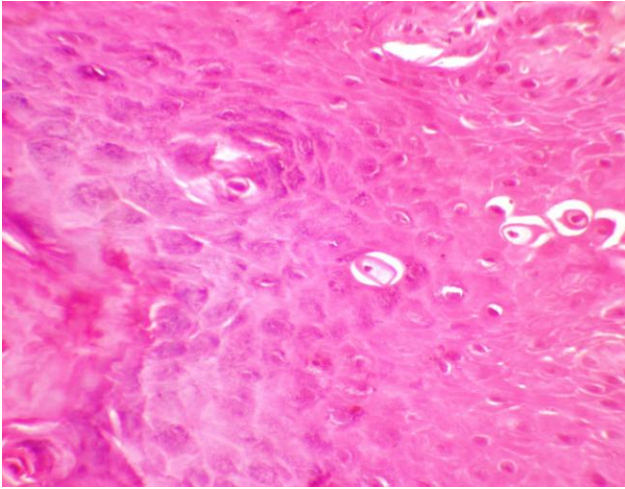


Fig-3 Microphotograph High Power Showing Corps Ronds In The Granular Layer (H&E Stain X 400)

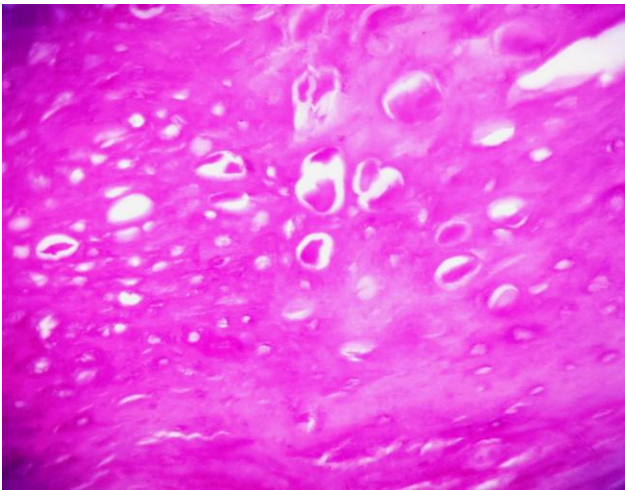


Fig-4 Microphotograph High Power View Showing, Grains In the Horny Layer (H&E Stain X 400)

## DISCUSSION

Darier's disease is an uncommon dominantly inherited skin disorder. It has a world-wide distribution, with the prevalence estimated to vary

from 1 in 36,000 to 1 in 1, 00,000. <sup>(9, 10)</sup> The incidence of new cases is four per million per 10 years. <sup>(11)</sup> Cases present as keratotic papules, erythematic papules and dyschromic papules mainly on the back. Darier's disease is an autosomal dominant disease with high penetrance and variable expressivity. Although it is an inherited disease, 47% of the patients with Darier's disease may not have a family history.

<sup>(12)</sup> Darier's disease most commonly manifests in the age group of 6 to 20 years; however, patients have presented as early as age 4 years and as late as age 70 years.<sup>(13)</sup> in our case series age of patients are 42,51,59 years respectively. Statistically both sexes are equally affected. <sup>(8)</sup> In our case series the M: F ratio is 1:2. This is probably due to small number of cases being considered. Ultrastructural studies have revealed the breakdown of desmosome-keratin filament complexes between keratinocytes, and a loss of cohesion between suprabasal epidermal cells. There may be a structural abnormality in a component of the desmosomes.<sup>(14)</sup>

The gene responsible for Darier's disease has been localized in chromosome 12q 23–241.

ATP2A2 encoding the sarcoplasmic/ endoplasmic reticulum Ca<sup>2+</sup> ATPase (SERCA) 2 has been identified as the defective gene in Darier's disease, <sup>(15,8)</sup> suggesting that SERCA2 plays an important role in epidermal cell adhesion and differentiation. <sup>(4, 6)</sup> In fact, abnormalities in SERCA2 may alter cell signalling and affect the synthesis, folding or trafficking of desmosomal components. <sup>(16)</sup>

Clinically, the distinctive lesion is a firm, rather greasy, crusted papule that is skin-coloured or yellow–brown. Coalescence of the papules produces irregular warty plaques or papillomatous masses, which, in the flexures, become hypertrophic, fissured and malodorous. The sites of predilection are the seborrhoeic areas of the trunk and face, particularly the scalp margins. The palms and soles may show punctate keratoses and minute pits. Several abnormalities may be detected in nails <sup>(2)</sup> as nail fragility, longitudinal ridging and splitting. Subungual hyperkeratotic fragments often protrude from beneath the free

margin of the nail and longitudinal red or white lines. In Burge and Wilkinson's, study nail involvement was detected in 90% of cases. <sup>(2)</sup> In our case series got similar finding.

The frequency of psychoneurological problems, including seizure, mental retardation and psychoses, maniac depressive illness and epilepsy have been reported to be increased in patients with Darier's disease. <sup>(17)</sup> in our case series, no psychoneurological problem were noted. Histologically, Darier's disease is characterized by hyperkeratosis <sup>(7, 8)</sup> acantholysis which forms suprabasal clefts. There is formation of corps ronds and grains which are seen in the superficial portion of the biopsy. Corps ronds are usually present in the granular cell layer and show central large round, dyskeratotic basophilic masses surrounded by a clear halo like zone. <sup>(7,8)</sup> We observed similar finding in our case series. Hyperkeratosis, acanthosis were seen in all three cases and corps ronds and grains were more prominent in case 2, case 3.

Darier's disease must be distinguished histologically from other acantholytic



dyskeratoses, such as Haily-Haily disease (familial benign pemphigus) and Grover's disease (transient acantholytic dermatosis). In Haily-Haily disease, acantholysis is incomplete, causing the well-known "dilapidated brick wall" appearance of the lower epidermis. <sup>(18)</sup>

Darier's disease may worsen with age, but severity is unpredictable and fluctuates. The outcomes of investigations into genotype-phenotype correlations have been disappointing. <sup>(19)</sup>

Despite much progress in understanding of the underlying abnormalities in Darier's disease, treatment is usually unsatisfactory. Many patients with mild disease require no treatment other than simple emollient-like soap substitutes and moisturizers, <sup>(1)</sup> with advice about the effects of sunshine. For those with more severe disease, oral retinoids are the most effective prescription. The clinical response is good in 90% of patients. <sup>(3)</sup>

Most patients tolerate 0.6 mg/kg of acitrecin daily, but 10–25 mg daily is a reasonable starting dose and the dose can be increased gradually. <sup>(1)</sup>

Other treatments, such as topical retinoids, topical corticosteroids, surgery and laser surgery, have their advocates but evidence of efficacy is sparse. Photodynamic therapy can be viewed as a potential adjunctive modality for Darier's disease. <sup>(20)</sup>

### **CONCLUSION**

Darier's disease shows apparent heterogenous clinical presentation, especially with clinical feature mimicking eczema and seborrheic dermatitis. Biopsy is necessary to arrive at definitive diagnosis. The clinical and histopathological features in this study were concordant with those described in literature.


### **REFERENCES**

1. Burge SM. Darier's disease, keratins and proteases: a review. *J R Soc Med* 1989; **82**: 673-6.
2. Burge SM, Wilkinson JD. Darier-White disease: A review of the clinical features in 163 patients. *J Am Acad Dermatol* 1992; **27**: 40-50.
3. Munro CS. The phenotype of Darier's disease: Penetrance and expressivity in adults and children. *Br J Dermatol* 1992; **127**: 702-11.

4. A. Sakuntabhai, V. Ruiz-Perez, S. Carter et al., "Mutations in ATP2A2, encoding a Ca<sup>2+</sup> pump, cause Darier disease," *Nature Genetics*, vol. 21, no. 3, pp. 271–277, 1999.
5. Richard G, Wright AR, Harris S, Doyle SZ, Korge B, Mazzanti C, et al. Fine mapping of the Darier's disease locus on chromosome 12q. *J Invest Dermatol* 1994; 103:665-8. Darier's Disease 13
6. Sheridan AT, Hollowood K, Sakuntabhai A, Dean D, Hovnanian A, Burge S. Expression of sarco/endoplasmic reticulum Ca<sup>2+</sup>-ATPase type 2 isoforms (SERCA2) in normal human skin and mucosa, and Darier's disease skin. *Br J Dermatol* 2002;147:670-4)
7. Judge MR, McLean WHI, Munro CS. Disorders of keratinization. In : Burns T, Breathnach S, Cox N, Griffiths, eds. *Rook's Textbook of Dermatology*, 8th edition, Vol. 1. Massachusetts, Oxford, Victoria: Blackwell Science; 2010. p.19.81–6.
8. Kwok PY, Bhutani T, Liao W. Keratosis follicularis (Darier Disease). 2010. Available at: <http://emedicine.medscape.com/article/1107340-overview#a0101>
9. Loche F, Carrière M, Schwarze HP et al. Darier White disease and dermatofibrosarcoma protuberans. *Dermatology* 1999; **199**:278–280.
10. Tavadia S, Mortimer E, Munro CS. Genetic epidemiology of Darier's disease: a population study in the west of Scotland. *Br J Dermatol* 2002; **146**: 107–109.
11. Wilkinson JD, Marsden RA, Dawber RPR. Review of Darier's disease in the Oxford region. *Br J Dermatol Suppl* 1977; **15**:15–16.
12. T. Ferris, P. J. Lamey, and J. S. Rennie, "Darier's disease: oral features and genetic aspects," *British Dental Journal*, vol. 168, no. 2, pp. 71–73, 1990
13. Cooper SM, Burge SM. Darier's disease: epidemiology, pathophysiology, and management. *Am J Clin Dermatol* 2003; **4**: 97-105
14. Hakuno M, Shimizu H, Akiyama M et al. Dissociation of intra- and extracellular domains of desmosomal cadherins and E-cadherin in Hailey-Hailey disease and Darier's disease. *Br J Dermatol* 2000; **142**:702–71

15. Dhitavat J, Dode L, Leslie N et al. Mutations in the sarcoplasmic/ endoplasmic Ca<sup>2+</sup> ATPase isoform cause Darier's disease. *J Invest Dermatol* 2003; **121** :486–489.
16. Hulatt L, Burge S. Darier's disease: hopes and challenges. *J Roy Soc Med* 2003; **96**: 439–441.
17. Jacobsen N, Daniels J, Moorhead S et al. Association study of bipolar disorder at the phospholipase A2 gene (PLA2A) in the Darier's disease (DAR) region of chromosome 12q23-q24.1. *Psychiatr Genet* 1996;**6**: 195–199.
18. P. H. Meckee, *Pathology of the Skin With Clinical Correlations*, Mosby, Philadelphia, Pa, USA, 2nd edition, 1996.
19. Bale SJ, Toro JR. Genetic basis of Darier White disease: bad pumps cause bumps. *J Cutan Med Surg* 2000;**4**: 103–106.
20. Exadaktylou D, Kurwa HA, Calonje E, Barlow RJ. Treatment of Darier's disease with photodynamic therapy. *Br J Dermatol* 2003; **149**: 606–610.

## AUTHER PROFILE –

1. 1- Dr. Harsh kumar , MD , Professor<sup>1</sup> Department of pathology, Dr. D.Y Patil Medical College and Hospital, Pimpri, Pune, India
  2. Dr .Jain K Atul, MD, Assistant Professor<sup>1</sup> Department of pathology, Dr. D.Y Patil Medical College and Hospital, Pimpri, Pune, India
- 
3. Dr.Chandanwale S.S. , MD, Professor<sup>1</sup> Department of pathology, Dr. D.Y Patil Medical College and Hospital, Pimpri, Pune, India
  4. Dr.Panicker N.K. ,MD,professor<sup>1</sup> Department of pathology, Dr. D.Y Patil Medical College and Hospital, Pimpri, Pune, India