

---

Research Article

## Histopathologic Spectrum of Upper Gastrointestinal Tract Mucosal Biopsies: A Prospective Study

*Rosy Khandelia<sup>1</sup>, Mayurpankhi Saikia<sup>2</sup>*

<sup>1</sup>Demonstrator, Gauhati Medical College, Guwahati,781032, India,

<sup>1</sup>Demonstrator,Gauhati Medical College, Guwahati,781032, India,

**Corresponding author: Dr Rosy Khandelia,**

Demonstrator, Department of Pathology, Gauhati Medical College, Guwahati 781032, India,

---

### Abstract:

**Introduction:** Upper Gastrointestinal tract endoscopy in combination with biopsy plays an important role in the early diagnosis of GI neoplasms and provides an opportunity for a broad range of treatment options as well as potential for possible cure. This study was done to determine the histopathologic spectrum of Upper Gastrointestinal Tract Mucosal Biopsies.

**Methods:** A prospective study of upper GI endoscopic biopsy was carried out in a tertiary care hospital over a span of one year. 125 biopsy samples were subjected to histopathological examination.

**Result:** Among the 115 endoscopic biopsies- oesophageal biopsies were 48 (41.7%), gastric biopsies were about 40(34.7%) and duodenal biopsies were 27 (23.4%). Male to female ratio was 1.44:1. Mean age of presentation was 40 years. Biopsies comprised of 78 (67.8%) non neoplastic cases and 37(32.1%) neoplastic cases. Among the 37 neoplastic cases,21 cases were from oesophagus and 16 cases from stomach. All the 21 esophageal malignancies were squamous cell carcinoma(SCC)and all the 16 gastric malignancies were diagnosed as adenocarcinoma.

**Conclusion:** We conclude that endoscopy is incomplete without biopsy and so the combination of methods provides a powerful diagnostic tool for better patient management.

---

### INTRODUCTION

Before the advent of endoscopy direct access to the lesion of the gastrointestinal tract for the confirmation of the diagnosis was difficult, this posed difficulty in contemplating adequate and appropriate surgery. Endoscopy as a diagnostic and therapeutic tool has grown in recent years. Upper GI endoscopy in combination with biopsy plays an important role in the early diagnosis of GI neoplasms and provides an opportunity for a broad range of treatment options as well as potential for possible cure.<sup>1</sup> It is a simple, safe and well tolerated procedure with direct visualization of the pathologic site and biopsy leading to early detection of pathologic changes and therefore helps to start appropriate treatment. Endoscopic biopsy examination followed by histopathologic assessment is a convenient procedure and current gold standard for accurate objective assessment of patients. Upper gastrointestinal tract is one of the most common sites for neoplasms, especially malignant tumours. Worldwide, gastric adenocarcinoma is the second most common cancer and carcinoma oesophagus is the sixth leading cause of death.<sup>2,3</sup> According to the National Cancer Registry, oesophageal and gastric cancers are the most common cancers found in men, while oesophageal cancer ranks third among women after the

carcinoma of breast and cervix.<sup>4</sup> Early detection of malignancy greatly improves the survival rate of the patients. This study was done to determine the histopathologic spectrum of Upper Gastrointestinal Tract Mucosal Biopsies.

### II. MATERIALS AND METHODS

A prospective study of upper GI endoscopic biopsy was carried out in a tertiary care hospital over a span of one year in which about 125 endoscopic mucosal biopsies were evaluated. The endoscopy was done by gastroenterologist and all the samples of upper GIT endoscopic biopsy were included. All the biopsy samples were immediately put in 10% neutral buffered formalin followed by conventional tissue processing and embedding. Five micron thick sections were cut and slides were prepared. Each section was stained with Haematoxylin and Eosin stain and studied.

### III. RESULTS AND DISCUSSION

Among the 115 endoscopic biopsies- oesophageal biopsies were 48 (41.7%), gastric biopsies were 40(34.7%) and duodenal biopsies were 27 (23.4%). Out of 115 cases, 68 (59.1%) were males and 47 (40.8%) were females with a male

to female ratio of 1.44:1. This gender ratio favouring males could be reflective of the fact that males are exposed to more risk factors than females and gastrointestinal malignancies are more common in males according to JC Paymaster et al.<sup>5</sup> Age of the patients ranged from 10 – 90 years. Mean age of presentation was 40 years. The youngest patient was a 11 year old female with nonspecific duodenitis and the oldest patient was 86 year male with adenocarcinoma of stomach. Majority of patients (61%) presented with dysphagia and abdominal pain. Biopsies comprised of 78 (67.8%) non-neoplastic cases and 37(32.1%) neoplastic cases. Among the 37 neoplastic cases,21 cases were from oesophagus and 16 cases from stomach.

Table I: Histopathological findings in upper GI biopsies

LESIONS	NO OF CASES	%
<b>Esophagus</b>		
Chronic non specific esophagitis	15	13.5
Barrets Esophagus	02	1.73
Squamous cell Carcinoma	21	18.2
Dysplasia	03	2.60
No Specific Pathology	07	6.08
<b>Stomach</b>		
Chronic Non Specific Gastritis	10	8.69
Acute Non Specific Gastritis	02	1.73
Eosinophilic Gastritis	02	1.73
Gastric ulcer	06	5.21
Adenocarcinoma	16	13.9
No specific pathology	04	3.47
<b>Deodenum</b>		
Non Specific Duodenitis	16	13.9
Duodenal Ulcer	08	6.95
No specific Pathology	03	2.60

Distribution of Esophageal Lesions: Among the esophageal biopsies, 56.25% revealed non-neoplastic pathologies and 43.75% showed neoplastic lesions. Chronic nonspecific esophagitis was the commonest diagnosis among the non-neoplastic lesions. 96% of the patients with oesophageal carcinoma presented between 5th – 6th decades of life. These observations are similar with the studies of Qureshi et al and

and Bazaz-Malik G.<sup>6,7</sup> All the 21 esophageal malignancies were squamous cell carcinoma(SCC), out of these 15 (71.4%) cases were of well differentiated squamous cell carcinoma as shown in figure 1, 05 (23.8%) cases of moderately differentiated SCC and 1(4.7%) case of poorly differentiated SCC as shown in figure 2.

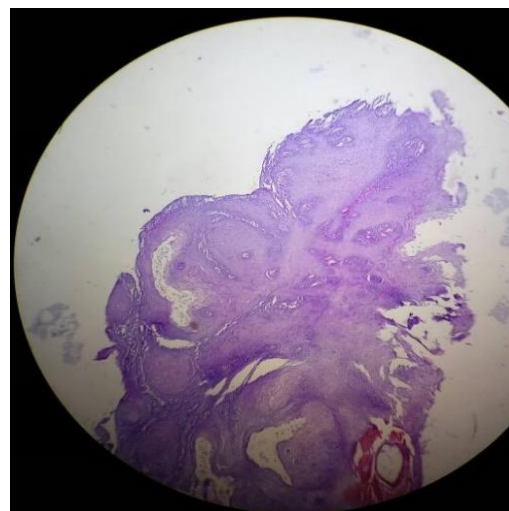


Figure 1: Well differentiated squamous cell carcinoma

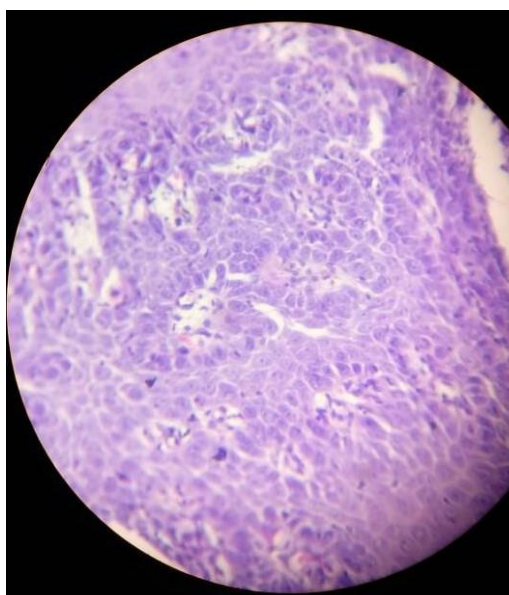


Figure 2: Poorly differentiated squamous cell carcinoma

Distribution of Gastric Lesions: Among the gastric biopsies, 60% revealed non-neoplastic pathologies and 40% showed neoplastic lesions. Chronic non-specific gastritis was the commonest diagnosis among the non neoplastic lesions which is comparable to the study conducted by Shreesha Khandige.<sup>8</sup> 13.9% of cases presented with adenocarcinoma. All the 16 gastric malignancies were diagnosed as adenocarcinoma, out of these 8 cases (50%) were differentiated adenocarcinoma, 06 cases (37.5%) were moderately differentiated adenocarcinoma and 02 cases (12.5%) were signet ring carcinomas.

Distribution of Deodenal Lesions: In our study 16(13.9%) patients showed nonspecific duodenitis which is comparable to the previous study done by Neil A Shepherd et al<sup>9</sup> followed by 8(6.95%) cases of duodenal ulcer and 3 (2.60%) cases of non specific deodenitis.

#### IV.CONCLUSION

Biopsy sampling of upper gastrointestinal mucosa at diagnostic endoscopy provides useful information. A variety of non-neoplastic and neoplastic lesions were reported in the present study across a wide range of age and site distribution. We conclude that biopsy of upper gastrointestinal lesions helps in early detection of mucosal lesions and diagnosis of the carcinomas at early stage leading to early clinical management. Endoscopy is incomplete without biopsy and so the combination of methods provides a powerful diagnostic tool for better patient management.

#### References

- [1] Sandhya PG, Madhusudan C, Naseem N, Balakrishnan CD, Balagurunathan K,. Interpretation of Upper GastroIntestinal Tract Endoscopic Mucosal Biopsies - A Study Conducted In Teaching Hospital In Puducherry, India. International Journal of Medical and Health Science. 2012; 1(3): 17 - 24.
- [2] Zhang XF, Huang CM, Lu HS, Wu XY, Wang C, Guang GX, et al,. Surgical treatment and prognosis of gastric cancer in 2613 patients. World Journal of Gastroenterology. 2004; 10: 3405-3408.
- [3] Enzinger PC, Mayer RJ; Esophageal cancer. The New England Journal of Medicine, 2003; 349: 2241-2252.
- [4] National Cancer Registry Programme. First All India Report 2001-2002. Vol 1. Indian Council of Medical Research. Bangalore, India. 2004.
- [5] Paymaster JC, Sanghvi LD, Ganghadaran P,. Cancer of gastrointestinal tract in western India. Cancer, 1968; 21: 279-287.
- [6] Nafees A Qureshi, Michael T Hallissey, John W,. Fielding Outcome of index upper gastrointestinal endoscopy in patients presenting with dysphagia in a tertiary care hospital - A 10 years review. BMC Gastroenterology, 2007; 7: 43.
- [7] Bazaz -Malik G, Lal N,. Malignant tumors of the digestive tract. A 25 year study. Indian Journal of Pathology and Microbiology, 1989; 32(3): 179185. 20
- [8] Shreesha Khandige,. The Conceding of Upper Gastrointestinal Lesion Endoscopic Biopsy: A Bare Minimum For Diagnosis. International Journal of Scientific Research, 2015; 4(2): 264 - 266.
- [9] Neil A Shepherd, Roland M Valori,2014. Guidance for Endoscopic Biopsy in the Gastrointestinal Tract Frontline. Gastroenterology, 2014; 5(2): 84-87.