
Research Article

Neuroimaging Abnormalities in Children Presenting With First Onset Apparent Unprovoked Seizures

Dr. Shashibala J Yadav¹, Dr. Anu Sharma²

¹Junior Consultant, Jindal Institute of Medical Sciences, Hisar

²Registrar, T.N.M.C & B.Y.L Nair Charitable Hospital, Mumbai.

Corresponding author: Dr Anu Sharma

¹Junior Consultant, Jindal Institute of Medical Sciences, Hisar

ABSTRACT:

Background: Seizures is the most common pediatric neurological disorder. 5-10% percent of children suffer at least one episode of seizure in the first 16 years of life. The incidence is highest in children less than 3 years of age. Epidemiological studies reveal that approximately 1, 50, 000 children will sustain a first-time, unprovoked seizure each year and of these 30,000 will develop epilepsy. Many of the adolescents and adults having epilepsy had their first episode of seizures in childhood. The management of seizures or later epilepsy is more complex in developing countries like India because of ignorance, poverty, stigmatization and lack of resources and trained manpower. The role of neuroimaging in unprovoked seizures has always been a topic of great interest and research. The role of neuroimaging in children with new onset unprovoked seizures is also not well defined and insufficient evidence is available to make a standard recommendation or guidelines for the use of routine neuroimaging in children with first unprovoked seizure. We conducted this study to find out neuroimaging abnormalities in children with first onset unprovoked seizures and to know whether finding of such neuroimaging abnormalities affect the management of these patients.

Aims and Objectives: To find out types of neuroimaging abnormalities in children with unprovoked seizures and to know whether finding of such neuroimaging abnormalities affect the management of these patients.

Materials and methods: This was a prospective cohort study comprising of children from 6 months to 12 years who have been referred to radiology department for either CT or MRI brain following first episode of unprovoked or complex febrile seizures. The demographics, history and clinical details were noted from case papers. Neuroimaging abnormalities found in these patients were noted and studied. The data was tabulated and analyzed using SPSS 16.0 version software.

Results: Total 30 children with unprovoked or complex febrile seizures who were referred to us for neuroimaging were enrolled in this study. 10 (33.33%) patients between 6m to 6 years and remaining 20 (66.66%) were more than 6 years. Most common type of seizures were found to be generalised seizures (60%). CT abnormalities were found in 9 patients (30%). MRI was done in 12 patients abnormalities were seen in 10 patients (33.33%). The most common CT and MRI abnormality found in these patients was volumetric reduction of cerebral hemisphere consistent with cerebral atrophy and Volume loss respectively. The other abnormalities found on neuroimaging included focal hypodense lesions (6.66%), white matter hypo-densities (3.33%), tram-track calcification suggestive of sturge weber syndrome (3.33%) and hemorrhage (3.33 %). MRI abnormalities seen in the patients included atrophic changes (3/12), infarcts (2/12), white matter lesions (2/12), Sturge Weber syndrome (1/12), hemorrhage (1/12) and acute disseminated encephalomyelitis (1/12).

Conclusion: Children presenting with first onset unprovoked or complex febrile seizures should undergo neuroimaging, preferably MRI, as part of basic workup. Many of these children are likely to be having neuroimaging abnormalities which will require specific treatment.

Key words: First onset unprovoked seizures, Pediatric age group, Neuroimaging abnormalities, Management.

Introduction:

Seizures are the most common pediatric neurological disorder¹. 5-10% percent of children suffer at least one episode of seizure in the first 12 years of life. The incidence is highest in children less than 5 years of age. As age advances

there is decrease in the frequency of seizures. Epidemiological studies reveal that approximately 1,50,000 children will sustain a first-time, unprovoked seizure each year and of these 30,000 will develop epilepsy². Many of the

adolescents and adults having epilepsy had their first episode of seizures in childhood. The management of seizures or later epilepsy is more complex in developing countries like India because of ignorance, poverty, stigmatization and lack of resources and trained manpower. Unprovoked seizures does not have an obvious precipitating cause. It may present as the single episode of a seizure which may never recur or it may recur³. The recurrence of an unprovoked seizure is then called epilepsy. Population-based estimates suggest that every year 25,000-40,000 children in the United States experience a first unprovoked seizure⁴. The guidelines for Neuroimaging after first episode of unprovoked seizures are not uniform⁵. The role of neuroimaging in children with unprovoked seizures is also not well defined and insufficient evidence is available to make a standard recommendation or guidelines for the use of routine neuroimaging in children with first unprovoked seizure⁶. In contrast guidelines for obtaining neuroimaging in adult patients presenting with seizures have been published⁷.

Detailed history, thorough clinical examination, electroencephalography and neuroimaging is an integral part of management of children presenting with first unprovoked seizures⁸. Neuroimaging techniques used may include neurosonography (particularly in neonates), computed tomography and magnetic resonance imaging⁹. Computed tomography is quick and can be done in emergency situations but it's associated with ionizing radiation and has less sensitivity than MRI in picking up subtle lesions. Moreover white matter abnormalities and conditions associated with demyelinating is better picked up by magnetic resonance imaging (MRI)¹⁰. MRI is more sensitive in picking up subtle anomalies but its higher cost, low availability and time required for scanning (necessitating sedation of the patient) are the drawbacks associated with MRI¹¹. Other imaging modalities like diffusion tensor imaging, MR/FDG-PET fusion imaging, and magnetic source imaging are usually not required and of either academic interest or may be helpful in patients with refractory seizures¹².

One of the important reasons for neuroimaging to be crucial is that some of these children may have pathologies which may need specific treatment and neuroimaging may help diagnose such conditions which is very difficult on the basis of clinical examination alone¹³. Such pathologies may include acute disseminated encephalomyelitis (requiring steroids), infarcts secondary to viral angiopathy (requiring acyclovir) and thromboembolism (requiring anticoagulation and other measures) etc. For this reason it is important to study neuroimaging abnormalities in children presenting with first apparent unprovoked seizures.

Materials And Methods

This was a prospective observational study carried out in department of radiology of a medical college situated in an urban area. The study consisted of 30 children between the age group of 6 months to 12 years who were sent for neuroimaging following first episode of an apparent unprovoked seizures. The patient belonged either to ward or

pediatric intensive care units. All patients underwent CT brain and selected patients underwent MRI if it was clinically indicated. The patients were included in the study depending upon a predefined inclusion and exclusion criteria. Demographic details like age, gender and past and family history was taken. History and clinical details were noted down from the case papers of the concerned patients. The history was looked into so as to know the specific type of seizures (generalized or focal). An anesthetist has sedated the patients if there was a need to do so (mostly for MRI brain). All the CT and MRI brains were interpreted by same radiologist. Neuroimaging abnormalities if detected were noted down with a special emphasis on their classification such as mass, encephalomalacia, anatomical defect, gliosis, ICSOL, demyelinating lesion or infective lesions. If any lesion was present then a previous scan was enquired into and if previous scan was available then the findings like size and shape were compared with the previous scan. The location of the lesion was also noted down. An effort was made to follow up the patient who had any neuroimaging abnormality so as to know whether the detection of these neuroimaging abnormalities influenced the management by pediatricians in anyway. The data was tabulated and analyzed using SPSS version 16. Fisher's test and t test were used as tests for significance. A P value lower than 0.05 was taken as statistically significant.

Inclusion Criteria:

1. Children between the age of 6 months- 12 years presenting with first onset of unprovoked seizures.
2. No h/o fever.
3. No precipitating cause.

Exclusion Criteria:

- 1- Age less than 6 months or more than 12 years.
- 2- H/o fever or any other sign of infection.
- 3- E/o CNS infection.
- 4- Neurological signs.

Results:

A total 30 patients referred to department of radiology for neuroimaging following first episode of unprovoked seizures were included in this study on the basis of a predefined inclusion and exclusion criteria. Out of these 30 patients there were 18 males and 12 females a M:F ratio of 1:0.66.

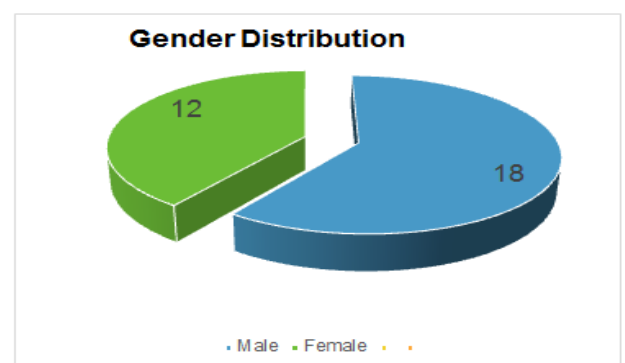


Figure 1: Gender Distribution of the studied cases.

The analysis of the age distribution of the studied cases showed that majority of the patients belonged to age group between 6m-5years (60%) followed by 5- 10 years (30%) and more than 10 years (10%). The mean age was found to be 4.3 years.

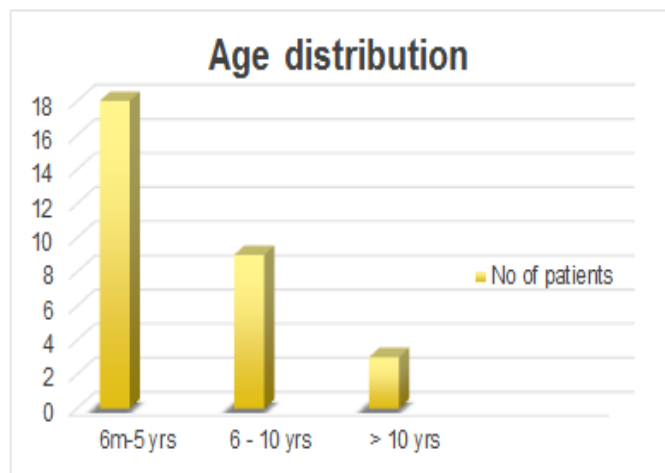


Figure 2: Age Distribution of the studied cases.

The analysis of the type of seizures showed that the most common type of seizures were generalized tonic-clonic seizures (33.33%) followed by simple partial seizures (26.66 %), secondary generalized (13.33 %) and absence seizures (13.33 %).

Type Of Seizures	Subtype	No of Cases	Percentage
Generalised Seizures	Absence	4	13.33%
	Tonic-Clonic	10	33.33%
	Myoclonic	2	6.66 %
	Total	16	53.33 %
Partial Seizures	Simple	8	26.66 %
	Complex	2	6.66 %
	Secondary Generalized	4	13.33 %
	Total	14	46.66 %
Total		30	100 %

Table 1: Type of Seizures in studied cases.

The analysis of symptoms of the studied cases showed that the most common symptom after seizures was altered sensorium (20 %), lethargy (16.66%), irritability (10%) and symptoms of upper respiratory tract infection (13.33 %). Being exclusion criteria patients with neck stiffness or signs of meningitis were excluded from the study.

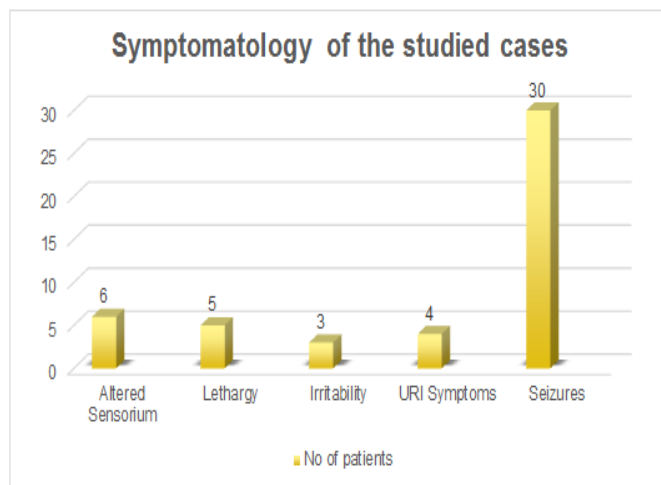


Figure 3: Symptomatology of the studied cases.

Non contrast Computed Tomography was done in all 30 patients. The analysis of neuroimaging findings showed that out of 30 studied cases 9 patients had some or the other form of abnormality seen on CT Brain. The most common abnormality on CT brain was found to be volumetric reduction of cerebral hemispheres consistent with cerebral atrophy (10 %) followed by focal hypodense lesions s/o infarcts (6.66 %), white matter hypodensity (3.33 %), tram track calcification s/o sturge weber syndrome (3.33%), hemorrhage (3.33 %) and equivocal CT (3.33 %) needing further evaluation by MRI.

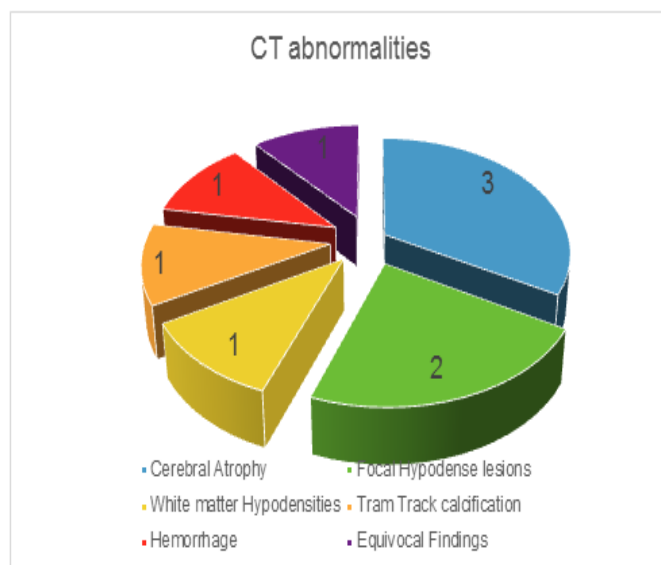


Figure 4: Neuroimaging abnormalities seen on CT Brain.

Out of the studied cases 12 patients underwent MRI scans as advised by treating pediatrician. The indications included further evaluation or equivocal CT brain. Out of 12 patients who underwent MRI 8 patients already had abnormal CT scans. Out of the remaining 4 patients 3 patients had normal CT and 1 patient had equivocal CT. Out of these 4 patients 1 patient was found to be having white matter lesion, 1 patient was found to be having acute disseminated encephalomyelitis (ADEM) and remaining 2 patients had normal MRI. The various MRI abnormalities found are given in tabulated form (Table 2).

MRI Features	Number of patients	Percentage
Normal	2	14.28 %
Atrophic changes	3	21.42 %
Infarcts	2	14.28 %
White matter lesions	2	14.28 %
Sturge weber syndrome	1	7.14 %
Hemorrhage	1	7.14 %
ADEM	1	7.14 %

Table 2: MRI findings seen in studied cases (12 patients)

The correlation of CT and MRI abnormalities revealed that out of the 8 patients in whom CT was abnormal MRI was also found to be abnormal and the abnormalities were similar. While in 1 patient where CT brain was equivocal MRI was found to be having white matter lesion. 1 patient with normal CT brain was found to be having features suggestive of acute disseminated encephalomyelitis.

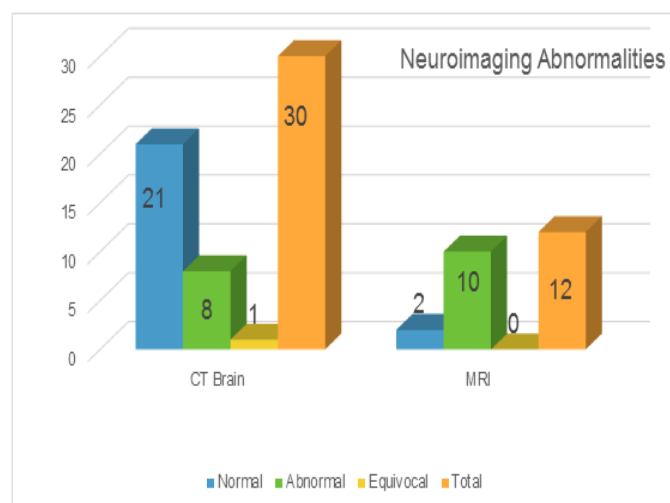


Figure 5: Correlation of CT and MRI brain abnormalities.

The patients were followed up to see whether neuroimaging abnormalities changed the management in anyway. Though in a small number of patients neuroimaging abnormalities such as ADEM, post varicella angiopathy and sturge weber syndrome changed the management of the patients. The child with ADEM on neuroimaging was given methylprednisolone to which he responded dramatically while the patient with sturge weber was put on long term anticonvulsants. Another patient who had cerebral infarct was eventually diagnosed to be having post varicella angiopathy and was given steroids and IV acyclovir.

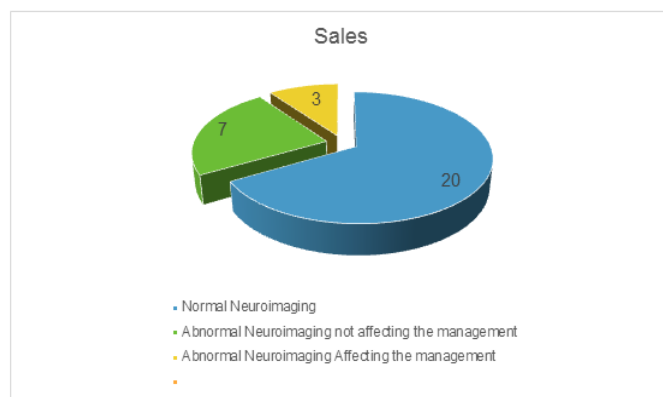


Figure 6: Neuroimaging abnormalities affecting the management of the patients.

Discussion:

This study was undertaken to know the neuroimaging abnormalities in children presenting with first onset unprovoked seizures. The mean age was found to be 4.2 years. The unprovoked seizures were found to be common below the age of 10 years. Similar findings were reported by various studies including those undertaken by Maytal et al¹⁴. In our study generalized seizures were more commonly than focal seizures. It is but expected as focal seizures are usually secondary to focal lesions like tuberculoma or neurocysticercosis etc and unprovoked seizures are by definition not due to such an etiology. Similar findings were reported by many other authors like Rasool et al¹⁵. Some authors have reported partial seizures to be more common than the generalized seizures (carrierio et al). Altered sensorium, lethargy and irritability were the most common associated features seen in the studied cases. Similar findings were also seen in the studies conducted by Stroink et al¹⁶.

Neuroimaging is one of the important diagnostic methods of evaluating a child presenting with first onset seizures. Though the neuroimaging is recommended in any adult patient presenting with first onset seizure such a recommendation can't be made for children presenting with first onset seizures because of lower incidence of neuroimaging abnormalities in these children¹⁷. In our study the prevalence of neuroimaging abnormalities (either CT, MRI or Both) was 33.33 %. CT scan was abnormal in 9 patients (30%) and MRI was abnormal in 10 patients out of 12 patients. Similarly many other studies have reported various neuroimaging abnormalities in children presenting with first onset unprovoked seizures. Garvey et al¹⁸ reviewed 99 children with new onset seizures and reported that neuroimaging was abnormal in 19% patients while according to Berg et al neuroimaging abnormalities were seen in 12.7% of the children presenting with first onset unprovoked seizures¹⁹.

In our study Abnormal CT brain results were seen in 30% patients and abnormal MRI was present in 33.33 %. All CT scans reported to be abnormal had also abnormal MRI and the abnormalities found on MRI corresponded well to CT abnormalities. One patient with equivocal findings on CT brain was found to be having white matter lesions on MRI and

one patient with normal CT brain was reported to be having acute disseminated encephalomyelitis on MRI. Hence it can be concluded that MRI is more sensitive in picking up neuroimaging abnormalities in children presenting with first onset unprovoked seizures and should be preferred over CT brain. This finding is supported by the studies conducted by Chang et al²⁰. Overall common neuroimaging abnormalities seen were atrophic changes, infarcts and white matter lesions. One patient had sturge weber syndrome while another one was diagnosed with ADEM.

One of the important aim of this study was to find out whether the neuroimaging abnormalities changed the management of patients in any way. Out of the 30 patients in whom neuroimaging was done the management was changed by treating pediatrician in 3 cases (10%) due to neuroimaging abnormalities. The abnormalities which changed the management included sturge weber syndrome, infarct secondary to post varicella angiopathy and acute disseminated encephalomyelitis. It can be inferred from the above findings that approximately 10% patients will get specific treatment following detection of neuroimaging abnormalities.

Conclusion: Neuroimaging forms the important part of management of children presenting with first onset unprovoked seizures. With improvements in imaging techniques more and more neuroimaging abnormalities are being picked up in these patients. Though in small number of patients abnormal neuroimaging is followed by changes in management by treating pediatricians. We therefore recommend that neuroimaging (Preferably MRI brain) should be done in children presenting with first onset unprovoked seizures whenever it is feasible.

References:

- [1] Friedman MJ, Sharieff GQ. Seizures in children. *Pediatr Clin North Am.* 2006 Apr;53(2):257-77.
- [2] Guerrini R. Epilepsy in children. *Lancet.* 2006 Feb 11;367(9509):499-524.
- [3] GHOFrani M. Approach To The First Unprovoked Seizure- PART I. *Iranian Journal of Child Neurology.* 2013;7(3):1-5.
- [4] Hirtz D, Berg A, Bettis D, et al. Practice parameter: treatment of the child with a first unprovoked seizure: Report of the Quality Standards Subcommittee of the American Academy of Neurology and the Practice Committee of the Child Neurology Society. *Neurology.* 2003 Jan 28. 60(2):166-75.
- [5] Roy T, Pandit A. Neuroimaging in epilepsy. *Annals of Indian Academy of Neurology.* 2011;14(2):78-80.
- [6] Pohlmann-Eden B, Beghi E, Camfield C, Camfield P. The first seizure and its management in adults and children. *BMJ : British Medical Journal.* 2006;332(7537):339-342.
- [7] Sinha S, Satishchandra P, Kalband BR, Bharath RD, Thennarasu K. Neuroimaging observations in a cohort of

elderly manifesting with new onset seizures: Experience from a university hospital. *Annals of Indian Academy of Neurology.* 2012;15(4):273-280.

- [8] Krumholz A, Wiebe S, Gronseth GS, et al. Evidence-based guideline: Management of an unprovoked first seizure in adults: Report of the Guideline Development Subcommittee of the American Academy of Neurology and the American Epilepsy Society. *Neurology.* 2015;84(16):1705-1713.
- [9] Hamiwka LD, Singh N, Niosi J, Wirrell EC. Diagnostic inaccuracy in children referred with "first seizure": role for a first seizure clinic. *Epilepsia.* 2007 Jun;48(6):1062-6.
- [10] Tillema J-M, Pirko I. Neuroradiological evaluation of demyelinating disease. *Therapeutic Advances in Neurological Disorders.* 2013;6(4):249-268.
- [11] Thukral BB. Problems and preferences in pediatric imaging. *The Indian Journal of Radiology & Imaging.* 2015;25(4):359-364.
- [12] Rubí S, Setoain X, Donaire A, Bargalló N, Sanmartí F, Carreño M, Rumià J, Calvo A, Aparicio J, Campistol J, Pons F. Validation of FDG-PET/MRI coregistration in nonlesional refractory childhood epilepsy. *Epilepsia.* 2011 Dec;52(12):2216-24.
- [13] Miskin DP, Saadi A, Chikoya L, Sloane JA, Korolnik IJ, Siddiqi OK. Challenges in the diagnosis and treatment of CNS demyelinating disorders in Zambia. *Multiple sclerosis journal - experimental, translational and clinical.* 2016;2:2055217316657117.
- [14] Maytal J, Krauss JM, Novak G, Nagelberg J, Patel M. The role of brain computed tomography in evaluating children with new onset of seizures in the emergency department. *Epilepsia* 2000;41:950-954
- [15] Akhter Rasool, Suhil A. Choh, Nisar A. Wani, et al Role of electroencephalogram and neuroimaging in first onset afebrile and complex febrile seizures in children from Kashmir *J Pediatr Neurosci.* 2012 Jan-Apr; 7(1): 9–15.
- [16] Stroink H, Brouwer OF, Arts WF, Geerts AT, Peters ABC, Van Donselaar CA. The first unprovoked, untreated seizure in childhood: a hospital based study of the accuracy of diagnosis, rate of recurrence, and long term outcome after recurrence. *Dutch study of epilepsy in childhood. J Neurol Neurosurg Psychiatry .* 1998; 64: 595–600
- [17] Hsieh DT, Chang T, Tsuchida TN, et al. New-onset afebrile seizures in infants: Role of neuroimaging. *Neurology.* 2010;74(2):150-156.
- [18] Garvey MA, Gaillard WD, Rusin JA, Ochsenschlager D, Weinstein S, Conry JA, Winkfield DR, Vezina LG. (1998) Emergency brain computed tomography in children with seizures: who is most likely to benefit? *J Pediatr* 133:664–669.

- [19] Berg AT, Testa FM, Levy SR, Shinnar S. Neuroimaging in children with newly- diagnosed epilepsy: a community-based study. *Pediatrics* 2000;106:527-532.
- [20] Chang T, Acosta MT, Rosser T, Conry JA, Pearl PL, Weinstein SL, Kolodgie M, Johnson P, Vezina LG, Dubovsky EC, Gaillard WD. (2002) Neuroimaging in children during the acute evaluation of new onset seizures. *Ann Neurol* 52:S134.